

# Extracranial Schwannoma of the Hypoglossal Nerve – a Case Report

## Extrakraniální schwannom nervi hypoglossi – kazuistika

### Abstract

**Background:** We describe a rare case of an extracranially located schwannoma of the hypoglossal nerve (CN XII). **Case description:** Case report with review of literature with emphasis on a possible iatrogenic lesion of the hypoglossal nerve. Initial intervention consisted of a biopsy of the tumour in a neurosurgical department, which resulted in a iatrogenic transection of the still-functional CN XII. The tumour was completely excised at subsequent surgery. **Conclusion:** In cases of unclear bulges of the neck, an MRI should be performed before scheduling surgical intervention, in order to prevent possible iatrogenic injury.

### Souhrn

**Východí problém:** Autoři popisují vzácný případ extrakraniálně lokalizovaného schwannomu podjazykového nervu (CN XII). **Popis případu:** Kazuistika s přehledem literatury zdůrazňující možnost iatrogenní léze podjazykového nervu. Nejprve byla na otorinolaryngologickém oddělení provedena biopsie tumoru, která však vedla k iatrogennímu přerušení dosud plně funkčního podjazykového nervu. Tumor byl pak kompletně odstraněn při následné operaci na neurochirurgické klinice. **Závěr:** V případech nejasného zduření na krku je nezbytné provést nejprve řádné MR vyšetření před plánovanou chirurgickou revizí, aby se zabránilo iatrogennímu poranění nervu.

**M. Kanta<sup>2</sup>, E. Ehler<sup>2</sup>,  
J. Habalova<sup>2</sup>, L. Klzo<sup>3</sup>**

<sup>1</sup> Neurochirurgická klinika LF UK  
a FN Hradec Králové

<sup>2</sup> Neurologické oddělení,  
Pardubická krajská nemocnice, a.s.

<sup>3</sup> Radiologická klinika LF UK  
a FN Hradec Králové



**doc. MUDr. Edvard Ehler, CSc.**  
Neurologické oddělení  
Pardubická krajská  
nemocnice, a.s.  
Kyjevská 44  
523 03 Pardubice  
e-mail: eda.ehler@tiscali.cz

Přijato k recenzi: 15. 7. 2009

Přijato do tisku: 9. 9. 2009

### Key words

cranial nerve tumours – iatrogenic lesion  
– schwannoma of the hypoglossal nerve

### Klíčová slova

tumory hlavových nervů – iatrogenní léze  
– schwannom podjazykového nervu

## Introduction

Schwannomas constitute 8–10% of all intracranial tumours. In 90% of cases, they arise from the vestibulocochlear nerve and usually grow around the facial nerve, which causes damage to this nerve. Tumours of other cranial nerves are rarer. Tumours of the hypoglossal nerve (CN XII) are very rare. To date, 42 cases of schwannoma arising from CN XII have been described by Ocura et al in 1994 [1], and Piccirilli et al in 2007 [2] found 105 cases in the English literature. In one case, a tumour of CN XII was located bilaterally, namely in the hypoglossal canal [3]. Extracranial location of the tumour just under the skull base is extremely rare. The authors had an opportunity to operate on a schwannoma in this location, and therefore share the experience.

## Case report

A 56-year-old man, a teacher, observed, over a 6-month period, a growing bulge on the right side of his neck. After an examination in an ENT department and in a department of infectious diseases, an ultrasound examination was performed with a finding of a suspicious lymph node, and an excision was recommended. The lymph node was surgically removed through a short incision. However, extensive expansion was revealed, so further excision was abandoned. In view of a progression of clinical findings consistent with a lesion of CN XII and CN XI, a revision was performed in the ENT department, and an extensive tumour reaching the base of the jugular foramen was revealed. However, because of its size and location, the surgeon did not continue with the intended complete excision of the tumour. It was only in this phase that an MRI investigation was requested, which determined the course of further interventions. In addition, the patient had started complaining of dysarthria and a tongue movement disorder after his first surgery. The MRI investigation revealed a tumour extending from the jugular foramen under the skull base as far as the C3–4 level laterally to the internal carotid artery, which the tumour was pushing away (Fig. 1–3). Cranially to the skull base, the finding was normal. Histological findings on the biopsy showed evidence of **schwannoma**.

At this point, the patient was transferred to the Department of Neurosur-

gery of the Faculty Hospital. During subsequent surgical procedure, the original scar on the right side under the mandible was used, extended distally in front of the sternocleidomastoid muscle and medially to the mastoid process. First, the common carotid artery and the vagus nerve were exposed in the healthy tissues; next, the carotid bifurcation and the external and internal carotid arteries were exposed as well. In the area of the scar, a pear-shaped tumour of a solid consistency was found, about 5 × 4 × 4 cm in size. The tumour was encapsulated, and it was relatively easy to dissect it, under a microscope, from the surrounding structures. A fine ramus descendens of the CN XII exited from the surface of the tumour. The internal carotid artery, which the tumour had been pushing away, was released from the tumour. However, the course of the CN XII peripherally to the distal stump dwindled in the scar tissue as a result of the ENT surgery. The tumour was released as far as its base where, just next to the jugular foramen, it was changing to a macroscopically normal nerve. In this location, the tumour was separated. The peripheral end of the nerve was not found; therefore, the intended reconstruction of CN XII using a sural nerve graft could not be performed. No other tumours possibly indicating the presence of neurofibromatosis were found in the patient.

The post-operative course was uncomplicated. In the initial period, the patient had light dysarthria – which, however, was receding – and a slight drooping of one corner of the mouth. An MRI check showed that the tumour had been completely removed.

Six months after surgery, the patient had only minimal problems arising out of nerve paresis. He had returned to his original profession, teaching in high school. In a neurological examination after 15 months, the patient had only a mild clumsiness on pronunciation of the tip-of-the tongue letters (r, ř, s, š, c, č). Clinical findings included a marked atrophy of the right half of the tongue and a palate arch that was lower on the right side during testing of swallowing. In an EMG examination, frequent fibrillation potentials and positive sharp waves at rest and “neurogenic” MUP during a voluntary contraction were found.

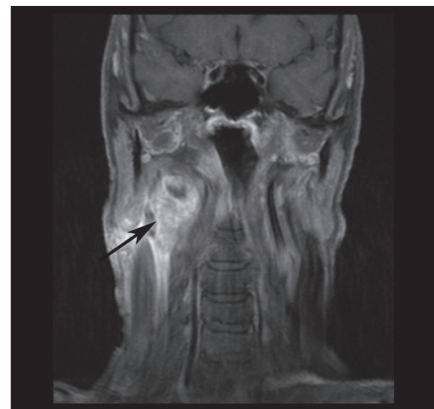


Fig. 1. MRI: T1-weighted image with fat saturation, coronal plane.

Extracranial mass with cystic portion, typical strong enhancement after administration of contrast agent (arrow).

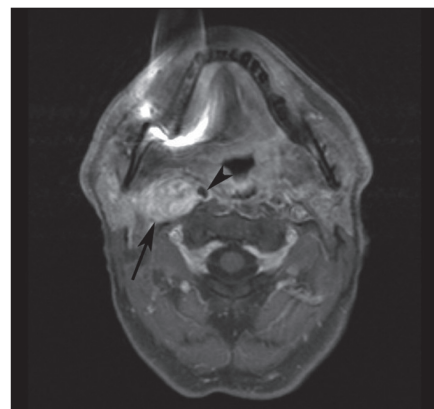


Fig. 2. MRI: T1-weighted image with fat saturation, axial plane.

Enhancing tumorous mass (arrow) displacing right internal carotid artery.

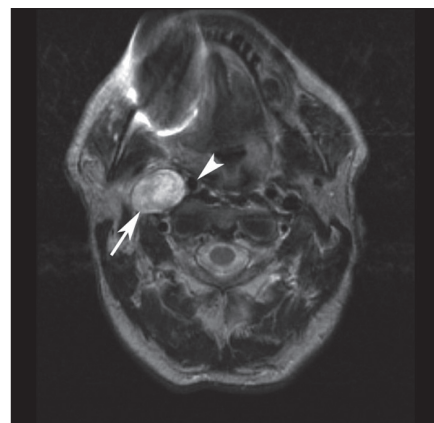


Fig. 3. MRI: T2-weighted image, axial plane.

Slightly heterogeneous T2 hyperintense mass (arrow) in carotid space, right internal carotid artery displaced medially (arrowhead).

## Discussion

Tumours of the hypoglossal nerve are very rare and to date, only 105 cases have been described [2]. The literature therefore provides only a description of case reports but not of patient aggregates [4]. In an intracranial location the tumours manifest themselves by exerting pressure on the brainstem and the cerebellum; further, in the area of the jugular foramen, they affect the lower cranial nerves and the jugular vein (Collet-Sicard syndrome) [5,6]. Tumours penetrating the hypoglossal canal also exist, and they may have extracranial and intracranial parts ("dumb-bell-shaped" tumours). Schwannomas of the CN XII growing only extracranially are extremely rare, and in 2007, Piccirilli et al found only 19 such cases described in the literature [2,7,8].

The diagnosis of a hypoglossal nerve tumour is based on case history data and on a focused physical assessment, which are complemented by an imaging procedure. Most patients present with paresis of CN XII. However, incidental findings of a CN XII tumour without significant paresis have been described as well which, in fact, occurred in our patient. It is difficult for a CT scan to obtain an image of a solely extracranial tumour or a tumour with a significant extracranial part. The introduction of MRI has been of great benefit, and MRI is now a powerful tool in the diagnosis of CN XII tumours, especially those located under the base. In our case, working from an ultrasound examination, the mass was described in terms of node clusters and not as a large, solid tumour. The surgeon therefore saw no reason for an MRI examination. During subsequent surgery, a serious iatrogenic lesion of the CN XII developed. An MRI investigation was performed only after the second ENT surgery during which, however, a large solid tumour extending to the base had already been confirmed. Among other auxiliary examinations, an EMG examination of the extracranial part of a tumour may be valuable because it could detect

a lesion of CN XII as well as of other nerves (especially CN XI). For a neurophysiological diagnosis of a lesion of the CN XII, it is possible to use not only needle EMG (proof of fibrillations and MUP changes) but also motor neurography (electrodes are placed on the surface of the tongue) [9,10].

The surgical approach depends on the location of the process and, given the complicated topographic relations (an intersection of three arteries, the relationship to surrounding nerves and muscles), it is frequently difficult [11]. It is possible to remove the intracranial portion using a suboccipital approach and concurrently, a C1 laminectomy. Tumours based in the skull base may be excised using a dorso-lateral transcondylar approach [12]. Using a cervical approach, it is possible to remove extracranial portions. After exiting the base, the nerve is located medially to cranial nerves IX, X, and XI, and it continues behind the posterior belly of the digastric muscle between the internal carotid artery and the jugular vein. In surgery, it is necessary to bear these complicated anatomical relations in mind and, in so doing, to avoid possible iatrogenic lesions and their serious consequences.

During treatment of peripheral nerve schwannoma, it is usually possible – using a microsurgical technique – carefully to "pull down" functional fibres located on the surface of the tumour. This manoeuvre allows for preservation of nerve function. If it proves necessary to resect the tumour after all, it is possible to connect the stumps using a sural nerve graft. During the neurosurgical operation, the authors did not find any fibres on the surface of the solid tumour. In addition, it proved impossible to find, in the scar tissue arising out of the previous ENT interventions, a peripheral portion of the CN XII. The intended reconstruction using a graft could not, therefore, be performed.

In recent years, there have been a growing number of iatrogenic injuries to peripheral nerves in all locations. In ENT departments, lesions of the CN XI following

lymph node removal are encountered very frequently. In the case under discussion, it was initially thought that a lymph node syndrome was being addressed, and it was treated as such. In cases of unclear bulges of the neck, it is worthwhile to conduct, before scheduling surgical revision, a thorough graphic demonstration – especially an MRI – with the goal of preventing possible iatrogenic injury to structures.

## References

1. Okura A, Shigemori M, Abe T, Yamashita M, Kojima K, Noguchi S. Hemiatrophy of the tongue due to hypoglossal schwannoma shown by MRI. *Neuroradiology* 1994; 36(3): 239–240.
2. Piccirilli M, Anichini G, Fabiani F, Rocchi G. Neurinoma of the hypoglossal nerve in the submandibular space: case report and review of the literature. *Acta Neurochir (Wien)* 2007; 149(9): 949–952.
3. Bektaş D, Caylan R. Bilateral hypoglossal schwannoma: a radiological diagnosis. *Kulak Burun Bogaz Ihtis Derg* 2004; 12(1–2): 45–47.
4. Takahashi T, Tominaga T, Sato Y, Watanabe M, Yoshimoto T. Hypoglossal neurinoma presenting with intratumoral hemorrhage. *J Clin Neurosci* 2002; 9(6): 716–719.
5. Garcia-Escribà A, Pampliega Pérez A, Martin-Estefania C, Botella C. Schwannoma of the hypoglossal nerve presenting as a syndrome of Collet-Sicard. *Neurologia* 2005; 20(6): 311–313.
6. Löwenheim H, Koerbel A, Ebner FH, Kumagami H, Ernemann U, Tatagiba M. Differentiating imaging findings in primary and secondary tumors of the jugular foramen. *Neurosurg Review* 2006; 29(1): 1–11.
7. Sato M, Kanai N, Fukushima Y, Matsumoto S, Tsumi C, Kitamura K et al. Hypoglossal neurinoma extending intra- and extracranially: case report. *Surg Neurol* 1996; 45(2): 172–175.
8. Spinnato S, Talacchi A, Musumeci A, Turazzi S, Bricolo A. Dumbbell-shaped hypoglossal neurinoma: Surgical removal via a dorsolateral transcondylar approach. A case report and review of the literature. *Acta Neurochir (Wien)* 1998; 140(8): 827–832.
9. Muellbacher W, Mathis J, Hess CW. Electrophysiological assessment of central and peripheral motor routes to the lingual muscles. *J Neurol Neurosurg Psychiatry* 1994; 57(3): 309–315.
10. Redmond MD, Di Benedetto M. Hypoglossal nerve conduction in normal subjects. *Muscle Nerve* 2004; 11(5): 447–452.
11. Bademci G, Batay F, Yaşargil MG. "Triple cross" of the hypoglossal nerve and its microsurgical impact to entrapment disorders. *Minim Invasive Neurosurg* 2006; 49(4): 234–237.
12. Ho CL, Deruytter MJ. Navigated dorsolateral suboccipital transcondylar (NADOSTA) approach for treatment of hypoglossal schwannoma. Case report and review of the literature. *Clin Neurol Neurosurg* 2005; 107(3): 236–242.