

Guillain-Barré Syndrome Associated with Breast Cancer Treated with Trastuzumab – a Case Report

Guillainův-Barrého syndrom asociovaný s karcinomem prsu léčeným trastuzumabem – kazuistika

Abstract

We present a case report of a 66-year old woman with breast cancer treated with trastuzumab, a monoclonal antibody against the HER2 receptor. Treatment with trastuzumab was complicated by the development of Guillain-Barré syndrome, well documented by EMG examination, cerebrospinal fluid analysis and clinical course with a relatively good outcome after plasmapheresis and intravenous immunoglobulins.

Souhrn

Prezentována je kazuistika 66leté pacientky s karcinomem prsu, u které v průběhu léčby trastuzumabem, monoklonální protilátkou proti HER-2 receptorům, došlo k rozvoji syndromu Guillain-Barré, dokumentovaného EMG nálezy, likvorologickým vyšetřením a dobrou terapeutickou odpovědí na léčbu plazmaferézou a intravenózními imunoglobuliny.

The authors declare they have no potential conflicts of interest concerning drugs, products, or services used in the study.

Autoři deklarují, že v souvislosti s předmětem studie nemají žádné komerční zájmy.

The Editorial Board declares that the manuscript met the ICMJE “uniform requirements” for biomedical papers.

Redakční rada potvrzuje, že rukopis práce splnil ICMJE kritéria pro publikace zasílané do biomedicínských časopisů.

P. Busek, M. Miler

Department of Neurology, First Faculty of Medicine, Charles University in Prague and General University Hospital in Prague



MUDr. Petr Busek, Ph.D.

Department of Neurology, First Faculty of Medicine, Charles University in Prague and General University Hospital in Prague

Katerinska 30

120 00 Praha 2

e-mail: petrbussek@seznam.cz

Accepted for review: 18. 12. 2012

Accepted for print: 22. 3. 2013

Key words

breast cancer – cancer – Guillain-Barré syndrome – monoclonal antibodies – trastuzumab

Klíčová slova

karcinom prsu – karcinom – monoklonální protilátky – Guillain-Barré syndrom – trastuzumab

Introduction

Monoclonal antibodies have become an important treatment option for a number of autoimmune or oncological diseases [1]. Unfortunately, their use may be complicated by serious side effects. Especially, considerable concerns have arisen about some monoclonal antibodies association with progressive multifocal leukoencephalopathy [2].

Trastuzumab is a recombinant humanised monoclonal antibody against the human epidermal growth factor receptor 2 (HER2). The role of this receptor is to regulate cell growth, survival, adhesion and differentiation. An over-expression of this receptor was observed in some adenocarcinomas, particularly in breast cancer [3]. The binding of trastuzumab to HER2 receptors induces antibody-dependent cell-mediated cytotoxicity against tumor cells, reduces cell proliferation and suppresses angiogenesis [4,5]. Cardiotoxicity is the most serious side effect of trastuzumab [6]. We report a case of a patient with breast cancer, who developed Guillain-Barré syndrome (GBS) as a trastuzumab treatment complication.

Case report

A 66-year old woman with breast carcinoma, staging T2N0M0, underwent mas-

tectomy in March 2010. She then received six courses of adjuvant chemotherapy with doxorubicin and cyclophosphamide. Trastuzumab was started three weeks after the last course of chemotherapy. Three days later, the woman complained of tingling sensation in her hands and feet and of stiffness in the calves. A marked symmetrical weakness in all extremities developed the following day. The patient was unable to walk or dress herself. Neurological examination showed a prominent generalized weakness, affecting predominantly proximal extremity muscles, and marked reduction of tendon reflexes. There was no sensory impairment. Muscle weakness, mainly in the lower extremities, progressed rapidly over the next two days. At this time, dysphagia occurred, and the patient developed tactile hypesthesia in a glove-stocking-like distribution, more pronounced in the legs. Based on the clinical picture, GBS was suspected. Because of its rapid progression, treatment with plasmapheresis was started. Cerebrospinal fluid (CSF) analysis showed normal protein level (0.52 g/L) and normal cell count (1/3 uL). Antibodies against *Borrelia burgdorferi*, EBV, CMV, HSV-1, 2, VZV, HHV 6, and tick-borne encephalitis were negative and PCR revealed no CMV and

HSV-1,2 DNA in the CSF. CSF analysis was repeated eight days later. This time, an elevated protein level was identified (0.99 g/L); cell count was normal (1/3 uL). This finding supported the diagnosis of GBS. Electroneurography, performed three weeks after the onset of first symptoms, detected markedly prolonged distal motor latencies, prominent temporal dispersion of compound motor action potential (CMAP), low amplitude of CMAP, and reduced conduction velocities (to less than 50% of lower normal limits) in medial and ulnar nerves, severe reduction of amplitude of CMAP and absence of motor responses after proximal stimulation of the left tibial and after proximal and distal stimulation of the right temporal and left common peroneal nerve (Fig. 1, 2). The markedly reduced amplitude of CMAP (< 1 mV) did not allow detection of conduction block. There was no sensory response of the median, ulnar, and sural nerves. F-wave responses were absent in all examined nerves. The needle electromyography showed reduced recruitment of motor units and the presence of rare positive sharp waves and fibrillation potentials (1+) in the right first dorsal interosseus, right deltoid, and both anterior tibial muscles. The finding of marked re-

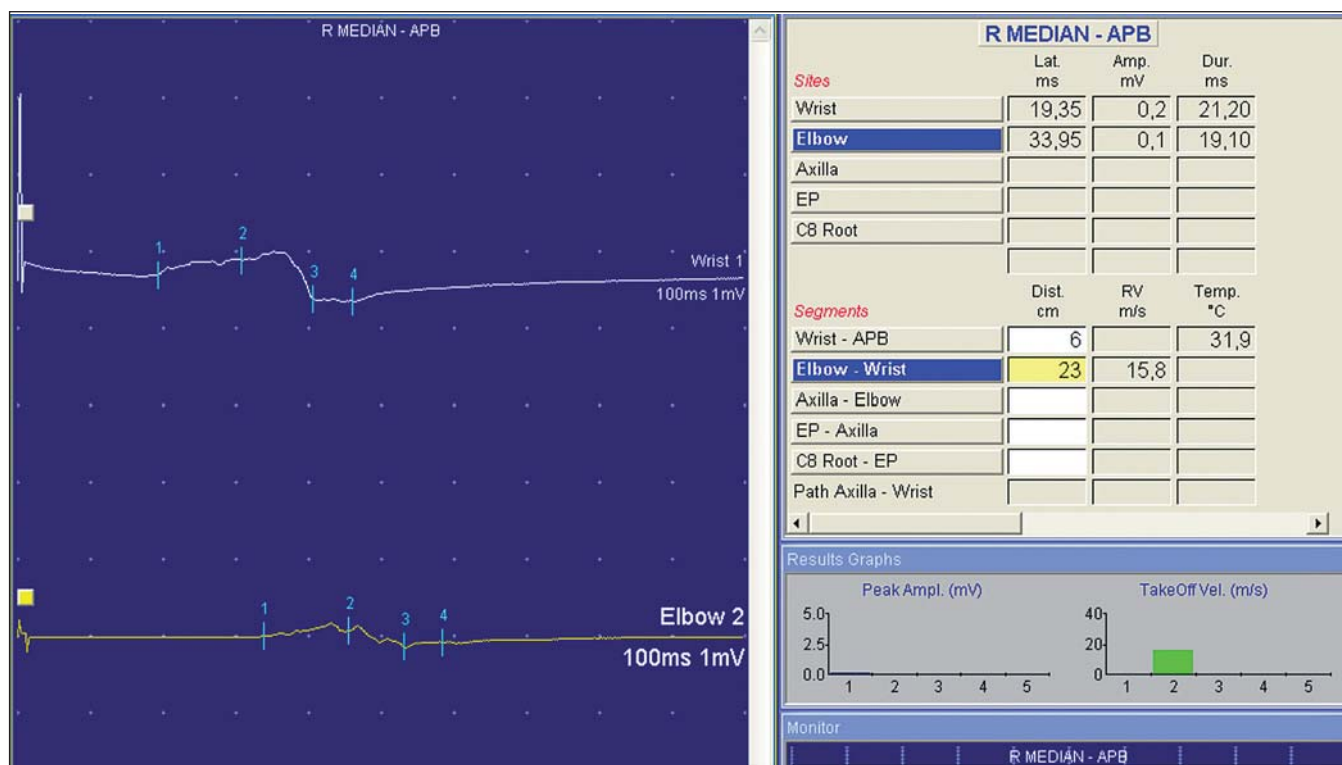


Fig. 1. Considerably prolonged distal motor latency, prominent reduction of amplitude of compound motor action potential, temporal dispersion and reduced conduction velocity of the right median nerve.

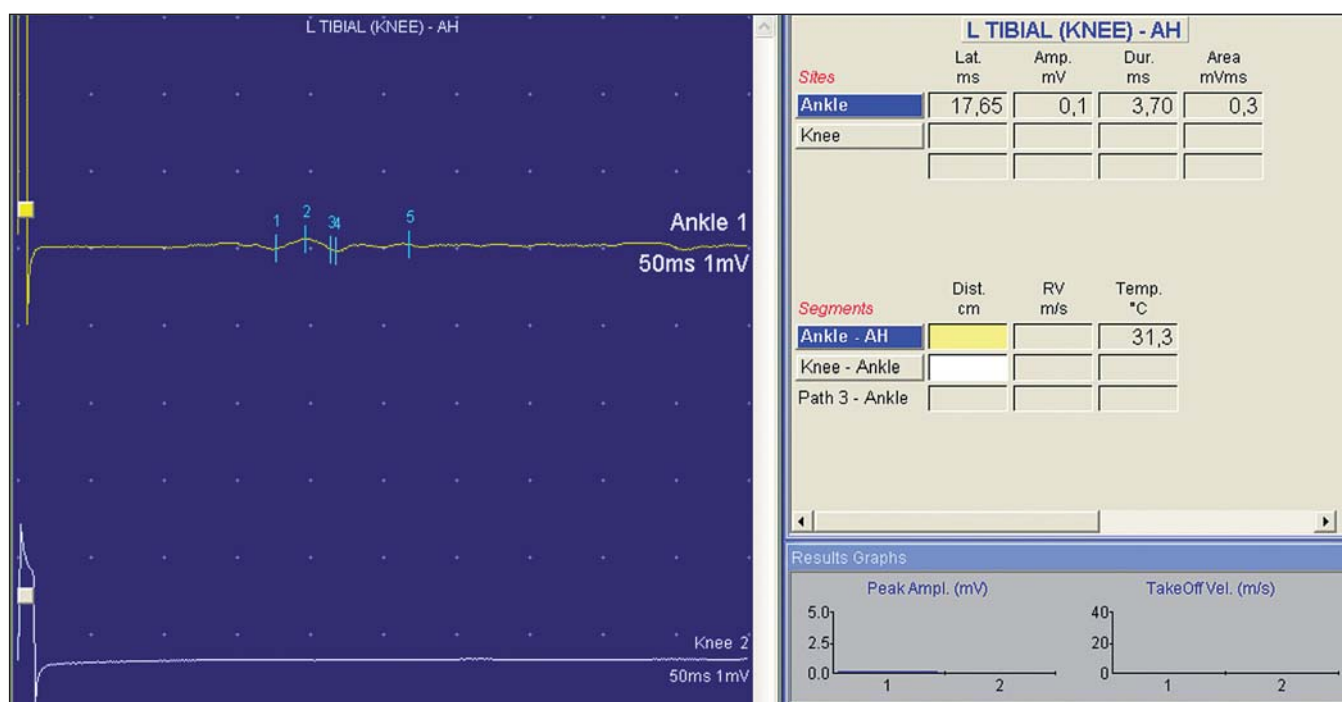


Fig. 2. Markedly prolonged distal motor latency, severe reduction of amplitude of compound motor action potential and absent response after proximal stimulation of the left tibial nerve.

duction or absence of CMAP, absence of SNAP, and the occurrence of positive sharp waves and fibrillation potentials in the needle EMG is consistent with acute motor and sensory axonal neuropathy (AMSAN) form of GBS [7].

The patient underwent seven rounds of plasmapheresis with slight improvement of muscle strength. Due to the insufficient effect, the course of plasmapheresis was followed by 5-day treatment with i.v. immunoglobulins at a dose of 0.4 g/kg/day. The patient's muscle strength further improved, making her fit for physiotherapy.

Discussion

The GBS is an acute autoimmune polyradiculoneuritis with ascending muscle paralysis resulting from autoimmune peripheral nerve damage. The onset of GBS is usually preceded by an infection. The infectious agents probably induce production of antibodies which cross-react with antigens (gangliosides, glycolipides) present in the myelin and in the peripheral nervous system. The autoimmune reaction results in lymphocytic infiltration of spinal roots and peripheral nerves and, consequently, in macrophage-mediated multifocal stripping of the myelin. In some cases of severe form of the disease, axonal disruption and loss occurs.

There are several reports of the GBS being associated with neoplastic diseases; nevertheless, it is unclear whether the GBS was the actual paraneoplastic phenomenon. GBS developed in association with small-cell lung carcinoma, gastric cancer, renal cancer, and with acute B-cell lymphoblastic leukemia [8–11].

In our case report, we present a patient with the GBS that developed shortly after the initiation of treatment with the monoclonal antibody trastuzumab. The diagnosis of GBS was supported by the patient's typical clinical picture, CSF analysis, electromyography, electroneurography, and by her therapeutic response to plasmapheresis and immunoglobulins. There is suspicion that this complication might be associated with trastuzumab treatment. We cannot rule out, though, that GBS appeared as a paraneoplastic process or merely coincidentally. Unfortunately, examination of *Campylobacter jejuni* serology, antganglioside and paraneoplastic antibodies was not performed. Association of GBS with administration of trastuzumab has previously been reported in isolated cases [12].

References

1. Lesterhuis WJ, Haanen JB, Punt CJ. Cancer immunotherapy – revisited. *Nat Rev Drug Discov* 2011; 10(8): 591–600.

2. Tavazzi E, Ferrante P, Khalili K. Progressive multifocal leukoencephalopathy: an unexpected complication of modern therapeutic monoclonal antibody therapies. *Clin Microbiol Infect* 2011; 17(12): 1776–1780.
3. McKeage K, Perry CM. Trastuzumab: a review of its use in the treatment of metastatic breast cancer overexpressing HER2. *Drugs* 2002; 62(1): 209–243.
4. Namboodiri AM, Pandey JP. Differential inhibition of trastuzumab- and cetuximab-induced cytotoxicity of cancer cells by immunoglobulin G1 expressing different GM allotypes. *Clin Exp Immunol* 2011; 166(3): 361–365.
5. Kerbel RS. Reappraising antiangiogenic therapy for breast cancer. *Breast* 2011; 20 (Suppl 3): S56–S60.
6. Zeglinski M, Ludke A, Jassal DS, Singal PK. Trastuzumab-induced cardiac dysfunction: A 'dual hit'. *Exp Clin Cardiol* 2011; 16(3): 70–74.
7. Van den Bergh PY, Piéret F. Electrodiagnostic criteria for acute and chronic inflammatory demyelinating polyradiculoneuropathy. *Muscle Nerve* 2004; 29(4): 565–574.
8. Naveed S, Okoli K, Hollingsworth J, Kasmani R. Guillain-Barré syndrome as a paraneoplastic manifestation of small-cell carcinoma of lung. *South Med J* 2010; 103(2): 156–158.
9. Colantuoni M, Matano E, Alfieri S, De Placido S, Carlomagno C. Guillain-Barre syndrome associated with gastric cancer: paraneoplastic syndrome or immunological disorder? *World J Oncol* 2010; 1(6): 247–249.
10. Večeřa L, Bednářik J. Case report of Guillain-Barré syndrome in a patient with renal carcinoma. *Cesk Slov Neurol N* 2012; 75/108(1): 84–87.
11. Mailänder V, Gleisner B, Blau IW, Thiel E. Guillain-Barre-Strohl syndrome unraveled as paraneoplastic syndrome of B-cell acute lymphoblastic leukemia in a patient with preceding common variable immunodeficiency syndrome with Evans syndrome. *Leuk Lymphoma* 2004; 45(1): 189–192.
12. Bettini AC, Tondini C, Poletti P, Caremoli ER, Guerra U, Labianca R. A case of interstitial pneumonitis associated with Guillain-Barré syndrome during administration of adjuvant trastuzumab. *Tumori* 2008; 94(5): 737–741.