

Stiff-person Syndrome Associated with Myotonic Dystrophy Type 2 – a Case Report

Stiff-person syndrom sdružený s myotonickou dystrofií 2. typu – kazuistika

Abstract

Stiff-person syndrome (SPS) is manifested by increased tone of the trunk muscles that gradually spreads to the limbs. The mechanism underlying this muscle hypertonia involves derangement of the inhibitory action of γ -aminobutyric acid (GABA) at cortical and spinal levels with subsequent continuous motor unit activity. A co-contraction mechanism with a board-like abdomen and painful lumbar hyperlordosis plays an important role. Symptomatic treatment involves drugs that enhance inhibition (baclofen and benzodiazepines). Causal treatment focuses on immunosuppression (corticosteroids, intravenously administered immunoglobulins, and plasmapheresis). A combination of SPS and another genetic disease has not yet been described. We describe a case study of a 46-year-old man with gradual development of severe SPS whose electromyography (EMG) showed continuous motor unit activity as well as several myotonic discharges. Genetic testing was indicative of myotonic dystrophy type 2 (DM2).

Souhrn

Stiff-person syndrom (SPS) se manifestuje zvýšeným napětím trupového svalstva, které se postupně šíří na končetiny. Mechanismus, který je podkladem svalové hypertonie, se skládá z poruchy inhibiční aktivity kyseliny gama-aminomáselné (GABA) na kortikální a spinální úrovni s následnou kontinuální aktivitou motorických jednotek. Důležitou úlohu má kokontrakce, která se projevuje prknavitým břichem a bolestivou lumbální hyperlordózou. Symptomatickou léčbu tvoří léky podporující inhibici (baklofen a benzodiazepiny). Kauzální léčba je zaměřena na imunosupresi (kortikoidy, intravenózní podání imunoglobulinu a plazmaferéza). Kombinace SPS a jiné geneticky podmíněné nemoci nebyla dosud popsána. Autoři prezentují kazuistiku 46letého muže s postupným rozvojem těžkého SPS. Při EMG vyšetření byla nalezena jak kontinuální aktivita motorických jednotek, tak i několik myotonických výbojů. Genetické vyšetření svědčilo pro myotonickou dystrofii typ 2 (DM2).

Used abbreviations

anti-GAD	anti-Glutamic Acid Decarboxylase
BAEP	Brainstem Auditory Evoked Potentials
DM2	Myotonic dystrophy type 2
GABA	γ -AminoButyric acid
EMG	ElectroMyoGraphy
MUP	Motor Unit Potentials
PERM	Progressive Encephalomyelitis with Rigidity and Myoclonus
SPS	Stiff-person Syndrome

This study was supported by the Internal Grant Agency of the Ministry of Health, project NT 13725-4/2012.

The authors declare they have no potential conflicts of interest concerning drugs, products, or services used in the study.

Autoři deklarují, že v souvislosti s předmětem studie nemají žádné komerční zájmy.

The Editorial Board declares that the manuscript met the ICMJE "uniform requirements" for biomedical papers.

Redakční rada potvrzuje, že rukopis práce splnil ICMJE kritéria pro publikace zasílané do biomedicínských časopisů.

E. Ehler¹, A. Kopal¹,
P. Mandysova¹, P. Vojtisek²,
J. Zamecnik³

¹ Dept. of Neurology, Pardubice Regional Hospital and Faculty of Health Studies, University of Pardubice

² Internal Dept., Pardubice Regional Hospital and Faculty of Health Studies, University of Pardubice

³ Institute of Pathology and Molecular Medicine, 2nd Faculty of Medicine, Charles University and Faculty Hospital Motol, Prague



Assoc. Prof. MUDr. Edvard Ehler, CSc.
Dept. of Neurology
Pardubice Regional Hospital
and Faculty of Health Studies,
University of Pardubice
Kýjevska 44
532 03 Pardubice
e-mail: edvard.ehler@nemocnice-pardubice.cz

Accepted for review: 8. 7. 2013
Accepted for print: 9. 9. 2013

Key words

co-contraction – GABAergic inhibition – immunoglobulins – myotonic dystrophy – stiff-person syndrome

Klíčová slova

kokontrakce – GABAergní inhibice – imunoglobuliny – myotonická dystrofie – stiff-person syndrom

Introduction

Stiff-person syndrome (SPS) is a rarely occurring and gradually progressive disorder of the central nervous system. It is clinically manifested by marked stiffness of the axial muscles that spreads to the limbs and by superimposed stimulus-sensitive spasms [1]. The spasms lead to a sudden increase of muscle stiffness and are provoked by voluntary movement, emotional triggers, tactile stimuli, and especially by auditory stimuli. The spasms are associated with attacks of pain, accentuation of dyspnoea, and stridor; they can even lead to luxation or fractures. Abdominal wall muscles exhibit board-like rigidity, and co-contraction of the paravertebral muscles leads to accentuation of lumbar lordosis and induction of lower back pain. The spasms are usually accompanied by paroxysmal dysautonomia – sweating, mydriasis, tachypnea, and tachycardia, as well as arterial hypertension – and also by anxiety. In more severe forms of SPS, oculomotor disorders with horizontal diplopia [2] and dysphagia, as well as urinary bladder dysfunction [3] can develop. Anti-glutamic acid decarboxylase antibo-

dies (anti-GAD65) that lead to GABAergic synapse impairment in the brain and spine, are present in 60–80% of patients with SPS. A paraneoplastic syndrome is identified in about 5%, and in such cases, the presence of antibodies against amphiphysin or gephyrin is sought. Electromyographic findings of continuous activity of normal motor unit potentials (MUP) present at rest and independent of passive joint motion (such activity is not increased through flexion, extension, or variable speed), have diagnostic significance [4]. SPS is associated with other autoimmune disorders, including nervous system disorders (myasthenia gravis and cerebellar ataxia), as well as with diabetes mellitus type 1 or lupus erythematosus [5]. Concurrent presence of SPS and genetic myopathies is rare, and occurrence of SPS in association with myotonic dystrophy has not yet been described.

Case report

A 45-year-old man was admitted to a neurology clinic due to a 2-month history of progressive muscle stiffness, muscle aches, oculomotor dysfunction,

convergent strabismus, diplopia, urinary bladder dysfunction (an indwelling catheter had been inserted prior to admission), and painful spasms accompanied by vegetative symptoms. He was unable to walk for the last three weeks, and he was unable to sit in a wheelchair because of the spasms during the week preceding admission.

The patient was followed for mild bronchial asthma and allergies (to pollen, mites and plastic) from 10 years of age. He worked as an analyst. First, he developed slight stiffness of the abdominal muscles and lower limbs, followed by urinary retention. Gradually, he developed spasmodic attacks and his gait worsened. Subsequently, he developed sweating and diplopia of the left eye.

On admission, he had marked hypertonia in the muscles of the lower limbs and trunk, board-like abdomen, and lumbar hyperlordosis with pain, and he was unable to move the left eyeball fully to the left without developing diplopia. The tongue was poorly mobile and markedly stiff. The patient was examined while lying supine. During the examination, he exhi-




Fig. 1. Left rectus abdominis muscle – 21 MUP (Motor Unit Potentials) analysed in MultiMUP programme.

Histogram MUP: Mean All MUP: 309.7 uV, 5.98 usec, 2.9 phases, 2.8 turns, polyphasic 5%.

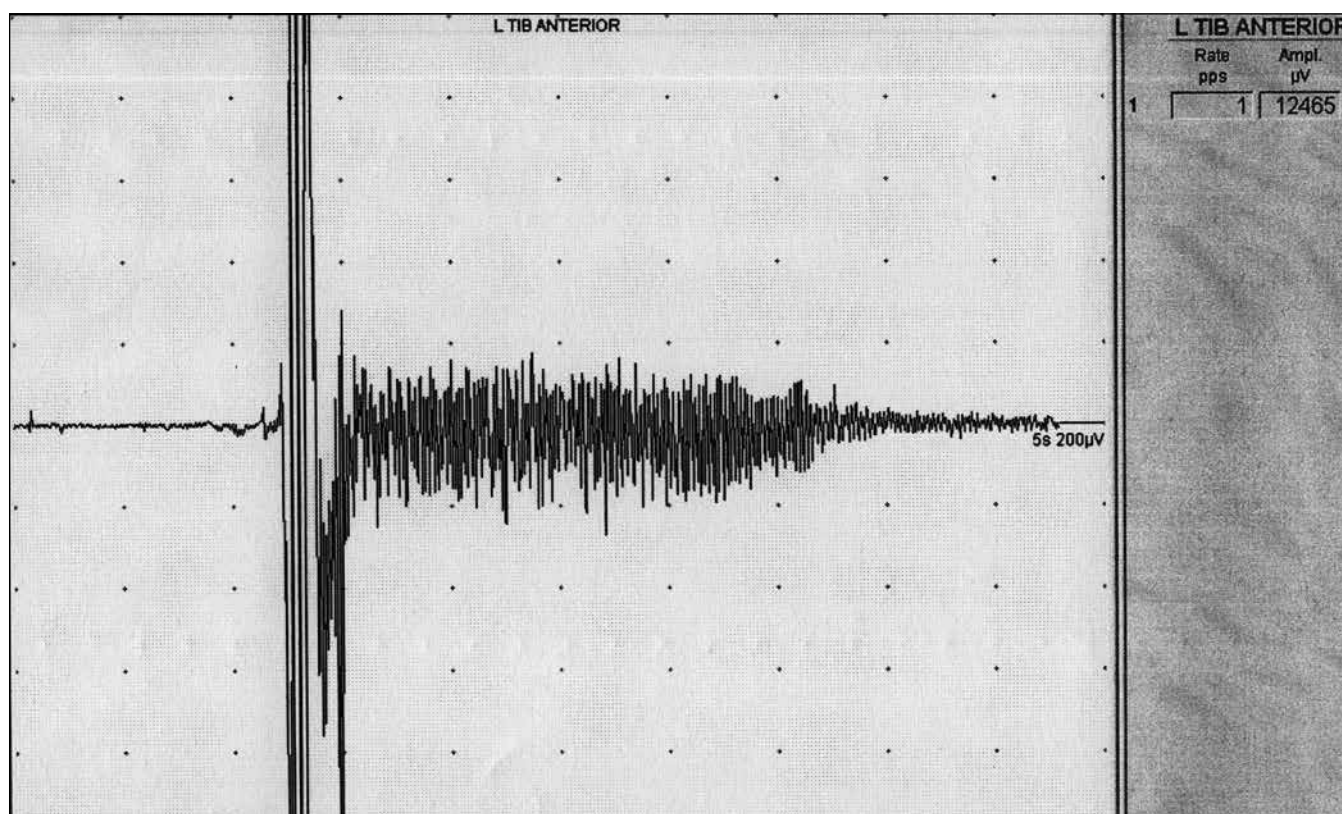


Fig. 2. Left tibialis anterior muscle – mechanical irritation of muscle membrane (move of needle electrode) with high-voltage potential with subsequent myotonic discharge.

bited attacks of muscular hypertonia, accompanied by anxiety, sweating, tachycardia, and mydriasis.

He had elevated levels of creatine kinase – 6.6 $\mu\text{kat/L}$, while the normal levels are up to 3.9 $\mu\text{kat/L}$ – and lactate dehydrogenase – 5.69 $\mu\text{kat/L}$, while the normal levels are 1.67–3.17 $\mu\text{kat/L}$.

Computed tomography scan of the chest, ultrasound of the abdomen, and magnetic resonance imaging of the brain and cervical spine were normal. Urological examination revealed urinary retention associated with urinary bladder dysfunction (slightly hyposensitive bladder with normal capacity). Dysphagia was confirmed, manifested as significantly prolonged oral preparatory and oral transport phases. Swallowing liquids required considerable effort. Cardiac examination revealed only an insignificant atrial septum aneurysm, with a 15 mm excursion into the left atrium (on echocardiography). Serum anti-GAD65 level was below 5 U/mL; amphiphysin antibodies were not found. The patient's cerebrospinal fluid was normal without any evidence of anti-GAD antibodies.

On EMG, motor and sensitive neurography was within normal limits. An examination using a concentric needle electrode revealed continuous motor unit activity in the paravertebral, rectus abdominis, and vastus lateralis muscles. An analysis of the motor unit potentials (using MultiMUP programme) disclosed motor unit potentials that were mildly lower and shorter than normal (Fig. 1). Infrequent myotonic discharges were detected in the first dorsal interosseus and anterior tibial muscles (Fig. 2).

Next, genetic testing was performed; it revealed expansion in the zinc finger protein 9 gene on the 3rd chromosome, thus providing evidence of myotonic dystrophy type 2.

Muscle biopsy (of the right vastus lateralis muscle) revealed only minimal morphological changes in the muscle tissue (that, however, was compatible with the diagnosis of myotonic dystrophy type 2) – only a few angular atrophic fibers were present.

Treatment with baclofen (100 mg) and tetrazepam (75 mg) resulted in partial alleviation of spasms and only a small re-

duction of board-like rigidity of the trunk muscles. Therefore, we administered 4.5 g of intravenous methylprednisolone. Within several days, the patient was able to stand up and move around, his diplopia resolved and 14 days later the indwelling catheter was removed. He was started on azathioprine (50 mg twice daily) and was discharged home with prednisone (10 mg daily) and baclofen (75 mg). However, after two months, he developed muscle stiffness, spasmodic attacks, and urinary retention that required catheterization. He was readmitted and was given 5 g of intravenous methylprednisolone. He exhibited a considerable – yet only a partial – regression of the signs and symptoms. Subsequently, he was given 30 g of intravenous immunoglobulins, leading to a complete remission of the signs and symptoms. At the present time, the patient is stable on prednisone (20 mg) and baclofen (10-10-25 mg). Every six weeks, intravenous immunoglobulin (30 g per session) is administered.

We have searched for myotonic dystrophy type 2 in the patient's family and have found reliable data related to his fa-

Tab. 1. SPS – diagnostic criteria [1].

Core diagnostic criteria	a) Positive <ul style="list-style-type: none"> • stiffness and rigidity in axial muscles- abnormal axial posture • stimulus-sensitive spasms • electromyographic evidence of continuous motor unit activity
	b) Negative <ul style="list-style-type: none"> • absent brainstem, pyramidal, extrapyramidal and lower motor neuron signs • no sphincter disturbance • no sensory disturbance • absence of chronic pain syndrome • no cognitive impairment
Supplementary diagnostic criteria	<ul style="list-style-type: none"> • stiffness and rigidity in proximal limb muscles • resolution of stiffness and rigidity with intravenous benzodiazepines • EMG evidence of abnormal exteroceptive reflexes • serum anti-GAD antibodies • non-habituating startle response • non-habituating head retraction reflex
Associated clinical features	<ul style="list-style-type: none"> • oculomotor signs • paroxysmal dysautonomia • paroxysmal fear

ther; he had muscle stiffness and experienced difficulty walking after the age of 50. Genetic testing was not conducted.

Discussion

In 1956, Moersch and Woltman presented a series of 14 patients (10 men and four women), collected over a period of 32 years, who exhibited fluctuating rigidity, spasms, and gait disturbances without evidence of an extrapyramidal or pyramidal disorder. The condition was called "stiff man syndrome" and later renamed SPS or Moersch-Woltman syndrome [6]. Traditional SPS is one of a spectrum of related disorders – stiff limb syndrome, jerking SPS, and progressive encephalomyelitis with rigidity and myoclonus (PERM). To make the diagnosis of SPS, electromyographic findings of continuous activity of normal MUP are required, in addition to clinical symptoms including muscle stiffness and spasms [1]. Core and supplementary diagnostic criteria, as well as associated clinical features are summarized in Tab. 1. Our pa-

tient fulfilled all the core positive and negative criteria. Auditory stimulation (in the form of clicking sounds) used to elicit brainstem auditory evoked potentials (BAEP) had to be interrupted after a few seconds, and repeated attempts to resume the study failed to make the patient tolerate the stimulation. Of the supplementary diagnostic criteria, he did not have anti-GAD65 antibodies in the blood or cerebrospinal fluid. Not only SPS but also a broad spectrum of autoimmune diseases with anti-GAD65 – cerebellar ataxia, idiopathic limbic encephalitis, diabetes mellitus type 1 – is associated with high levels of anti-GAD65 [7]. Our patient had marked oculomotor signs and symptoms with fluctuating reduction of eyeball (especially the left eyeball) movement towards the left and diplopia, quite severe paroxysmal autonomic dysfunction and marked episodes of anxiety. During the course of the disease, the patient also developed urinary bladder dysfunction consisting of detrusor sphincter dyssynergia and reduced bladder capacity.

Muscle stiffness and the presence of spasms are the two core motor symptoms of SPS. Muscle rigidity is characterized by increased tone and stiffness. It develops gradually and initially affects the muscles of the trunk; subsequently, it spreads to the lower and upper limbs. It is characterized by permanent co-contraction of agonists and antagonists, which manifests as board-like rigidity of the abdominal wall and the back muscles and as lumbar hyperlordosis. The rigidity is followed by episodic muscle spasms that develop suddenly and are triggered by auditory and tactile stimuli or emotional instability. Episodic spasms are a frequent cause of falls in patients who are still able to ambulate [1,8,9]. Our patient developed rigidity of the trunk and lower limb muscles over several months. Therefore, he was unable to stand or sit in a wheelchair and was only able to lie in a supine position. He did not have any signs and symptoms of an extrapyramidal or pyramidal disorder. The less common signs and symptoms exhibited by the patient included the oculomotor dysfunction and fluctuating convergent strabismus. From the onset of the disease, the patient had urinary bladder dysfunction consisting of detrusor hyperfunction and low bladder capacity. As the rigidity spread to the bulbar area and the neck muscles, the patient developed dysphagia, mainly when eating solids. A focused assessment (Daniel's test) showed prolonged oral transport phase and rigid muscles, especially the tongue muscles. The patient's dysphagia resolved after he was started on corticosteroids.

Continuous activity at rest is an important diagnostic finding – this is a case of a normally shaped MUP. Co-contraction is another characteristic feature – an antagonist is activated during movement in one direction, resulting in cessation of the movement and stiffening of segmental mobility. At the same time, the co-contraction mechanism leads to maintenance of muscle hypertonia in the antagonist groups. However, in SPS, spontaneous pathological activity – fibrillation, fasciculation, myokymia, and neuromyotonic or myotonic discharges – do not develop [2,10,11]. We ascertained that our patient had continuous activity of the motor units in the trunk and lower limb muscles. At the same time, we identified several myotonic discharges in the thigh muscles.

Therefore, we requested genetic testing, and this confirmed myotonic dystrophy type 2. Subsequent muscle biopsy revealed only slight dystrophic changes consistent with myotonic dystrophy type 2.

Myotonic dystrophy type 2 (DM2) is a dominantly inherited multisystem disorder, characterized by progressive proximal weakness, myotonia, cataracts and cardiac abnormalities. In patients with DM2, there is an increased frequency of autoimmune diseases and serum autoantibodies compared to patients with adult onset DM1 [12]. In patients with DM2, there is a relative frequency of abnormally elevated laboratory values (greater than by 50%) on several immunological tests. In addition, serum levels of IgG were low in 75% of all patients with DM2 who were tested, and absolute lymphocyte counts were low in 54% [13]. Our patient had no cataract or cardiac abnormalities; however, his handgrip release was moderately slow, the tongue was stiff and narrow, and some slowing of upper lid movement on downward gaze was noted. His EMG detected several myotonic discharges and MUPs of moderate duration with an amplitude lower than normal. Creatine kinase and lactate dehydrogenase levels were repeatedly elevated, IgG levels were always in the normal range, and absolute lymphocyte counts were at the lower limit or just below it: $0.78 \times 10^9/l$ (0.8–4.0).

Symptomatic treatment of SPS consists of benzodiazepines and baclofen (administered orally as well as intrathecally). Corticosteroid therapy was found to be effective in patients with autoantibody production. However, administration of intravenous immunoglobulins appears to be the most successful therapy [1,2]. The treatment of our patient

first involved administration of baclofen 100mg orally in combination with tetrazepam. As far as muscle hypertonia was concerned, the patient only partially responded to the therapy. Therefore, we administered 5g of intravenous methylprednisolone, followed by a maintenance dose of prednisone and initiated azathioprine therapy. Despite this treatment, the patient had a relapse 2.5 months later. Because of muscle hypertonia and pain, he was unable to walk and was able to sit in a wheelchair for only short periods of time; his spasms were severe. For that reason, we administered another bolus of intravenous methylprednisolone (5g) and this markedly improved his condition. Because of persisting signs and symptoms (muscle hypertonia, urinary urgency, and slow walking as well as slow speech), we administered 30g of intravenous immunoglobulins. The patient's condition resolved almost completely. He was able to run, and his urinary problems disappeared. Currently, the patient is stable on the following medication regimen – 20mg of prednisone, 45mg of baclofen, and 30g of intravenous immunoglobulins every six weeks.

Conclusion

Myotonic dystrophy type 2 is associated with a production of autoantibodies, the presence of autoreactive T-cells, and an increased frequency of autoimmune diseases. SPS has primarily an autoimmune etiology and is characterized by gradual development of muscle stiffness of the axial muscles subsequently spreading to the limbs, and by spasms. In our patient, myotonic dystrophy type 2 was diagnosed on the basis of electrophysiology (reduced duration and amplitude of MUPs and the presence of myotonic dis-

charges) and genetic testing. Diagnosis of SPS was based on the presence of clinical and EMG findings that are characteristic of the disease. DM2 probably affected the clinical manifestations of the patient's SPS. SPS was successfully treated with immunosuppression (prednisone), intravenous immunoglobulins and baclofen.

References

1. Duddy ME, Baker MR. Stiff Person syndrome. In: Pourmand R (ed). Immune-mediated neuromuscular diseases. Basel: Karger 2009: 147–165.
2. Amato AA, Russel JA. Neuromuscular Disorders. New York: McGraw – Hill Companies 2008.
3. Arrabal-Polo MA, Palao-Yago F, Zuluaga-Gomez A. Urodynamic study alterations in a patient with stiff person syndrome. *Int J Urol* 2010; 17(5): 587–588.
4. Burns TM. A step forward for the stiff-person syndrome. *Lancet* 2005; 365(9468): 1365–1367.
5. Hadavi S, Noyce AJ, Leslie D, Giovannoni G. Stiff person syndrome. *Pract Neurol* 2011; 11(5): 272–282.
6. Moersch FP, Woltman HW. Progressive fluctuating muscular rigidity and spasm („stiff-man” syndrome): report of a case and some observations in 13 other cases. *Proc Staff Meet Mayo Clin* 1956; 31(15): 421–427.
7. Saiz A, Blanco Y, Sabater L, Gonz  les F, Bataller L, Casamitjana R et al. Spectrum of neurological syndromes associated with glutamic acid decarboxylase antibodies: diagnostic clues for this association. *Brain* 2008; 131(10): 2553–2563.
8. Levy ML, Dalakas MC, Floeter MK. The stiff-person syndrome: an autoimmune disorder affecting neurotransmission of gamma-aminobutyric acid. *Ann Intern Med* 1999; 131(7): 522–530.
9. Goodson B, Martin K, Hunt T. Stiff person syndrome presenting with sudden onset of shortness of breath and difficulty moving the right arm: a case report. *J Med Case Reports* 2010; 4: 118–123.
10. Rakocevic G, Floeter MK. Autoimmune stiff person syndrome and related myelopathies: understanding of electrophysiological and immunological processes. *Muscle Nerve* 2012; 45(5): 623–634.
11. Oh SJ. Clinical electromyography. Case studies. Baltimore: Williams & Wilkins 1998.
12. Tieleman AA, den Broeder AA, van de Logt AE, van Engelen BG. Strong association between myotonic dystrophy type 2 and autoimmune diseases. *J Neurol Neurosurg Psychiatry* 2009; 80(11): 1293–1295.
13. Heatwole C, Johnson N, Goldberg B, Martens W, Moxley R jr. Laboratory abnormalities in patients with myotonic dystrophy type 2. *Arch Neurol* 2011; 69(9): 1180–1184.