

# Early Rotation of Intrathecal Baclofen Pump – a Case Report

## Časná rotace intratékální baklofenové pumpy – kazuistika

### Abstract

**Background:** Intrathecal baclofen (ITB) delivered by programmable pump devices represents an important modality for long-term treatment of severe spasticity when resistance to oral drugs and/or their severe side effects may occur. Despite generally favorable outcomes and relative safety of this method, complications associated with ITB can be observed. The most common problems include surgery-related complications resulting from system implantation, including catheter failure. Pump rotation is a rare complication with incidence less than 0.3%. **Case report:** Seventy-four-years-old female suffered from spasticity after chronic spinal cord injury at T9 level. She underwent successful implantation of ITB pump (Medtronic, Synchromed II) with prompt spasticity relief on baclofen dose of 100 µg/day. During the first outpatient appointment, it was difficult to puncture and fill the reservoir with baclofen. Plain x-ray revealed rotation of the pump with reservoir in downright position. On the same day, the patient underwent emergency surgical revision with correction of the pump position and refill of the reservoir. No baclofen withdrawal syndrome or other complications occurred and the patient recovered well. **Conclusion:** Pump rotation is a very unusual and rare complication of ITB treatment. Its prompt management in specialized centers can prevent an urgent situation such as acute withdrawal syndrome after sudden interruption of baclofen delivery.

### Souhrn

**Úvod:** Léčba intratékálním baklofenem (ITB) kontinuálně pomocí pumpových systémů je důležitou léčebnou modalitou u nemocných s těžkou spasticitou, která již nezabírá na perorální léky nebo když se objeví výrazné nežádoucí účinky. Tato metoda je relativně velmi bezpečná, přesto se ale mohou vyskytnout komplikace spojené s touto léčbou. Nejčastěji se objevují komplikace spojené s implantací systému. Jde zejména o problémy s katétrem. Rotace pumpy je extrémně vzácnou komplikací a její výskyt je méně než 0,3 %. **Kazuistika:** U 74leté ženy s těžkou spasticitou po chronickém míšním poranění ve výši Th9 byla úspěšně provedena implantace baklofenové pumpy (Medtronic, Synchromed II). Pacientka měla bezprostřední úlevu se snížením spasticity již na dávce baklofenu 100 µg/den. Na první ambulantní kontrole se opakovaně nezdařilo doplnit rezervoár pumpy. Bylo vysloveno podezření na její rotaci. Pacientka byla okamžitě odeslána na rentgenologické vyšetření, kde bylo potvrzeno přetočení pumpy o 180 stupňů. Tentýž den byla pacienta v lokální anestezii operována, pumpa byla otočena a důkladně zafixována stehy. Vzhledem k rychlé revizi se u pacientky nerozvinul syndrom z náhlého odnětí baklofenu při prázdném rezervoáru pumpy. **Závěr:** Rotace pumpy je vzácná komplikace léčby ITB. Je nutné okamžité vyřešení tohoto problému, neboť hrozí rozvoj abstinčního syndromu z náhlého odnětí baklofenu. Léčbu ITB je třeba provádět v centrech se specializovanou péčí o tyto pacienty.

Supported by Czech Research Projects PRVOUK P34 and IGA-NT12282.

The authors declare they have no potential conflicts of interest concerning drugs, products, or services used in the study.

Autoři deklarují, že v souvislosti s předmětem studie nemají žádné komerční zájmy.

The Editorial Board declares that the manuscript met the ICMJE "uniform requirements" for biomedical papers.

Redakční rada potvrzuje, že rukopis práce splnil ICMJE kritéria pro publikace zasílané do biomedicínských časopisů.

I. Stetkarova<sup>1</sup>, L. Mencí<sup>2</sup>

3<sup>rd</sup> Faculty of Medicine, Charles University and Hospital Kralovské Vinohrady, Prague:

<sup>1</sup> Department of Neurology

<sup>2</sup> Department of Neurosurgery



Ivana Stetkarova, MD, PhD

Department of Neurology

3<sup>rd</sup> Faculty of Medicine

Charles University and Hospital

Kralovské Vinohrady

Ruska 87

100 00 Prague 10

e-mail: ivana.stetkarova@fnkv.cz

Accepted for review: 7. 7. 2015

Accepted for print: 6. 10. 2015

### Key words

spasticity – intrathecal baclofen – pump systems – complications – pump failure – withdrawal syndrome – case report

### Klíčová slova

spasticita – intratékální baklofen – pumpové systémy – komplikace – selhání pumpy – abstinční syndrom – kazuistika

## Introduction

Numerous studies have shown intrathecal baclofen therapy (ITB) to be efficacious in severe spasticity. However, a variety of complications and side effects linked to ITB treatment may occur [1]. Despite generally favourable outcomes and relative safety of this method complications associated with ITB have been observed as drug-related complications (e.g. overdose or withdrawal), complications resulting from implantation and failure of the system [2]. Catheter malfunctions are the most frequent complications [2,3]. Rarely, problems with pump can also occur, usually resulting in sudden interruption of ITB delivery with baclofen withdrawal syndrome [4–9]. This serious adverse event can be life-threatening and its recognition is an important part of the ITB delivery management. Pump rotation is observed in less than 0.3% [10] of implanted subjects.

We present an unusual and potentially threatening complication of ITB treatment with pump rotation when acute baclofen withdrawal syndrome may occur in a sequence; however, no such a complication was observed in this study due to prompt diagnostic decision and urgent surgical intervention.

## Case report

Since 2003, 42 patients (17 females, aged 20–69 years, 16 with multiple sclerosis, 26 with chronic spinal cord injury) have been treated at the Department of Neurology, 3<sup>rd</sup> Faculty of Medicine, Charles University in Prague with a total of 58 pump systems with intrathecal baclofen delivery (Synchromed EL in five cases, Synchromed II in 53 cases). Patients suffered from severe generalized spinal spasticity that did not respond adequately to physiotherapy and oral medication. All patients were familiar with the risks of intrathecal baclofen delivery during the testing period, pump implantation and follow-up with pump refill and signed an informed consent. All of them were advised of the importance of keeping scheduled refilling visits and were educated on the early symptoms of baclofen withdrawal.

A seventy-four-year-old female suffered from chronic spinal cord injury at T9 level classified as AIS A. She underwent positive baclofen testing for severe spinal spasticity and painful muscle spasms followed by successful implantation of an ITB pump (Synchromed II, Medtronic Inc; Minnesota,

MN, USA). No abnormalities were observed during pump implantation. The patient was slightly overweight with a thick layer of subcutaneous fat. The effective dose was set to 100 µg of baclofen /day during the first week after the pump implantation. The degree of spasticity in the lower limbs decreased from 4 to 1 according to MAS. Patient was dismissed to home care in stable clinical condition. The telemetry unit software calculates an alarm date automatically based on 2 ml of residuum remaining in the pump reservoir. On the first outpatient appointment after the pump implantation the patient was checked clinically and normal neurological status was confirmed. The pump reservoir was refilled by an experienced physician with a sterile technique. However, there was a problem puncturing the central access port. The situation was assessed as a possible abnormal position of the pump, probably with downright position of the reservoir. Plain x-ray showed the pump to be rotated with reservoir in an opposite position (Fig. 1, 2). To prevent possible life-threatening baclofen withdrawal syndrome due to empty reservoir, the patient immediately underwent surgical revision under local anaesthesia. The pump position was corrected and reservoir refilled with baclofen. Neither acute withdrawal syndrome nor any other complication occurred and patient recovered well.

## Discussion

Severe generalized spasticity due to chronic central nervous system impairment is still difficult to influence with conventional methods of treatment [1]. Intrathecal baclofen delivered by programmable pump devices with continuous 24-hour administration has been proved as an important treatment modality for severe spasticity of different aetiologies (e.g. trauma, ischemia, haemorrhage, inflammation, degenerative process or tumour). Clinical efficacy of intrathecal baclofen in reducing spasticity has been demonstrated by several studies. However, associated complications affect its utility and acceptance [1]. Catheter problems are relatively common and more frequent than pump- or surgical procedure-related complications. Catheter complications included kinks, holes, breaks, cuts, dislodgements, disconnections, fibrosis and occlusions [2]. In case of suspected baclofen pump complication, it is recommended to check the pump telemetry to

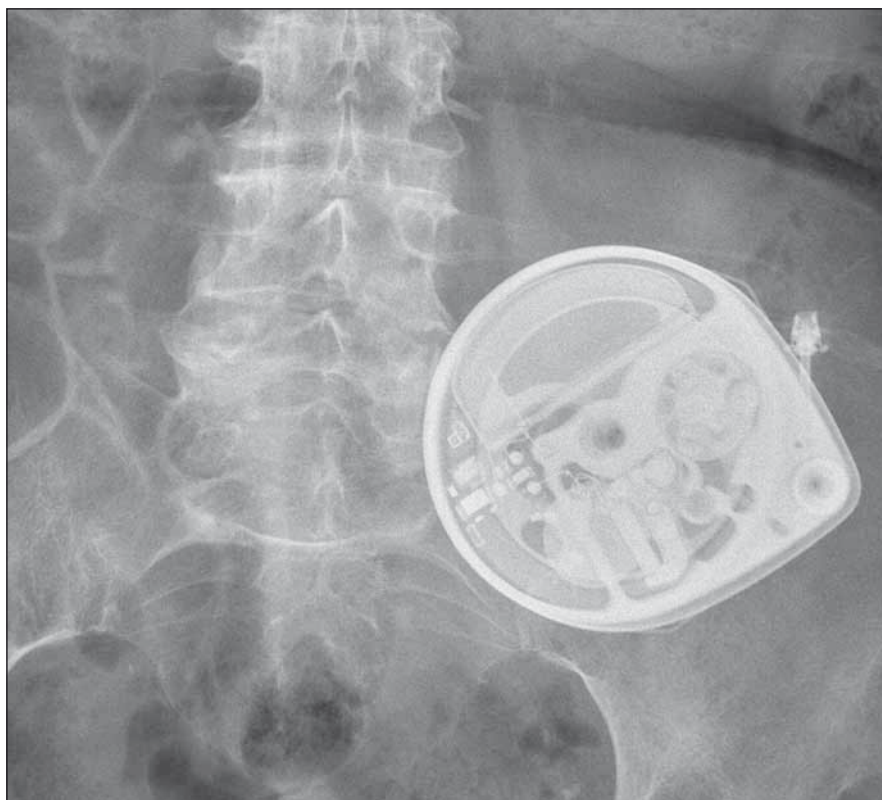
ensure that all mechanical functions are working and that the pump has adequate battery function. X-rays of the pump and catheter system should be obtained and analysed for migrations of the catheter tip, disconnections, kinking or curling of the catheter system [3]. An abrupt cessation of ITB administration can result in a rapid onset of acute baclofen withdrawal syndrome [4–6,9] that includes sudden increase in spasticity of the muscles, starting in lower limbs, itching without rash, hallucinations, hyperthermia, agitation, hallucinations, autonomic dysregulation or epileptic seizures. Baclofen withdrawal syndrome often occurs after human error (defective filling of the pump reservoir, change in the program settings, inappropriate baclofen concentration), catheter problem or pump failure (insufficient or no dosage) [8,9]. Severe withdrawal signs can result in a life-threatening situation with rhabdomyolysis, renal failure and coma requiring intensive care and assisted ventilation. Appropriate diagnosis before treatment initiation is critical as therapies utilized to manage complications associated with acute baclofen withdrawal may require institution of mechanical ventilation and additional neurocritical care expertise.

Baclofen overdose represents another drug-related complication linked to ITB administration [11]. Acute baclofen overdose usually arises after human error during baclofen filling into the pump reservoir. The overdose may occur when a too high dose of the drug, wrong concentration or improper bridging dose of the drug is used, or an error in pump programming is made. Symptoms of overdose include excessive muscles weakness starting in lower limbs, fatigue, hypotension, sedation, sleepiness, dizziness, nausea and vomiting, seizures or coma requiring intensive care and assisted ventilation. Acute ITB overdose is managed with immediate cessation of baclofen delivery through the system, reducing the baclofen load by cerebrospinal fluid aspiration and by providing supportive treatment in an intensive care setting. There is no specific antidote for reversing overdose symptoms.

The most common complications during surgical implantation of a pump system include local bleeding, local tissue damage, leakage of cerebrospinal fluid and infection [12,13]. A subcutaneous pocket around the pump leads sometimes to a fluid collection (seroma) that is usually absorbed within 1–2 weeks. If it persists longer, a sur-

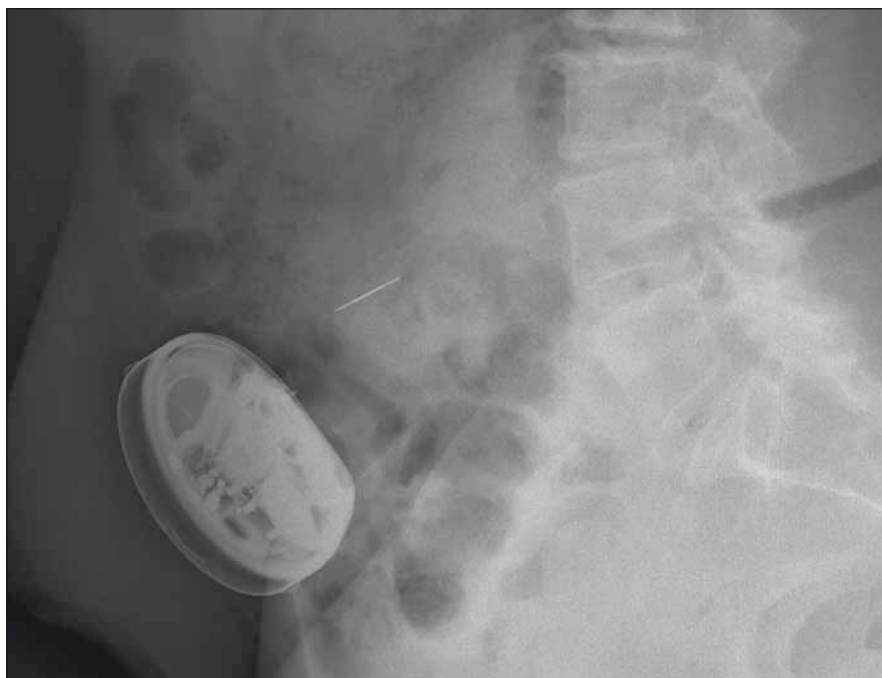gical revision is recommended. An infection that may occur after the pump implantation anywhere alongside the implanted system represents another serious complication of ITB delivery. Severe infections could lead to removal of the entire pump system [14]. There is a risk of sepsis, meningitis or meningoencephalitis, even though these events are rare [15]. Rapid identification of infectious agents is recommended, followed by a high dose of microbe-specific antibiotics. The preventive measures include sterile technique of pump system implantation and preventive intraoperative administration of antibiotics. Technical problems with puncture of intrathecal space can lead to leakage of cerebrospinal fluid. Blood patch of 15–20 ml of autologous blood in the epidural space to replace epidural perforation is recommended [13]. Prevention of this complication is paramedian puncture approach and meticulous suture around the catheter to anchor it.

When a failure of the pump is suspected, X-ray prior to and after a single baclofen bolus at the smallest size within the shortest period of application is performed to review rotation of the pump rotor. Normal function of the rotor is 1/4 turn of the pump. The most common pump complications include pump overflow, twisting, damage and battery failure. However, pump flipping or twisting occurred on a few occasions only, in less than 0.3% of implanted subjects [8–10]. The “Twiddler syndrome” has already been reported in pacemaker systems [16]. Foreign-body reaction has also been reported as a very rare complication [17]. Rarely, repeated MRI can induce pump memory error [18]. Overloading of the pump may cause reservoir damage and overdose the patient. When fixation of the pump is inappropriate or patient increases his/her weight, the pump may roll over with increased pressure on the catheter attached to the pump. When the drug remains in the pump reservoir for longer than its permitted use (more than 180 days for Synchromed II), pump corrosion may occur, leading to system malfunction [5,9]. It is recommended to use one drug only in the reservoir. However, good experience with baclofen and morphine has been reported for treatment of pain and spasticity without any pump complication [19]. Battery life of the pump is estimated to be up to 6–7 years. Subsequently, it must be replaced. An original package with antibacterial filter should be used for



**Fig. 1. Pump rotation in downright position.**

Axial X-ray scan.



**Fig. 2. Pump rotation in downright position.**

Sagittal X-ray scan.

sterile filling of the reservoir pump to prevent infection of the intrathecal space. The pump is recommended to be implanted in

the subcutaneous pocket or under the fascia of the anterior rectus and external oblique muscles with well described benefits and

pitfalls of each technique. We prefer to place the pump subcutaneously so as to preserve the subfascial plane in case of a complication. In patients with extensive abdominal surgery or severe scoliosis, the infraclavicular fossa may be the alternative to the abdominal wall for placement of the pump [20]. The most effective method of reducing the risk of pump rotation is to avoid oversized subcutaneous or subfascial pocket. Furthermore, no absorbable sutures can be used to anchor the pump through suture loops to the anterior rectus fascia or the posterior rectus fascia. Even so, the sutures can be still pulled out by extensive force. In order to facilitate anchoring of the pump, a sock fitted over the pump can be used that can promote scar formation [21].

## Conclusion

Prompt recognition of an ITB complication, especially when ITB withdrawal syndrome is suspected, and its appropriate urgent solution are critical. Successful indication, implantation and follow-up of intrathecal pump systems need comprehensive professional training, thorough knowledge of complications and safety administration in the hands of a multidisciplinary team in specialized centers.

## References

1. Motta F, Antonello CE. Analysis of complications in 430 consecutive pediatric patients treated with intra-

thecal baclofen therapy: 14-year experience. *J Neurosurg Pediatr* 2014; 13(3): 301–306. doi: 10.3171/2013.11.PEDS13253.

2. Stetkarova I, Yablon SA, Kofler M, Stokic DS. Procedure- and device-related complications of intrathecal baclofen administration for management of adult muscle hypertonia: a review. *Neurorehabil Neural Repair* 2010; 24(7): 609–619. doi: 10.1177/1545968310363585.

3. Coffey RJ, Edgar TS, Francisco GE, Graziani V, Meythaler JM, Ridgely PM et al. Abrupt withdrawal from intrathecal baclofen: recognition and management of a potentially life-threatening syndrome. *Arch Phys Med Rehabil* 2002; 83(6): 735–741.

4. Taira T, Ueta T, Katayama Y, Kimizuka M, Nemoto A, Mizusawa H et al. Rate of complications among the recipients of intrathecal baclofen pump in Japan: a multicenter study. *Neuromodulation* 2013; 16(3): 266–272. doi: 10.1111/ner.12010.

5. Ross JC, Cook AM, Stewart GL, Fahy BG. Acute intrathecal baclofen withdrawal: a brief review of treatment options. *Neurocrit Care* 2011; 14(1): 103–108. doi: 10.1007/s12028-010-9422-6.

6. Siegfried RN, Jacobson L, Chabal C. Development of an acute withdrawal syndrome following the cessation of intrathecal baclofen in a patient with spasticity. *Anesthesiology* 1992; 77(5): 1048–1050.

7. Mohammed I, Hussain A. Intrathecal baclofen withdrawal syndrome – a lifethreatening complication of baclofen pump: a case report. *BMC Clin Pharmacol* 2004; 4: 6.

8. Coffey RJ, Edgar TS, Francisco GE, Graziani V, Meythaler JM, Ridgely PM et al. Abrupt withdrawal from intrathecal baclofen: recognition and management of a potentially life-threatening syndrome. *Arch Phys Med Rehabil* 2002; 83(6): 735–741.

9. Stetkarova I, Brabec K, Vasko P, Mencl L. Intrathecal baclofen in spinal spasticity: frequency and severity of withdrawal syndrome. *Pain Physician* 2015; 18(4): E633–E641.

10. Riordan J, Murphy P. Intrathecal pump: an abrupt intermittent pump failure. *Neuromodulation* 2014; 18(5): 433–435. doi: 10.1111/ner.12258.

11. Watve SV, Sivan M, Raza WA, Jamil F. Management of acute overdose or withdrawal state in intrathecal

baclofen therapy. *Spinal Cord* 2012; 50(2): 107–111. doi: 10.1038/sc.2011.112.

12. Follet KA, Burchiel K, Deer T, DuPen S, Prager J, Turner MS et al. Prevention of intrathecal drug delivery catheter-related complications. *Neuromodulation* 2003; 6(1): 32–41. doi: 10.1046/j.1525-1403.2003.03005.x.

13. Dominguez E, Latif O, Rozen D, Sahinler B, Orbezgozo M, Edmunds A et al. Subdural blood patch for the treatment of persistent CSF leak after permanent intrathecal catheter implantation: a report of two cases. *Pain Pract* 2001; 1: 344–353.

14. Follet KA, Boortz-Marx RL, Drake JM, DuPen S, Schneider SJ, Turner MS et al. Prevention and management of intrathecal drug delivery and spinal cord stimulation system infections. *Anesthesiology* 2004; 100(6): 1582–1594.

15. Wunderlich C, Krach LE. Gram-negative meningitis and infections in individuals treated with intrathecal baclofen for spasticity: a retrospective study. *Dev Medicine Child Neurol* 2006; 48(6): 450–455.

16. Schulten HK, du Mesnil de Rochemont W, Jochem W, Baldus O, Grosser KD, Behrenbeck DW. Interference of pacemaker stimulation due to battery rotation (pacemaker-twiddler syndrome). *Med Welt* 1975; 26(31–32): 1406–1407.

17. Bernuz B, Assier H, Bisseriex H, Thiebaut JB, Rech C, Schnitzler A. Intrathecal baclofen pump: a foreign-body reaction case report and its solution. *J Rehabil Med* 2012; 44(2): 184–185. doi: 10.2340/16501977-0918.

18. Kosturakis A, Gebhardt R. SynchroMed II intrathecal pump memory errors due to repeated magnetic resonance imaging. *Pain Physician* 2012; 15(6): 475–477.

19. Saulino M. Simultaneous treatment of intractable pain and spasticity: observations of combined intrathecal baclofen-morphine therapy over a 10-year clinical experience. *Eur J Phys Rehabil Med* 2012; 48(1): 39–45.

20. Rocque BG, Albright AL. Infraclavicular fossa as an alternate site for placement of intrathecal infusion pumps: technical note. *Neurosurgery* 2010; 66(2): 402–403. doi: 10.1227/01.NEU.0000363597.56986.C4.

21. Vender JR, Hester S, Waller JL, Rekito A, Lee MR. Identification and management of intrathecal baclofen pump complications: a comparison of pediatric and adult patients. *J Neurosurg* 2006; 104 (Suppl 1): 9–15.