

# Frameless Image-guided Stereotactic Brain Biopsy – Advantages, Limitations, and Technical Tips

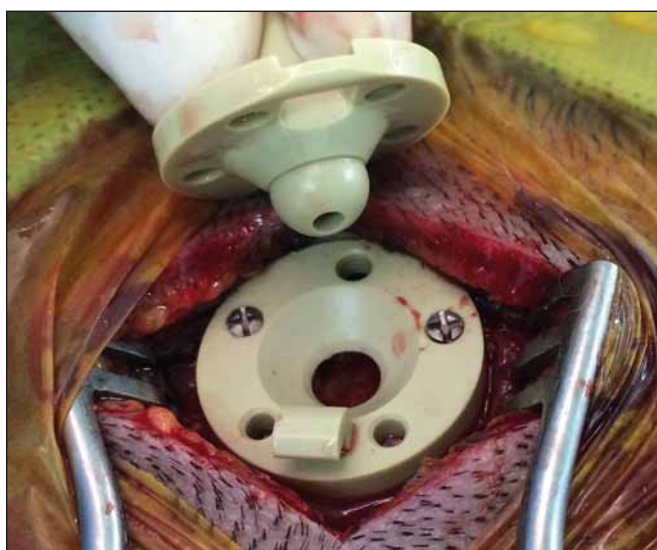Stereotaktická biopsie mozku pomocí bezrámové navigace –  
výhody, omezení a technické tipy

Dear editors,

Stereotactic biopsy is a routine procedure that is performed in all neurosurgical centres. The purpose of stereotactic biopsy is to obtain an accurate histological diagnosis with minimal morbidity. Traditionally, frame-based stereotactic biopsy has been the gold standard for the sampling of intracranial lesions [1–5]; however, frameless techniques have been adopted by many neurosurgeons, and some reports suggest that frameless stereotactic biopsy is comparable to or better than the traditional frame-based method [1,6,7]. Frame-based techniques are still preferred in specific conditions because of the limitations of the frameless technique [8]. We have experienced the advantages and limitations of frameless stereotactic biopsy and obtained important technical considerations for the procedure.

Frameless stereotactic biopsy has many advantages relative to frame-based biopsy, with the largest advantage being convenient preoperative preparation and high patient satisfaction due to the fact that preoperative frame application is not necessary. Additionally, unlike frame-based biopsy, the biopsy target can be modified or adapted as necessary at any time during the procedure in frameless biopsy. However, there are some limitations to frameless biopsy. For example, the direction of the catheter is subject to change during advancement. Additionally, errors in preoperative computed tomography image matching can affect the navigation system and decrease procedural accuracy for small or deeply seated lesions. For these reasons, Owen et al. [6] reported that 80% of lesions are candidates for frameless biopsy, while the remaining 20% of lesions still depend on frame-based biopsy methods.

Another limitation of frameless biopsy is that the tilt angle of the catheter from the entry point to the target is narrow. In a frame-based biopsy, there is no limitation on the tilt angle of the catheter, such that the possible entry point area is wide. In our institution, we used a fixing adaptor (Stryker Corporation, Kalamazoo, USA) for the guiding stylet that consisted of a fixed part and a movable part



**Fig. 1.** The adaptor used to fix the guiding stylet during frameless biopsy.

The fixed part was fitted into the burr hole and the movable part allowed the insertion of the guiding stylet.

The authors declare they have no potential conflicts of interest concerning drugs, products, or services used in the study.

Autoři deklarují, že v souvislosti s předmětem studie nemají žádné komerční zájmy.

The Editorial Board declares that the manuscript met the ICMJE “uniform requirements” for biomedical papers.

Redakční rada potvrzuje, že rukopis práce splnil ICMJE kritéria pro publikace zasílané do biomedicínských časopisů.

**T. S. Jeong, G. T. Yee, W. K. Kim,  
C. J. Yoo, E. Y. Kim, M. J. Kim**

Department of Neurosurgery, Gachon  
University Gil Medical Center, Incheon,  
Korea



**G. T. Yee, MD**

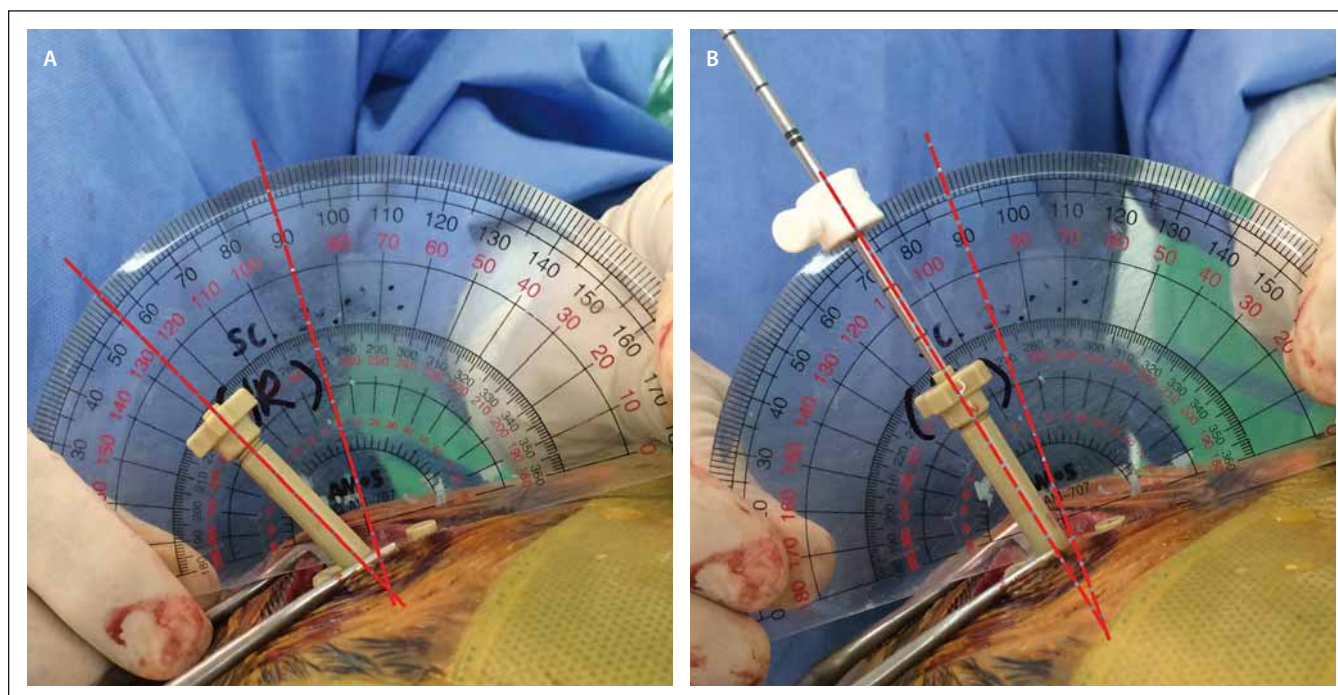
Department of Neurosurgery  
Gachon University Gil Medical Center  
21 Namdong-daero 774 beon-gil  
Namdong-gu, Incheon 405760  
Korea  
e-mail: gtyee@gilhospital.com

Accepted for review: 4. 7. 2017

Accepted for print: 11. 9. 2017

(Fig. 1). While the maximum tilt angle of the movable part was 35° without the guiding stylet, it was reduced to 15° when the guiding stylet was inserted (Fig. 2). As a result, the area available for the entry point was limited. Thus, when the lesion size was small with superficial placement, the entry point could not be placed distant from the target.

Given the limitations listed above, caution is required during preoperative planning for frameless biopsy procedures. The distance between the entry point and lesion should be minimised, and the eloquent



**Fig. 2. Maximum tilt angles of the movable part of the adaptor.**

A) Without a guiding stylet, the maximum tilt angle was 35°; B) With the guiding stylet inserted, the maximum tilt angle was limited to 15°.

area should be avoided as much as possible. If the lesion is located in an eloquent area close to the cortex, the entry point can be placed close to the lesion. The most common entry points are Kocher's point and the parietooccipital point, which are known to minimise the damage of eloquent area and vessels. However, because frameless biopsy makes it impossible to use a given entry point if the angle between the perpendicular line to the cortex and the target trajectory is more than 15°, it is necessary to plan a suitable entry point using preoperative magnetic resonance images or 3-dimensional images reconstructed with the navigation system.

When a burr hole is made to apply the adaptor, the direction of the adaptor is determined by the direction of the burr hole. An exact trajectory can be most easily obtained when the burr hole is made perpendicular to the skull. If the burr hole is made obliquely, the intended trajectory becomes more difficult to obtain due to the resultant angle of the adaptor. It is especially easy to make an oblique burr hole in areas of the skull that are particularly round or thick;

therefore, precautions should be taken to make the burr hole as perpendicular to the skull as possible.

Finally, the burr hole should be made in such a manner that the entry point is located in the middle of the hole. If a burr hole is extended to correct initial misplacement, it becomes impossible to fix the adaptor into the hole, because in circumstances where the burr hole size is larger than that of the adaptor, one of two fixing screws cannot be placed on the skull as two screws are driven on both sides of the adaptor to fix it into the hole. In this case, the new entry point and trajectory should be re-confirmed.

A frameless stereotactic biopsy is an efficient and convenient alternative to frame-based biopsy. However, this method has some structural and technical limitations relative to frame-based biopsy, such as a narrow entry point area and an increased likelihood of matching error. Considering these limitations, preoperative imaging should be performed to allow accurate surgical planning for biopsies utilising the frameless technique.

## References

1. Dammers R, Haitsma IK, Schouten JW, et al. Safety and efficacy of frameless and frame-based intracranial biopsy techniques. *Acta Neurochir (Wien)* 2008;150(1):23–9. doi: 10.1007/s00701-007-1473-x.
2. Kim JE, Kim DG, Paek SH, et al. Stereotactic biopsy for intracranial lesions: reliability and its impact on the planning of treatment. *Acta Neurochir (Wien)* 2003;145(7):547–54; discussion 54–5. doi: 10.1007/s00701-003-0048-8.
3. Apuzzo ML, Chandrasoma PT, Cohen D, et al. Computed imaging stereotaxy: experience and perspective related to 500 procedures applied to brain masses. *Neurosurgery* 1987;20(6):930–7.
4. Apuzzo ML, Chandrasoma PT, Zelman V, et al. Computed tomographic guidance stereotaxis in the management of lesions of the third ventricular region. *Neurosurgery* 1984;15(4):502–8.
5. Kim JE, Kim DG. Stereotactic biopsy in brain lesions. *J Korean Neurosurg Soc* 1997;26:1050–8.
6. Owen CM, Linskey ME. Frame-based stereotaxy in a frameless era: current capabilities, relative role, and the positive- and negative predictive values of blood through the needle. *J Neurooncol* 2009;93(1):139–49. doi: 10.1007/s11060-009-9871-y.
7. Zhang QJ, Wang WH, Wei XP, et al. Safety and efficacy of frameless stereotactic brain biopsy techniques. *Chin Med Sci J* 2013;28(2):113–6.
8. Smith JS, Quinones-Hinojosa A, Barbaro NM, et al. Frame-based stereotactic biopsy remains an important diagnostic tool with distinct advantages over frameless stereotactic biopsy. *J Neurooncol* 2005;73(2):173–9. doi: 10.1007/s11060-004-4208-3.