

# Iron deficiency anaemia in cerebral venous sinus thrombosis – cause or association?

## Anémie z nedostatku železa u pacientky s mozkovou žilní trombózou – příčina nebo souvislost?

Dear editor,

The causal relationship between cerebral venous sinus thrombosis (CVT) and iron deficiency anaemia (IDA) as an independent factor remains unclear. CVT is a rare disease, with an incidence of 1.32/100,000 inhabitants in high-income countries and more in lower economies, whereas anaemia is a common global problem affecting millions, particularly children and women of reproductive age. The World Health Organization estimates that one-half of the cases are due to iron deficiency [1]. However, the presentation of CVT could represent a wide spectrum, from encephalopathy coma to an indolent disease with the sole complaint being a headache. Thus, the disease could be more common than expected.

A 46-year-old woman was admitted to the emergency department with a severe, gradually worsening headache present for the past few days, a loss of strength, and numbness on the right side. Her past medical history revealed no neurological complaints other than an occasional tension type headache. She had no previously known chronic diseases, cancer or infection, was taking no medication including oral contraceptives and had no history of smoking or alcohol abuse. Upon physical examination, she was conscious, had no nuchal rigidity or meningeal irritation symptoms and had hypoaesthesia and decreased (4/5) muscle strength on the right upper and lower extremities. Admission blood tests disclosed anaemia with haemoglobin (Hgb) 7.2 g/dL, mean corpuscular volume 64.7 fL, mean corpuscular haemoglobin concentration 26.6 g/dL platelet count 251×10<sup>9</sup>/L. An emergency CT scan showed a broad, expansive, hypodense area harbouring haemorrhagic foci up to 2 cm in the left temporoparietal region (Fig. 1A). Diffusion-weighted MRI revealed restricted diffusion in the left temporoparietal region and

the patient was hospitalized with the preliminary diagnosis of haemorrhagic infarction and CVT (Fig. 1B).

CTA was normal and a repeated brain MRI revealed a large left temporooccipital cortical-subcortical lesion with a focal haemorrhage which was iso-hypointense in T1-weighted images and heterogeneous, hyperintense in T2-weighted images (Fig. 1C) with surrounding oedema that caused compression of the basal ganglia, effacement of the cerebral sulci and a mild mid-line shift to the right affecting the third and the left lateral ventricle. There was no flow in the left transverse and sigmoid sinuses on MRI venography (Fig. 1D). She was treated with anti-edematous therapy and low molecular weight heparin anticoagulation. Further evaluation for anaemia showed serum iron 9 µg/dL, iron binding capacity 436 µg/dL and ferritin 7 ng/mL confirming the diagnosis of iron deficiency anaemia and replacement therapy was started. The suspected cause of anaemia was menorrhagia, overlooked in her history. A basic system work-up for the identification of other causes of CVT including any oncological disorders was also performed.

The headache, sensory and motor deficits improved within a day of treatment. There were no seizures. Control brain MRI performed at the 5th month, when the patient was asymptomatic, showed post-ischemic changes in the left cortical-subcortical temporoparietal region with local gliosis. The left transverse sinus appeared hypoplastic with no recanalization on control MRI venography and the last Hgb level was 13.4 g/dL.

The proposed mechanisms for IDA-associated CVT are thrombocytosis secondary to ID (iron is a regulator of thrombopoiesis), hypercoagulability, hypoxia-related ischaemic damage and increased blood viscosity due to microcytosis and altered erythrocyte

**The Editorial Board declares that the manuscript met the ICMJE “uniform requirements” for biomedical papers.**

Redakční rada potvrzuje, že rukopis práce splnil ICMJE kritéria pro publikace zasílané do biomedicínských časopisů.

**S. Eliaçık, F. Uysal Tan**

Department of Neurology, Hitit University, School of Medicine, Çorum, Turkey



**Funda Uysal Tan, MD**

Department of Neurology

Hitit University

School of Medicine

Erol Olcok Hospital

Çorum

Turkey

e-mail: fundauysaltan@yahoo.com

Accepted for review: 21. 8. 2020

Accepted for print: 24. 2. 2021

morphology [1–3]. In addition, acute haemorrhaging raises platelet adhesiveness and decreases fibrinolytic activity, leading to intravascular thrombogenesis [2].

Iron deficiency anaemia is rarely the sole aetiological factor for CVT, especially in children [2]. Sebire et al reported anaemia in 55% of children with CVT mostly due to ID, however, all had triggering factors and 40% had chronic diseases [2].

Hung et al [4] confirmed an association between IDA and subsequent venous thromboembolisms (VTE) in a population-based study. However, the mean age of the study population was 62.5 years and subjects with VTE had a significantly higher prevalence of several comorbidities such as cancer, heart failure, arterial hypertension, diabetes, hyperlipidaemia, renal disease and obesity

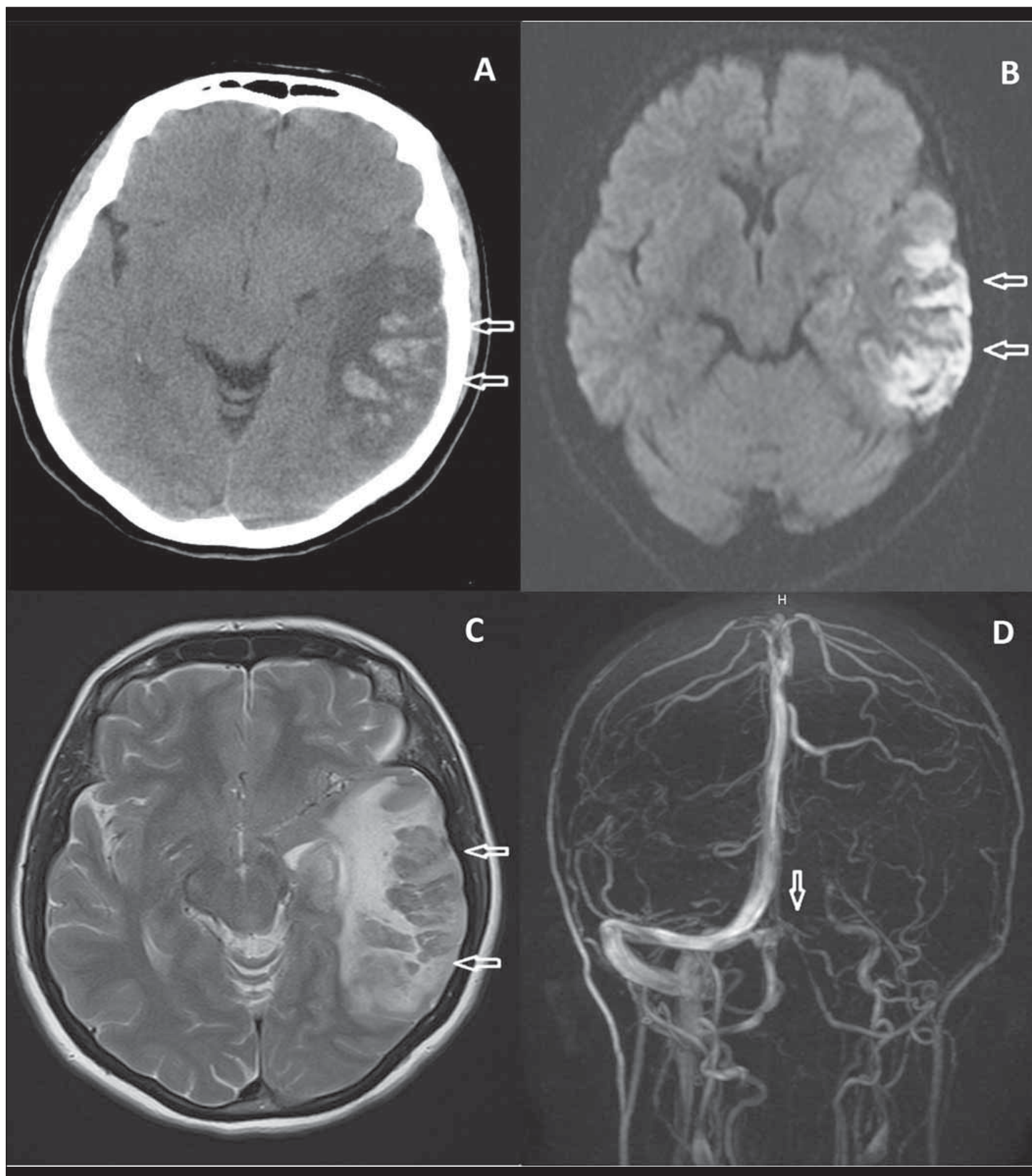


Fig. 1. (A) CT – broad, expansive, hypodense area (arrows) harbouring haemorrhagic foci up to 2 cm in the left temporoparietal region. (B) MRI, diffusion weighted image – restricted diffusion (arrows) in the left temporoparietal region. (C) MRI, T2-weighted image – large left temporooccipital cortical-subcortical hyperintense lesion with focal haemorrhage. (D) MRI venography – absence of flow (arrow) in the left transverse and sigmoid sinuses.

Obr. 1. (A) CT – rozsáhlá expandující hypodenzní oblast (šipky) obsahující až 2 cm velká hemoragická ložiska v levé temporoparietální oblasti. (B) Difúzi vážená MR – restrikce difúze (šipky) v levé temporoparietální oblasti. (C) MR, T2 vážený obraz – vlevo rozsáhlé temporooccipitální kortikální až subkortikální hyperintenzní ložisko s fokální hemoragií. (D) MR venografie – absence průtoku (šipka) v levém sinus transversalis a sinus sigmoideus.

than controls who were healthy. Though the authors had made statistical adjustments, the severity of these comorbidities might differ and there was a lack of treatment information [4]. Conversely, IDA is more common in children and women of reproductive age mainly due to malnutrition and failure to restore blood loss and/or increased demand related to menstruation and pregnancy. Chronic blood loss is the most common cause of IDA particularly in women with menorrhagia. Similarly, Coutinho et al [1] suggested that anaemia was a risk factor for CVT, after adjustment for potential confounders such as age, sex, malignancy, use of oral contraceptives and pregnancy-puerperium, in a large case-control study with, younger subjects (mean ages 40 vs. 48 years for CVT and controls, respectively). However, 70% of their CVT patients were taking oral contraceptives compared to only 21.1% of controls and the incidences of pregnancy, malignancy and previous thrombosis, which were definitely proven risk factors for CVT, were markedly higher in the CVT group. Thus, the adjustments should be performed to exclude these cases.

However, anaemia could be a prognostic factor for CVT as confirmed by Liu et al [5] especially when severe and microcytic de-

spite the limitations mentioned by authors, e.g., selection bias (single centre), small sample size, retrospective analysis and absence of iron levels and recording of fluid administration prior to blood sampling. They suggested that anaemia was a significant and independent predictor of disability and mortality in patients with CVT [5]. Factors such as age, sex, coma, malignancy, intracerebral haemorrhage, and straight sinus and/or deep CVT involved were adjusted. Similarly, Pan et al [6] reported that the top three risk factors for CVT in Chinese patients were obstetric problems (19.8%), infection (17.7%) and anaemia (17.7%). Women are at additional risk for CVT due to the use oral contraceptives (which is comparatively lower than in the West, as mentioned by the authors) or hormonal replacement. Finally, Stolz et al [3] found that severe anaemia was significantly and independently associated with CVT.

As a conclusion, particularly severe IDA appears to be a contributing and prognostic risk factor for CVT. Anaemia is an important component of chronic disorders, however, IDA is very rarely the sole risk factor for CVT.

### Ethical approval

This article does not contain any studies with human participants or animals performed by any of the authors.

### Declaration of patient consent

The authors certify that they have obtained all the appropriate patient consent forms. In the form, the patient has given her consent for her images and other clinical information to be reported in the journal. The patient understands that her name and initials will not be published and due efforts will be made to conceal her identity, but anonymity cannot be guaranteed.

### References

1. Coutinho JM, Zuurbier SM, Gaartman AE et al. Association between anemia and cerebral venous thrombosis: case-control study. *Stroke* 2015; 46(10): 2735–2740. doi: 10.1161/STROKEAHA.115.009843.
2. Sébire G, Tabarki B, Saunders DE et al. Cerebral venous sinus thrombosis in children: risk factors, presentation, diagnosis and outcome. *Brain* 2005; 128(Pt 3): 477–489. doi: 10.1093/brain/awh412.
3. Stolz E, Valdueza JM, Grebe M et al. Anemia as a risk factor for cerebral venous thrombosis? An old hypothesis revisited. Results of a prospective study. *J Neurol* 2007; 254(6): 729–734. doi: 10.1007/s00415-006-0411-9.
4. Hung SH, Lin HC, Chung SD. Association between venous thromboembolism and iron-deficiency anemia: a population-based study. *Blood Coagul Fibrinolysis* 2015; 26(4): 368–372. doi: 10.1097/MBC.0000000000000249.
5. Liu K, Song B, Gao Y et al. Long-term outcomes in patients with anemia and cerebral venous thrombosis. *Neurocrit Care* 2018; 29(3): 463–468. doi: 10.1007/s12028-018-0544-6.
6. Pan L, Ding J, Ya J et al. Risk factors and predictors of outcomes in 243 Chinese patients with cerebral venous sinus thrombosis: a retrospective analysis. *Clin Neurol Neurosurg* 2019; 183: 105384. doi: 10.1016/j.clineuro.2019.105384.

Článek v anglickém jazyce naleznete na webu csnn.eu.