

Large-vessel occlusion in a patient with Emery-Dreifuss muscular dystrophy

Okluze velkých mozkových tepen u nemocné se svalovou dystrofií Emery-Dreifuss

Dear Editors,

Heart problems in individuals with Emery-Dreifuss muscular dystrophy (EDMD) are caused by a number of related complications. Cardiac complications manifest as arrhythmias, atrio-ventricular (AV) conduction blockages, congestive heart failure, and sudden death. Atrial arrhythmias (extrasystoles, atrial fibrillation or flutter, atrial arrest), and less frequently ventricular arrhythmias, are characteristic cardiac problems. Cardiac involvement does not manifest until the age of 20 and develops independently of changes in the neuromuscular system [1]. Patients report palpitations, presyncope and syncope, poor tolerance to stress, and dyspnea. Due to cardiac involvement, patients should be examined in detail using electrocardiography (ECG), Holter ECG monitoring, echocardiography, and invasive electrophysiological examination. Specific treatments for cardiac manifestations are antiarrhythmic therapy, implantation of cardioverter-defibrillator (ICD), and pharmacological and non-pharmacological treatments of cardiac failure. ICD implantation has been shown to significantly reduce the risk of sudden death from ventricular fibrillation. In the terminal stages of cardiac failure, a heart transplant is performed. Anticoagulant therapy is indicated for the prevention of thromboembolic stroke in patients with reduced left ventricular function and in those with atrial arrhythmia [2].

In this case report, we present a 47-year-old woman with cardiomyopathy in EDMD (with minor clinical expressions on the skeletal muscles) due to a mutation in the *LMNA* (lamin A) gene, who developed acute extensive ischemic stroke in the internal carotid artery. The patient was being prepared for ICD and permanent anticoagulant medication when acute stroke occurred.

Over 2 years ago, she suffered from a recurrent symptomatology from the right

parietal area of the brain with complete regression. She also suffered from the apicolateral acute transmural myocardial infarction. She was subsequently examined for rheumatic diseases, but these were not detected. Due to suspicion of the patient having a genetic origin of cardiomyopathy with arrhythmias, next generation sequencing was performed with the finding of a mutation in the *LMNA* gene and EDMD was determined. At that time, only a slight shortening of the m. triceps surae tendons, biceps brachii tendons, uncertain pelvic fixation, and subjective small fluctuating dizziness were evident in the neurological findings. The patient's family history included a cousin with cardiac disease in whom a pacemaker was implanted for arrhythmias followed shortly thereafter by a cardioverter. Her mother had a pacemaker and died during heart surgery due to a valve defect at the age of 62. Her brother died unexpectedly at the age of 35 while cycling, which was retrospectively assessed as the result of a cardiac problem.

Our patient has undergone two myocardial infarctions (non-ST elevation myocardial infarction; NSTEMI) and now has a permanent grade I AV block, Wenckebach-type intermittent AV block symptomatic, paroxysmal atrial fibrillation, and transient polymorphic ventricular tachycardia (documented by the implantable loop recorder [ILR]). According to the echocardiography, the patient had an ejection-fraction (EF) of 50%. MRI of the heart (September 2019) indicated a borderline size of the left ventricle, post-ischemic scar apically, and non-specific opacification of the middle layer of the inferoseptal myocardium basally. The causal mutation NM_170707.4(LMNA): c.999_1003dup (p.Arg335Profs*147) in the *LMNA* gene was found using a high-throughput sequencing analysis. This variant was not yet described in any publication or genetic databases. It was

The Editorial Board declares that the manuscript met the ICMJE "uniform requirements" for biomedical papers.

Redakční rada potvrzuje, že rukopis práce splnil ICMJE kritéria pro publikace zasílané do biomedicínských časopisů.

T. Prax¹, E. Ehler¹, L. Ungermann², I. Štětkářová³

¹ Department of Neurology, Faculty of Health Studies, University of Pardubice and Pardubice Regional Hospital, Czech Republic

² Radiodiagnostic Department of the Pardubice Regional Hospital, Czech Republic

³ Department of Neurology, Third Faculty of Medicine, Královské Vinohrady University Hospital, Prague, Czech Republic



Assoc. Prof. Edvard Ehler, MD, CSc., FEAN

Department of Neurology
Faculty of Health Studies
University of Pardubice
and Pardubice Regional Hospital
Kyjevská 44
532 03 Pardubice
Czech Republic
e-mail: edvard.ehler@nempk.cz

Accepted for review: 4. 11. 2020

Accepted for print: 1. 9. 2021

evaluated in VarSome software (Saphetor SA, Lausanne, Switzerland) [3], which further utilizes prediction programs and assesses variants according to the recommendation of the American Society for Genetics and Genomics. This variant is evaluated as a pathogenic variant within this program – it fulfilled criteria PVS1, PM1, PM2, and PP3. No other mutations were found.

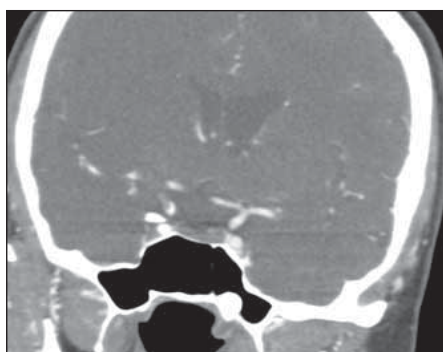


Fig. 1. Acute stage of ischemic stroke with the evidence of embologenic occlusion of the right internal carotid artery and of the M1 segment of the right middle cerebral artery.

Obr. 1. Akutní stadium ischemické CMP s průkazem emboligenního uzávěru vnitřní karotidy vpravo a úseku M1 a. cerebri media vpravo.

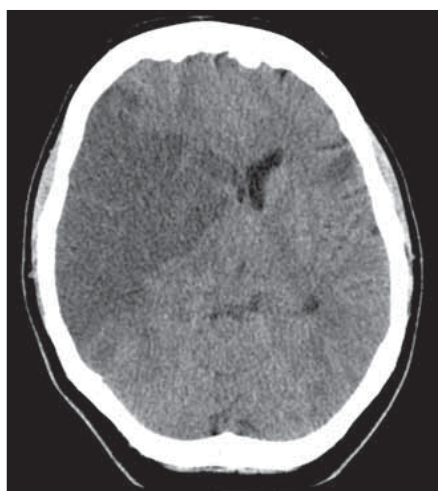


Fig. 2. CT of the brain indicating an expansively behaving ischemia in the right hemisphere.

Obr. 2. CT mozku svědčící pro expanzivně se chovající ischemii v pravé hemisféře.

During the night, about 3 hours after falling asleep, the patient experienced sudden left movement disorder (there were some dystonic movements on the left side observed and described by her husband) along with marked restlessness. The husband called the emergency service and the patient was admitted to the ICU of the stroke center. Stroke due to embolization to the middle cerebral artery (MCA) was diagnosed. Brain CT revealed, that penumbra was only affected to a small extent; ASPECTS (Alberta Stroke Program Early CT Scale) was 3 points. CTA of the cerebral arteries showed the occlusion of the terminal section of the internal carotid artery (ICA) on the right side (segment C7) with a transition to the M1/MCA segment (10 mm) (Fig. 1). The patient was consulted at a comprehensive stroke center that did not recommend intravenous thrombolysis or mechanical thrombectomy due to the presence of significant and extensive ischemic changes in the brain tissue. The finding was evaluated as an embologenic occlusion of the distal ICA, most likely of cardiac origin. On the next day, somnolence, dysarthria, dysphagia and left-sided hemiplegia were present. A follow-up CT of the brain was performed with the finding of expansively behaving ischemia in the right hemisphere

with a midline shift, with a subphalnic and descending transtentorial herniation (Fig. 2). The patient was transferred to neurosurgery, where an extensive right-sided craniectomy was performed. This was followed by a stay at the Anesthesiology and Resuscitation Department. After disconnection from complete mechanical ventilation (immediate postoperative), she was transferred to a neurological ICU. Here, the patient's environmental cooperation gradually improved, and passive and active rehabilitation was started. The neurological finding was dominated by significant psychological changes with fluctuations in cooperation, partial neglect syndrome, plegia of the left upper limb, and severe paresis of the left lower limb.

There was a significant reduction in cerebral edema on both the follow-up CT and the brain MRI two months after the onset of the disease. The development of post-ischemic changes in the brain tissue were evident.

EDMD has an incidence of 0.1–0.4 per 100,000 individuals and is characterized by the early development of contractures in the elbows, Achilles tendons, and neck extensors. Furthermore, the development of

muscle weakness and the development of atrophy in the humeroperoneal distribution is typical [2]. Cardiac involvement develops in more than 90% of patients and manifests itself in various types of conduction blocks and dilated cardiomyopathy.

Pacemaker implantation has not been shown to reduce the risk of arrhythmias and sudden death, and there have been repeated sudden deaths in patients with pacemaker implants [4]. Only the ICD has been shown to significantly improve the outcome of these patients. Due to atrial arrhythmias and cardiomyopathy with EF reduction (below 45% in EDMD), there is a high probability of intracardiac thrombus formation and subsequent embolizations, especially to the brain. Therefore, anticoagulant therapy is indicated in these patients.

Financial support

Supported by the PROGRES Q 35 Research projects of Charles University, Prague.

References

1. Karpatis G, Hilton-Jones D, Bushby K et al. Disorders of voluntary muscles. 8th ed. Cambridge, UK: Cambridge University Press 2010.
2. Faiella W, Bessoudo R. Cardiac manifestation in Emery-Dreifuss muscular dystrophy. CMAJ 2018; 190(3): E1414–E1417. doi: 10.1503/cmaj.180410.
3. Kopanos C, Tsiolkas V, Kouris A et al. VarSome: the human genomic variant search engine. Bioinformatics 2019; 35(11): 1978–1980. doi: 10.1093/bioinformatics/bty897.
4. Granger B, Gueneau L, Drouin-Garraud V et al. Modifier locus of the skeletal muscle involvement in Emery-Dreifuss muscular dystrophy. Hum Genet 2011; 129(2): 149–150. doi: 10.1007/s00439-010-0909-1.
5. Vohánka S, Vlčková E, Bednář J. Genetika nervosvalových onemocnění. Česk Slov Neurol N 2019; 82/115(2): 229–235. doi: 10.14735/amcsnn2019229.
6. Angelini C. LGMD. Identification, description and classification. Acta Myologica 2020; 39(4): 207–217. doi: 10.36185/2532-1900-024.
7. Bakay M, Wang Z, Melcon G et al. Nuclear envelope dystrophies show a transcriptional fingerprint suggesting disruption of Rb-MyoD pathways in muscle regeneration. Brain 2006; 129(Pt 4): 996–1013. doi: 10.1093/brain/awl023.
8. Arbustini E, Ri Torro A, Giuliani L et al. Cardiac phenotypes in hereditary muscle disorders. J Am Coll Cardiol 2018; 72(20): 2485–2506. doi: 10.1016/j.jacc.2018.08.2182.
9. Bednář J, Gaillyová R, Kadaňka Z et al. Nemoci kosterního svalstva. Praha: Triton 2001.
10. Mercuri E, Muntoni F. Muscular Dystrophies. Lancet 2013; 381(9869): 845–860. doi: 10.1016/S0140-6736(12)61897-2.

An extended version of the article is available at csnn.eu.