

# Middle ear myoclonus as a cause of objective tinnitus

## Myoklonus středního ucha jako příčina objektivního tinnitu

Dear Editors,

We present a case report of a patient with middle ear myoclonus (MEM) as a cause of objective tinnitus. We describe how we managed to make a diagnosis and how we continued with the clinical follow-up. In addition, we have performed a systematic review of the diagnosis and treatment in the relevant literature.

Objective tinnitus caused by MEM is a sporadic diagnosis, but it can have a disturbing impact on patients' lives.

Tinnitus is the perception of sound that does not originate from an external source. It is essential to distinguish between either subjective or objective and between pulsatile and non-pulsatile types of tinnitus. More common form is subjective tinnitus, which is perceived just by the patient and occurs apart from idiopathic reasons most frequently in patients with sensorineural hearing loss and presbycusis. While in objective tinnitus the sound is audible to both the patient and examiner. It is essential to describe the characteristics of the tinnitus. If it is rather continuous, it is most likely related to sensorineural hearing loss, otosclerosis or acoustic neuromas. The pulsatile kind of tinnitus is most likely to be produced by vascular abnormalities, high riding jugular bulb, arterial hypertension, glomus tumor or myoclonic disorders [1].

A 48-year-old male presented to a local otolaryngologist with 6 months of experiencing a crackling noise and intermittent aural blockage in his right ear. He had no personal history of chronic severe diseases and was not using any medication at that time. During the following year, he underwent several examinations such as complete ear-nose-throat (ENT) examination, audiometry, brain stem auditory evoked potentials (BAEP), CT of the brain, and X-ray of the cervical spine, but no specific pathology was found. He was given nasal corticosteroid spray, antihistamine drugs and antibiotics,

but there was no improvement of the patient's problem. The patient was sent to a referral speech-language-audiology department. The local clinician was the first who noticed an audible crackling noise in the patient's right ear. He raised the suspicion of Eustachian tube (ET) dysfunction, and thus catheterization of ET was performed and also nasal corticosteroid was recommended again. Nevertheless, the problems persisted and because the diagnosis of ET dysfunction seemed to be the most presumable cause, the patient underwent balloon Eustachian tuboplasty under general anesthesia. Anyway, there was no significant change in the patient's condition afterwards. Differential diagnosis was made considering disorder of masticatory muscles, and so the neurological examination and rehabilitation of the temporomandibular complex was recommended. Neurological findings, including MRI of the brain, were without pathological findings and subsequently, our oto-neurology department was consulted. As we examined the patient with an oto-microscope, we could see movement of the tympanic membrane in synchrony with the patient reporting sound in his ear. Hence, MEM came up. In long time-base tympanometry, we found a saw-tooth-like pattern (Fig. 1a) that supported the diagnosis of myoclonus of tensor tympani. Patient was given carbamazepine at a dose of 200 mg 3 times a day. Two months later (and four years since the first visit to a physician), the patient referred that his problems almost disappeared. In long time-base tympanometry, there was nearly a physiologic recording (Fig. 1b). The dosage of carbamazepine was then lowered to 200 mg twice a day. The patient stayed asymptomatic on that dose until the last visit (December 2021).

Myoclonus can be described as an abnormal involuntary repetitive muscular contraction. MEM involving tensor tympani (TT) and/or stapedius muscles (SM) is a rare

The Editorial Board declares that the manuscript met the ICMJE "uniform requirements" for biomedical papers.

Redakční rada potvrzuje, že rukopis práce splnil ICMJE kritéria pro publikace zasílané do biomedicínských časopisů.

**M. Bonaventurová, V. Bandúrová, Z. Čada, J. Plizák, Z. Balatková**

Department of Otorhinolaryngology and Head and Neck Surgery, 1<sup>st</sup> Faculty of Medicine, Charles University and Faculty Hospital Motol, Prague, Czech Republic



**Markéta Bonaventurová, MD**  
Department of Otorhinolaryngology and Head and Neck Surgery  
1<sup>st</sup> Faculty of Medicine,  
Charles University  
and Faculty Hospital Motol  
V Úvalu 84  
150 06 Prague  
Czech Republic  
e-mail:  
marketa.bonaventurova@fnmotol.cz

Accepted for review: 23. 6. 2022

Accepted for print: 21. 11. 2022

neuro-otological disorder and a well-recognized cause of objective tinnitus. The reported incidence of MEM is around 1.5% of newly diagnosed tinnitus patients [2].

Tensor tympani attaches from the cartilaginous part of the Eustachian tube and inserts onto the superior part of the malleus handle in the middle ear (Fig. 2). While contracting it stiffens the tympanic membrane, and so decreasing sound propagation via the ossicular chain. TT is associated with a startle reflex, which may be evoked by intense or abrupt sound or exaggerated by high-stress levels [3]. SM arises from the apex of the pyramidal and inserts into the posterior surface of

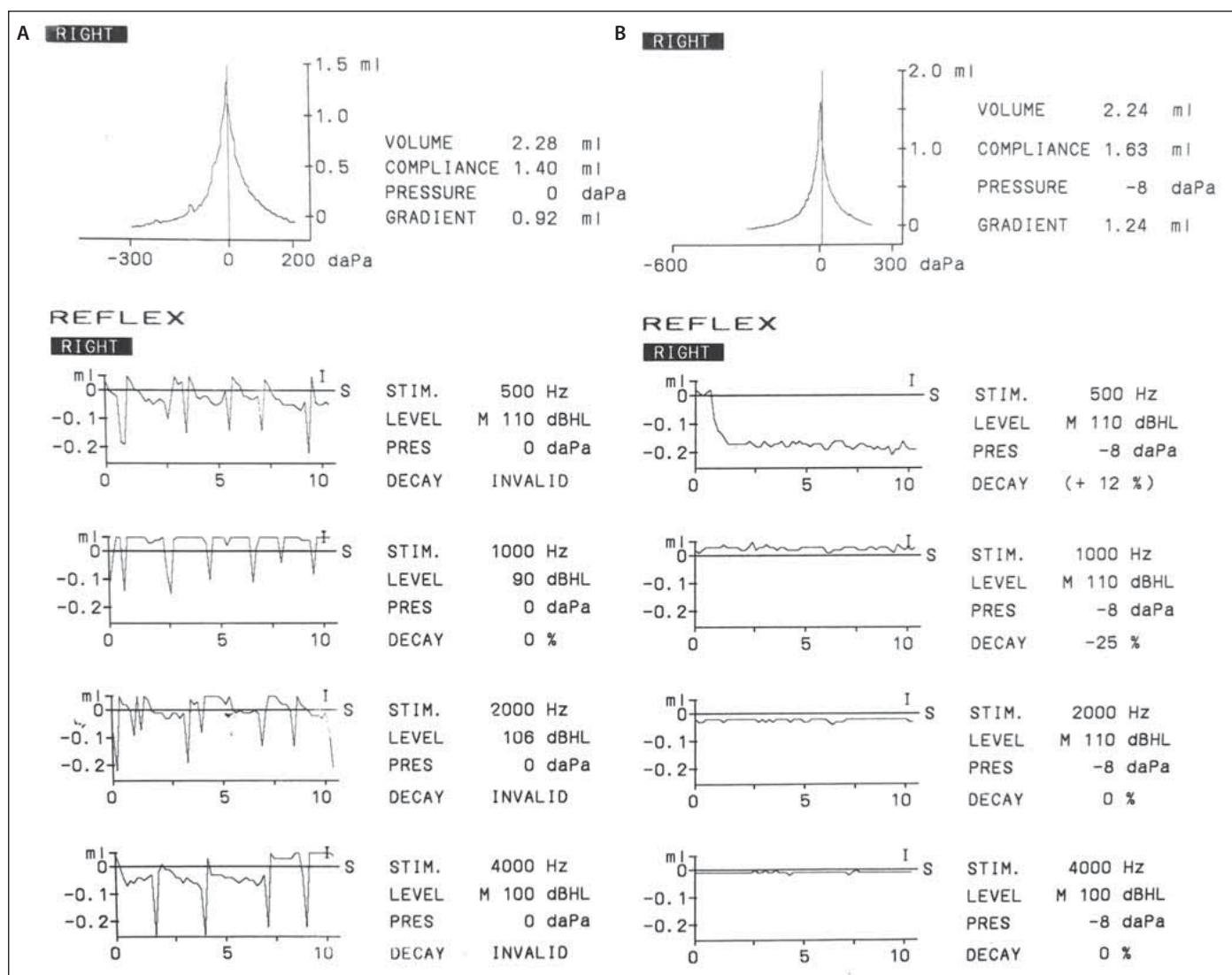


Fig. 1. Long-term tympanometry – (A) saw-tooth-like pattern; (B) nearly physiologic curve.

Obr. 1. Dlouhodobá tympanometrie – (A) pilovitý obrazec; (B) téměř fyziologická křivka.

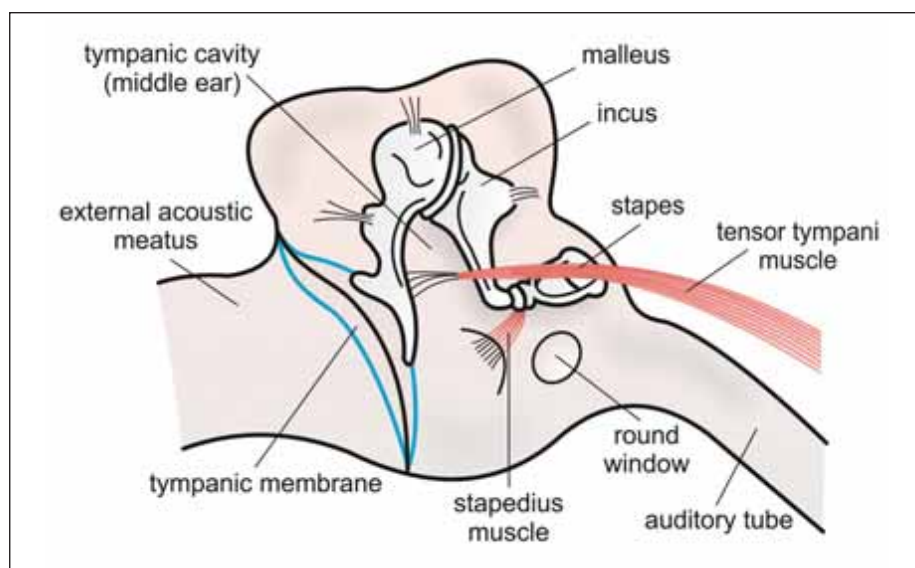


Fig. 2. Anatomical scheme of the middle ear cavity of the right ear.

Obr. 2. Anatomické schéma středoušní dutiny pravého ucha.

the neck of the stapes (Fig. 2). It protects the inner ear from high-intensity sound as well.

No unique pathophysiologic mechanism for this myogenic tinnitus has been discovered. However, there is a theory that MEM might be closely related to sound exposure in addition to stress [4].

The diagnosis can be achieved from the patient's history, otoscopic findings and long time-base tympanometry.

The main symptom is usually pulsatile tinnitus, which can be associated with hyperacusis, aural pain or blockage, mild vertigo/nausea, muffled hearing, and headache [5].

In otoscopic findings, there can be the observation of movements of the tympanic membrane synchronous with the tinnitus.

As far as the long time-base tympanometry is considered, a cogwheel or saw-

toothed pattern has been described in MEM by various authors [6].

In differential diagnosis, we consider (among the others) i) vascular abnormalities, ii) palatal myoclonus, iii) patulous eustachian tube and iv) temporomandibular joint pathology [7]. Vascular abnormalities must be ruled out using CTA or MRA. Recently, spontaneous otoacoustic emission (SOAE) has been identified as a helpful tool in assessing the degree of tinnitus in a patient with MEM [8].

From the latest research, 75 % of patients have benefitted from conservative therapy consisting of carbamazepine, clonazepam and baclofen [5]. Carbamazepine attenuates neuronal firing leading to decreased activity of the muscles innervated by them. It is recommended in doses as low as possible, but up to 400 mg a day [9]. Close monitoring of blood levels and its side effects should be done [8,9].

There are also other possibilities how to treat MEM, e.g., local therapy with botuli-

num toxin, behavioral therapy, and avoidance of trigger factors [10].

In case of unsatisfactory response to conservative treatment, sectioning of middle ear muscles can be performed. In most cases, patients underwent ipsilateral sectioning of both TT and SM. According to Kim et al up to 92% of the subjects exhibited complete symptomatic resolution of MEM during their follow-up period (up to 3 years) [2]. In our case, we achieved a good functional result with conservative treatment and there was no reason for surgical procedure.

## References

1. Fortune DS, Haynes DS, Hall JW. Tinnitus. Current evaluation and management. *Med Clin North Am* 1999; 83(1): 153–162. doi: 10.1016/s0025-7125(05)70094-8.
2. Kim DK, Park JM, Han JJ et al. Long-term effects of middle ear tendon resection on middle ear myoclonic tinnitus, hearing, and hyperacusis. *Audiol Neurotol* 2017; 22(6): 343–349. doi: 10.1159/000487260.
3. Maslovat D, Kennedy P, Forgaard C et al. The effects of prepulse inhibition timing on the startle reflex and

reaction time. *Neurosci Lett* 2012; 513(2): 243–247. doi: 10.1016/j.neulet.2012.02.052.

4. Park SN, Bae SC, Lee GH et al. Clinical characteristics and therapeutic response of objective tinnitus due to middle ear myoclonus: a large case series. *Laryngoscope* 2013; 123(10): 2516–2520. doi: 10.1002/lary.23854.

5. Westcott M, Sanchez T, Diges I et al. Tonic tensor tympani syndrome in tinnitus and hyperacusis patients: a multi-clinic prevalence study. *Noise Heal* 2013; 15(63): 117–128. doi: 10.4103/1463-1741.110295.

6. Golz A, Fradis M, Netzer A et al. Bilateral tinnitus due to middle-ear myoclonus. *Int Tinnitus J* 2003; 9(1): 52–55.

7. Bhimrao SK, Masterson L, Baguley D. Systematic review of management strategies for middle ear myoclonus. *Otolaryngol Head Neck Sur* 2012; 146(5): 698–706. doi: 10.1177/0194599811434504.

8. Salehi PP, Kasle D, Torabi SJ et al. The etiology, pathogenesis, and treatment of objective tinnitus: Unique case series and literature review. *Am J Otolaryngol* 2019; 40(4): 594–597. doi: 10.1016/j.amjoto.2019.03.017.

9. Sunwoo W, Jeon YJ, Bae YJ et al. Typewriter tinnitus revisited: the typical symptoms and the initial response to carbamazepine are the most reliable diagnostic clues. *Sci Reports* 2017; 7(1): 10615. doi: 10.1038/s41598-017-10798-w.

10. Wong WK, Lee MFH. Middle ear myoclonus: Systematic review of results and complications for various treatment approaches. *Am J Otolaryngol* 2022; 43(1): 103228. doi: 10.1016/j.amjoto.2021.103228.

# Vzdělávací internetové stránky o demencích

Vážené a milé kolegyně a kolegové,

v roce 2021 skončil 3letý evropský grant Innovation for Dementia in the Danube Region (INDEED), jehož účelem bylo vyvinout elektronickou platformu ke vzdělávání o demencích. Je určena pro organizátory aktivit, instituce a firmy zabývající se kognitivními poruchami a demencemi. Podařilo se vytvořit rozsáhlé internetové stránky. Je možné je používat jakkoli zdarma po registraci, takže např. pro různé výukové účely.

Existují v 5 jazycích vč. slovenštiny a angličtiny. Budeme rádi, když je budete využívat nebo poskytovat dalším nebo informovat o nich kohokoli, pro koho by mohly mít užitek.

**<https://indeed-project.eu/>**

**prof. MUDr. Aleš Bartoš, PhD**

*spoluřešitel evropského grantu Innovation for Dementia in the Danube Region (INDEED)*

*Fakultní nemocnice Královské Vinohrady, Univerzita Karlova 3. LF, Praha*

*Národní ústav duševního zdraví, Klecany*

*e-mail: ales.bartos@nudz.cz*