

Trigeminal Nerve Asymmetry in Classic Trigeminal Neuralgia – Evaluation by Magnetic Resonance Imaging

Asymetrie trojklaného nervu u klasické neuralgie trigeminu – zhodnocení pomocí magnetické rezonance

Abstract

Aim: Classic trigeminal neuralgia (CTN) is characterized by episodic neuropathic facial pain that, with exception of neurovascular conflict (NVC), was not attributed to any underlying disorder in our sample. Using magnetic resonance imaging, we evaluated volumes of affected and non-affected nerves and presence and type of NVC in a large group of CTN subjects prior to gamma knife treatment. **Design:** Correlation between affected nerve volume and NVC, clinical data and demographic characteristics (duration of pain, age) were explored in 45 subjects diagnosed with CTN. **Results:** NVC was detected in 69% of affected nerves, 51% of non-affected nerves, and in 42% of subjects bilaterally. Lower trigeminal nerve volume was detected on the affected side ($p < 0.001$), however, no correlation between affected nerve volume and the presence and type NVC or demographic data was detected. **Conclusion:** Our results suggest that NVC may trigger CTN in susceptible subjects but is not a reliable disease marker. Lower trigeminal nerve volume appears to manifest independently of NVC, and may represent nerve asymmetry rather than atrophy.

Souhrn

Cíl: Klasická neuralgie trigeminu (CTN) je charakterizována epizodickou ostrou neuropatickou obličejovou bolestí a s výjimkou přítomnosti neurovaskulárního konfliktu (NVC) nebyla v našem souboru podmíněna jinou známou abnormitou či patologií. V poslední době je diskutována atrofie trigeminu na straně bolesti. Naším cílem bylo ověřit tyto nálezy a vztáhnout je k dalším klinickým datům. **Soubor a metodika:** Pomocí magnetické rezonance (MR) jsme změřili objemy trojklaného nervu na bolestí postižené a nepostižené straně a vyhodnotili výskyt a typ NVC u 45 nemocných s CTN. Následně jsme provedli korelace mezi objemy postiženého nervu, NVC, klinickými a demografickými daty (trvání nemoci, věk nemocného). **Výsledky:** NVC jsme zjistili u 69 % postižených nervů, 51 % nepostižených nervů a u 42 % nemocných oboustranně. Signifikantně snížený objem trojklaného nervu byl zjištěn na bolestí postižené straně ($p < 0,001$). Žádné korelace jsme nezaznamenali mezi objemem postiženého nervu, přítomností a typem NVC ani mezi klinickými a demografickými daty. **Závěr:** Naše výsledky naznačují, že NVC může být sice spouštěvým mechanismem CTN u vnímavých subjektů, ale není spolehlivým ukazatelem nemoci. Snížený objem trojklaného nervu se objevuje nezávisle na NVC a odráží spíše predisponující asymetrii trigeminu než vzniklou atrofii.

This work was supported by Grant IGA NT11328-4/2010; MH CZ – DRO (Nemocnice Na Homolce – NNH, 00023884), Research Project Charles University in Prague PRVOUK P34 and Project FNUSA-ICRC (No.CZ.1.05/1.1.00/02.0123).

The authors declare they have no potential conflicts of interest concerning drugs, products, or services used in the study. Autoři deklarují, že v souvislosti s předmětem studie nemají žádné komerční zájmy. The Editorial Board declares that the manuscript met the ICMJE “uniform requirements” for biomedical papers. Redakční rada potvrzuje, že rukopis práce splnil ICMJE kritéria pro publikace zaslané do biomedicínských časopisů.

D. Urgosik¹, A. M. Rulseh², J. Keller^{2,3}, V. Svehlik⁴, J. M. V. N. Pingle², D. Horinek^{4,5}

¹ Department of Stereotactic and Radiation Neurosurgery, Na Homolce Hospital, Prague

² Department of Radiology, Na Homolce Hospital, Prague

³ Department of Neurology, 3rd Faculty of Medicine, Charles University in Prague

⁴ International Clinical Research Center, St. Anne's University Hospital in Brno

⁵ Department of Neurosurgery, Masaryk Hospital, J. E. Purkyně University, Usti nad Labem



Dusan Urgosik, MD, PhD
Na Homolce Hospital
Roentgenova 2
150 30 Prague
e-mail: urgosik@gmail.com

Accepted to review: 27. 5. 2014
Accepted to print: 26. 6. 2014

<http://dx.doi.org/10.14735/amcsnn2014582>

Klíčová slova

classic trigeminal neuralgia – neuralgia – neuropathic pain – magnetic resonance imaging – volumetry

Key words

klasická neuralgie trigeminu – neuropatická bolest – magnetická rezonance – volumetrie

Introduction

Classic trigeminal neuralgia (CTN) is one of the most commonly treated pain syndromes, although the cause of the disease is still under debate. Various authors have tried to explain the etiology of trigeminal pain by different anatomical abnormalities, including trigeminal nerve volume changes. It has been shown that the volume of affected nerves in CTN is lower than non-affected nerves [1–3]. The lower volume of affected nerves is often considered to reflect atrophy [1–3], the gross manifestation of demyelination and axonal derangement, following neurovascular conflict (NVC; the presence of either neurovascular contact or compression) or other insult. However, no effort to correlate trigeminal nerve volume with other imaging or clinical data has been undertaken to date. In the present study, we evaluated volumes of affected and non-affected nerves in a large group of CTN subjects refractory to pharmacological treatment referred to our institution for gamma knife treatment. We further evaluated subjects for the presence of NVC, classifying the type of contact when present. Our aim was to determine whether trigeminal nerve volume correlates with the presence and type of NVC,

as well as clinical parameters such as age and disease duration.

Groups and methods

Subjects

A total of 45 subjects diagnosed with classic trigeminal neuralgia were included in the study (24 male, 21 female; age 54–86 years, mean 69.2 ± 10 SD; disease duration 3–180 months, mean 64.6 ± 50 SD months). All subjects suffered from classical trigeminal neuralgia with a spontaneous onset of episodic facial pain. No subjects had undergone any type of neurosurgical procedure (radio-frequency rhizotomy, glycerol rhizotomy, balloon microcompression, microvascular decompression or peripheral neurectomy, radiosurgery) prior to evaluation. The study was approved by the ethics committee of Na Homolce Hospital in Prague, and all subjects provided written informed consent.

MR imaging protocol

All images were acquired after administration of an IV contrast agent prior to GKS treatment. In addition to standard imaging sequences collected for clinical purposes, 3D constructive interference in steady state (CISS) images were obtained

for volumetric evaluation. Subjects were scanned at 1.5 T on a Siemens Avanto (Erlangen, Germany) scanner (3D-CISS; slice thickness 0.9 mm, in-plane resolution 0.45×0.45 mm, TE 2.47 ms, TR 5.54 ms, NEX = 2).

Post-processing and assessment

Volumetry was evaluated in consistent grayscale using the auto-level mode in Leksell GammaPlan v.10.1 (Elekta Instruments, Stockholm, Sweden) by manually tracing the contours of trigeminal nerves between the brain stem and Meckel's cave (Fig. 1). One investigator with 18 years of experience in trigeminal nerve imaging performed all measurements blinded to the side of neuralgia; measurements were repeated after six months.

CISS and T1-weighted post-contrast MR images were used to detect and classify NVC based on localization and relation of the vessel to the nerve [4]. The presence or absence of NVC was evaluated and localization of NVC was recorded as root-entry zone (REZ, defined as the segment of the trigeminal nerve up to 2–4 mm from the brainstem) or non-root-entry zone. The relation of the vessel to the nerve was further classified as u-shaped contact, parallel contact, crossing contact or nerve dislocation [4].

Statistical analyses

Region of interest (ROI) data were processed in R (R Development Core Team [5]). A paired t-test was used to detect differences in trigeminal nerve volume on affected and non-affected sides, and a two-sample t-test was used to explore volume differences in affected nerves related to the number of branches affected (1 vs. 2), NVC type (REZ vs. non-REZ), and the presence of a trigger zone. A one-way analysis of variance (ANOVA) test was used to examine potential volume differences in subgroups of affected nerves classified according to type of NVC. A linear model was applied to investigate correlation between affected nerve volume and disease duration and patient age. Intra-rater variability was assessed using the single score intra-class correlation. The Bonferroni correction for multiple comparisons was applied to maintain an alpha of 0.05. All significant p-values reported are corrected.

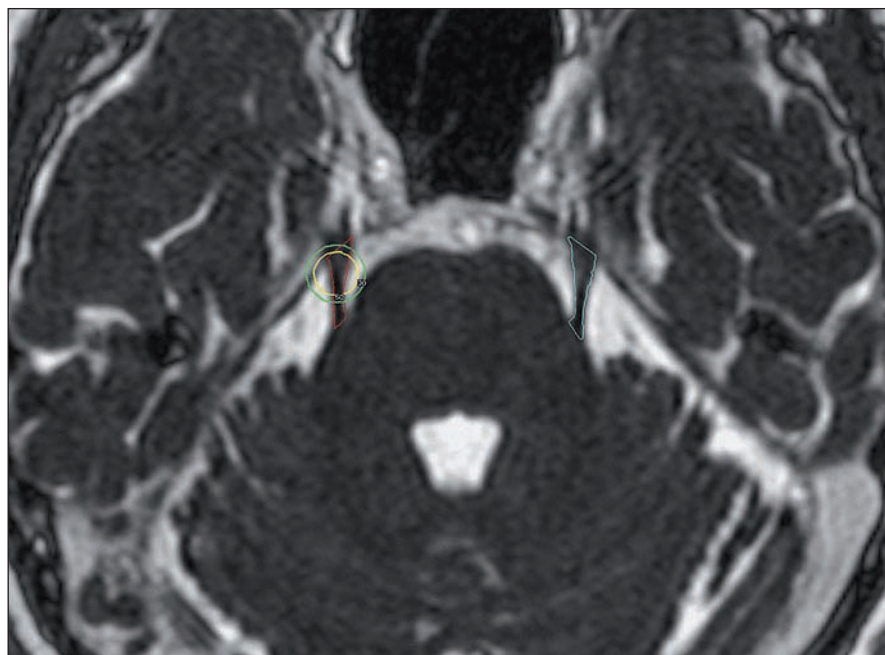
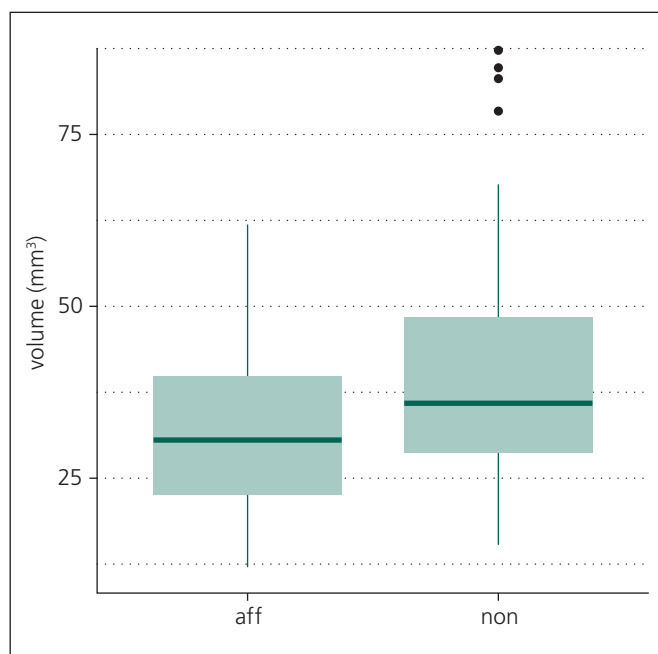


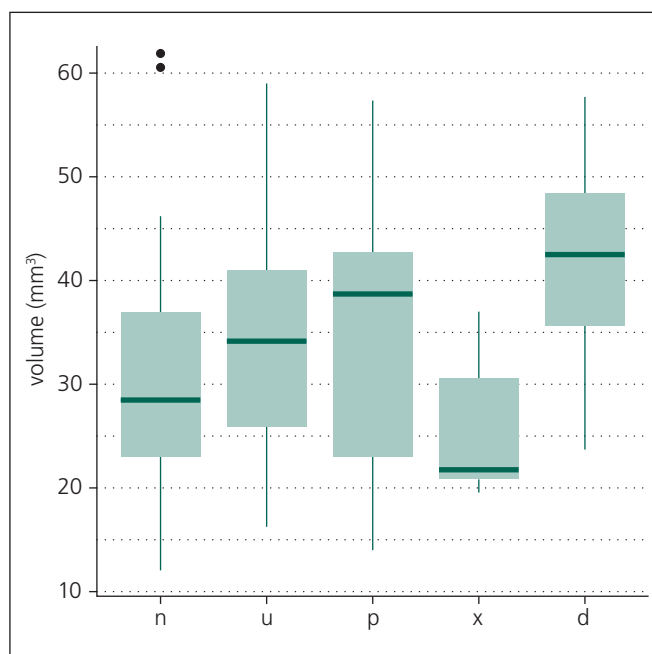
Fig. 1. 3D-CISS MR image used for volumetric evaluation. ROIs placed on the bilateral trigeminal nerves, circles placed on the side of neuralgia represent planned 50% and 30% isodoses delivered by gamma knife irradiation.

CISS – constructive interference in steady state, ROI – region of interest.



Graph 1. Tukey boxplot illustrating lower group-wise trigeminal nerve volume in affected nerves versus non-affected nerves in CTN ($p < 0.001$).

CTN – classic trigeminal neuralgia, aff – affected side, non – non-affected side.



Graph 2. Tukey boxplot illustrating no group-wise differences in affected volumes in CTN by type of NVC ($F(4,40) = 1.04$, $p = 0.40$). NVC was classified as n for none, u for u-shaped contact, p for parallel contact, x for crossing contact and d for dislocation.

CTN – classic trigeminal neuralgia, NVC – neurovascular conflict.

Results

The distribution of pain in trigeminal nerve branches was as follows: one branch in 22 subjects (49%) and two branches in 23 subjects (51%; in 12 subjects branches I and II, in 11 subjects branches II and III). Forty of 45 patients (89%) had a trigger zone (TZ). NVC was detected in 31 of 45 affected trigeminal nerves (69%), including 13 instances of u-shaped contact, seven crossing contact, seven parallel contact and four instances of dislocation. NVC within the REZ was observed in 11 (24%) affected nerves. In 23 (51%) subjects, NVC was detected on the non-affected side, including seven (16%) instances of NVC within the REZ. NVC was detected bilaterally in 19 (42%) subjects.

Volumetric results

Intra-rater agreement between two separate measurements was excellent ($ICC = 0.98$) and the mean of these measurements was used in further tests. We detected lower group-wise trigeminal nerve volume in affected nerves vs. non-affected nerves ($p < 0.001$, affected mean $33.3 \text{ mm}^3 \pm 13 \text{ SD}$, non-affected

mean $40.8 \text{ mm}^3 \pm 18 \text{ SD}$; Graph 1). No dependence on disease duration ($p = 0.32$) or patient age ($p = 0.54$) in affected nerves was detected. Additionally, no differences in affected volumes were detected either between the various types of NVC ($F(4,40) = 1.04$, $p = 0.40$; Graph 2) or between groups with different numbers of affected branches (1 vs. 2, $p = 0.27$).

Discussion

In the present study, we evaluated clinical and MR imaging data in a large group of patients diagnosed with CTN that were referred to our institution for GKS treatment. All patients presented with one or two branches affected, in roughly equal proportions, while the majority of patients had a trigger zone. MR imaging detected NVC in 69% of affected nerves, including 24% within the REZ. NVC was also detected in 51% of subjects on the non-affected side and in 42% bilaterally. This is in agreement with previous studies [2,6–8], suggesting that NVC may trigger CTN in susceptible subjects but is not a reliable disease marker.

When evaluating trigeminal nerve volume on MR images, we detected lower

trigeminal nerve volume on the affected side in comparison to the non-affected side (Graph 1). Lower trigeminal nerve volume in CTN has been previously reported and posited to represent atrophy due to NVC [1–3]. However, previous studies have not explored potential correlation between nerve volume and other covariates such as the presence and type of NVC, disease duration or patient age. Although, in agreement with previous reports, we detected lower nerve volume on the affected side [1–3], we did not observe any correlation with other covariates in affected nerves. No differences in affected nerve volumes were detected in NVC positive and negative subjects, nor were any volume differences detected by number of branches affected, NVC classification (Graph 2) or the presence or absence of REZ contact. Additionally, no correlation was detected between affected trigeminal nerve volume and patient age or disease duration.

Histopathological studies in CTN have reported central demyelination [9–11] as well as axonal changes [10] in affected nerves. It is currently thought that CTN arises in the presence of NVC due

to pulsatile compression of demyelinated fibers, resulting in aberrant, ephaptically transmitted impulses [12]. Successful treatment of CTN with microsurgical decompression [13] strongly supports involvement of NVC in the pathogenesis of CTN. However, with regard to trigeminal nerve volume, our findings suggest that lower volume of affected nerves occurs independently of NVC. Lower trigeminal nerve volume is likely present prior to clinical onset and predisposes an individual to the development of CTN, rather than occurring as a consequence of NVC. This hypothesis is supported by the detection of NVC in non-affected nerves in the present study as well as in previous studies [2,6–8].

In conclusion, we observed NCV in 69% of affected nerves and 51% of non-affected nerves in CTN, suggesting that NVC may trigger CTN in susceptible subjects but is not a reliable disease marker. No dependence of affected trigeminal nerve volume on demographic factors was observed. Additionally, no volume

dependence on the presence or type of NVC was detected. Therefore, we recommend that the term asymmetry, rather than atrophy, is used to describe lower volume of affected trigeminal nerves in CTN.

References

1. Erbay S, Bhadelia R, O'Callaghan M, Gupta P, Riesenburger R, Krackov W et al. Nerve atrophy in severe trigeminal neuralgia: noninvasive confirmation at MR imaging – initial experience. *Radiology* 2006; 238(2): 689–692.
2. Kress B, Schindler M, Rasche D, Hähnel S, Tronnier V, Sartor K. Trigeminal neuralgia: how often are trigeminal nerve-vessel contacts found by MRI in normal volunteers. *Rofo* 2006; 178(3): 313–315.
3. Ha SM, Kim SH, Yoo EH, Han IB, Shin DA, Cho KG et al. Patients with idiopathic trigeminal neuralgia have a sharper-than-normal trigeminal-pontine angle and trigeminal nerve atrophy. *Acta Neurochir (Wien)* 2012; 154(9): 1627–1633. doi: 10.1007/s00701-012-1327-z.
4. Adamczyk M, Bulski T, Sowiska J, Furmanek A, Bekiesiska-Figatowska M. Trigeminal nerve-artery contact in people without trigeminal neuralgia – MR study. *Med Sci Monit* 2007; 13 (Suppl 1): 38–43.
5. R Development Core Team. *A Language and Environment for Statistical Computing*. Vienna: R Foundation for Statistical Computing 2008.
6. Haines SJ, Jannetta PJ, Zorub DS. Microvascular relations of the trigeminal nerve. An anatomical study

with clinical correlation. *J Neurosurg* 1980; 52(3): 381–386.

7. Magnaldi S, Cecconi P, Skrap M, Ricci C, Cova MA, Pozzi-Mucelli RS. Magnetic resonance in trigeminal neuralgia. *Radiol Med* 1992; 83(6):700–705.

8. Peker S, Diner A, Necmettin Pamir M. Vascular compression of the trigeminal nerve is a frequent finding in asymptomatic individuals: 3-T MR imaging of 200 trigeminal nerves using 3D CISS sequences. *Acta Neurochir (Wien)* 2009; 151(9): 1081–1088. doi: 10.1007/s00701-009-0329-y.

9. Kunc Z, Fuchsová M, Novák M. Excision of the spinal trigeminal tract. Electron microscopy. *Acta Neurochir (Wien)* 1978; 41(1–3): 233–241.

10. Love S, Hilton DA, Coakham HB. Central demyelination of the Vth nerve root in trigeminal neuralgia associated with vascular compression. *Brain Pathology* 1998; 8(1): 1–11.

11. Marinković S, Gibo H, Todorović V, Antić B, Kovacević D, Milisavljević M et al. Ultrastructure and immunohistochemistry of the trigeminal peripheral myelinated axons in patients with neuralgia. *Clin Neurol Neurosurg* 2009; 111(10): 795–800. doi: 10.1016/j.clineuro.2009.07.020.

12. Love S, Coakham HB. Trigeminal neuralgia: pathology and pathogenesis. *Brain* 2001; 124(12): 2347–2360.

13. Sindou M, Leston J, Decullier E, Chapuis F. Microvascular decompression for primary trigeminal neuralgia: long-term effectiveness and prognostic factors in a series of 362 consecutive patients with clear-cut neurovascular conflicts who underwent pure decompression. *J Neurosurg* 2007; 107(6): 1144–1153.

Kongresový den BUDĚJOVICE KAZUISTICKÉ

25. září 2014 v prostorách Zdravotně sociální fakulty
Jihočeské Univerzity v Českých Budějovicích

Setkání lékařů, sester a dalších zdravotnických profesionálů, kteří budou **formou kazuistik** prezentovat to nejzajímavější a nejpoučňivější, co se za poslední dobu na jejich pracovištích událo, pořádá Nemocnice České Budějovice a.s. a Zdravotně sociální fakulta Jihočeské Univerzity.

Své práce mohli přihlásit lékaři, sestry a další zdravotničtí profesionálové **do 35 let**.

Účastníci se mohou těšit na 60 lékařských a 20 sesterských kazuistik.

BUDĚJOVICE KAZUISTICKÉ jsou rozděleny do **dvou lékařských sekcí** (sekce chirurgických oborů a sekce interních oborů), **dvou sesterských sekcí** (opět chirurgická a interní sekce), studentská sekce určená pro studenty nejen ZSF JČU. Účast na konferenci je **zdarma**.

Rozšířené abstrakty všech přijatých kazuistik budou uveřejněny ve sborníku, vybrané kazuistiky pak budou otištěny v odborných lékařských časopisech **nakladatelství Ambit Media**.