

Invasive primary intracerebral infections in women caused by *Streptococcus intermedius* manifesting as purulent meningitis and intracerebral abscess

Invazivní primárně intracerebrální infekce u žen způsobené *Streptococcus intermedius* a manifestující se jako purulentní meningitida a intracerebrální absces

Dear Editor,

Brain abscess is characterised as a purulent infection of the brain with cerebritis leading to central necrosis that can be caused by a broad spectrum of infectious agents. Here we report two cases of invasive infections of *Streptococcus intermedius* in women with no identified primary focus other than the intracerebral manifestation.

Patient 1 is a 55-years-old woman treated chronically for depression. She was admitted to the local department of neurology for fatigue and sleeplessness and showed slowed psychomotor reactions, dysarthria, lesion of the right VIIth nerve and positive meningeal signs. Blood tests showed an elevation of C-reactive protein (CRP) (141 mmol/L) and leucocytosis ($14.9 \times 10^9/L$). A native CT scan showed vasogenic edema in the left frontal lobe ($50 \times 40 \times 55$ mm) with a centrally localized focus ($21 \times 20 \times 20$ mm). IV anti-edematous therapy was started together with IV amoxicillin/clavulanate. The next day, a contrast enhanced CT scan identified a circular tumor-like focus in the left frontal lobe with surrounding edema. The suspected diagnosis of glioblastoma was made and the patient was transferred to the Department of Neurology of the University Hospital. There, the cerebrospinal fluid (CSF) was examined with results supporting a diagnosis of a brain abscess (Tab. 1). The anti-edematous therapy was continued, but the antibiotic therapy was changed to a combination of ceftriaxone + metronidazole + vancomycin.

After a non-invasive approach was indicated, the patient was transferred to the Department of Infectious Diseases (DID). Symptomatically she was afebrile, somnolent, able to follow only simple command, with positive meningeal signs, lesion of the right VIIth nerve and Glasgow Coma Scale (GCS) of 12. CSF showed high inflammatory markers, but the cultivation was negative. CT scan of the brain on day 4 at the DID showed an abscess in the left frontal lobe with communication to the ventricles, ventriculitis and surrounding edema. The panbacterial DNA test identified *Streptococcus intermedius*, which was confirmed later on by anaerobic CSF cultivation. The cultivation from all other biological samples was negative and additional examinations identified no other potential focus of the infection. After 4 days of therapy, the status of the patient improved. Despite some dysarthria, the patient started to communicate, neurological symptoms and the inflammatory markers improved and the CSF laboratory markers also showed improvement (Tab. 1).

On day 6 at DID, the patient continued to improve. She suffered only from minor dysarthria, inflammatory markers returned to normal (leucocytes $7.7 \times 10^9/L$, CRP 5.5 mmol/L) and CSF laboratory results further improved (Tab. 1). On day 10, the MRI showed the brain abscess and ventriculitis. In addition, however, a pathological content of the lateral ventricle appeared as small abscesses (Fig. 1A). Based on these findings, a drainage

The authors declare they have no potential conflicts of interest concerning drugs, products, or services used in the study.

Autoři deklarují, že v souvislosti s předmětem studie nemají žádné komerční zájmy.

The Editorial Board declares that the manuscript met the ICMJE "uniform requirements" for biomedical papers.

Redakční rada potvrzuje, že rukopis práce splnil ICMJE kritéria pro publikace zasílané do biomedicínských časopisů.

**P. Prášil¹, V. Boštíková²,
Z. Hermannová¹, S. Plíšek¹, P. Boštík^{1,2}**

¹ Department of Infectious Diseases, Charles University, Faculty of Medicine and University Hospital, Hradec Králové, Czech Republic

² Faculty of Military Health Sciences, University of Defence, Hradec Králové, Czech Republic



prof. MUDr. Pavel Boštík, Ph.D.
Department of Infectious Diseases
Charles University Faculty
of Medicine and University Hospital
Šimkova 870
500 03 Hradec Králové,
Czech Republic
e-mail: bostikp@lfhk.cuni.cz

Accepted for review: 6. 9. 2017

Accepted for print: 1. 3. 2018

of the abscess was initiated with confirmatory bacteriological findings from the abscess material. At this point, the sensitivity of the identified agent was established as having minimal inhibitory concentrations (MIC) for penicillin (MIC = 0.008 mg/L). Therefore, the antibiotic combination was terminated and a high dose of crystalline penicillin was administered instead (48 MIU/day). The ventricular drainage continued for 4 days and then was terminated. The MRI performed on

Tab. 1. Laboratory findings in cerebrospinal fluid of both patients on the days of hospitalization indicated in the left column.

Cerebrospinal fluid	Neutrophils (1/mm ³)	Lymphocytes (1/mm ³)	Glucose (mmol/L)	Protein (g/L)	Cl ⁻ (mmol/L)	Lactate (mmol/L)
Patient 1						
day 1	> 10,000	0	0.26	1.9	119	13.5
day 4	1,298	176	2.46	0.6	112	7.8
day 6	528	80	2.66	0.7	121	5.4
Patient 2						
day 1	6,912	2,304	0.66	2.3	114	2.15

day 32 showed further regression of brain edema, a decrease of abscess size and no CSF circulation pathology. Antibiotic therapy was

terminated on day 62, when the MRI showed a disappearance of the liquid in the site of the former abscess and signs of scarring in

the surrounding tissue (Fig. 1B). The patient finally recovered with no residual finding.

Patient 2 is a 43-year-old woman. Her first symptoms started 3 days before as fever and headaches leading to meningeal signs. Her DID entry exam showed fever, hypohydration, positivity of upper meningeal signs, but she was fully conscious and neurologically showing only transient problems with dystaxia of her left upper limb. The blood laboratory tests showed high CRP (272.7 mmol/L) and fibrinogen (6.1 mmol/L) values as well as leucocytosis ($16.33 \times 10^9/L$). CSF examination supported a diagnosis of bacterial meningitis (Tab. 1), but microscopy and agglutination tests were negative. MRI showed no focal infection of the brain. PCR for the panel of bacteria was negative. The patient was re-

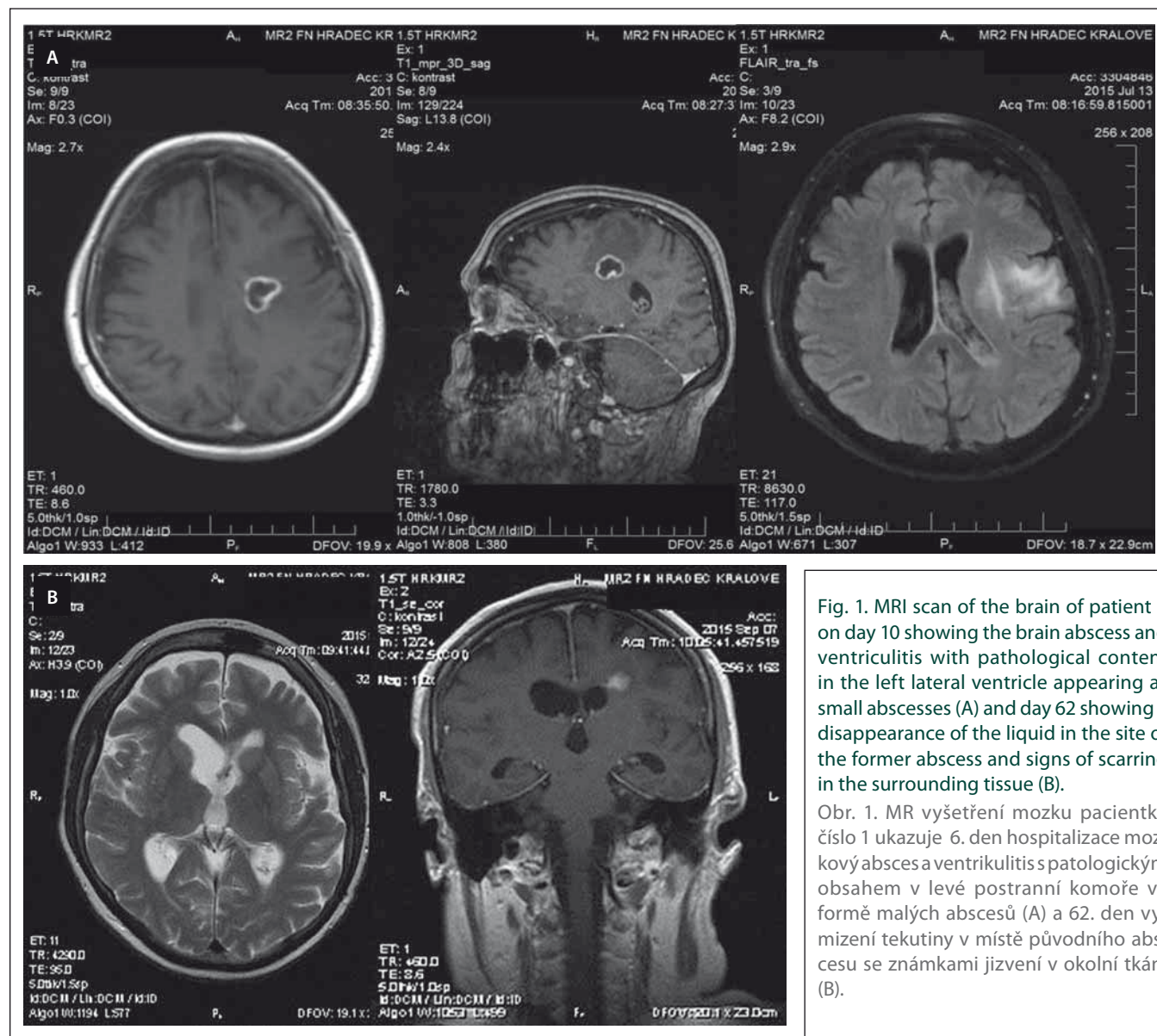


Fig. 1. MRI scan of the brain of patient 1 on day 10 showing the brain abscess and ventriculitis with pathological content in the left lateral ventricle appearing as small abscesses (A) and day 62 showing a disappearance of the liquid in the site of the former abscess and signs of scarring in the surrounding tissue (B).

Obr. 1. MR vyšetření mozku pacientky číslo 1 ukazuje 6. den hospitalizace mozkový absces a ventriculitis s patologickým obsahem v levé postranní komoře ve formě malých abscesů (A) a 62. den vymizení tekutiny v místě původního abscesu se známkami jizvení v okolní tkáni (B).

hydrated, therapy with ceftriaxon (4 g/day) was started and, after negative results for *Listeria spp*, ampicillin and corticosteroids were added. Simultaneously, a thorough exam failed to identify a potential focus of the infection. On day 3 after admission, *Streptococcus intermedius* was identified by both cultivation and sequencing from CSF with a good sensitivity to penicillin (MIC = 0.018 mg/L). Antibiotic therapy was thus adjusted to a high dose of crystalline penicillin potassium salt (48 MIU/day), which led to the normalization of the levels of inflammatory markers. The complete normalization of the CSF was, however, achieved after 18 days post-admission. The patient was released 21 days after the beginning of hospitalization showing no residual symptoms.

Both cases showed invasive infections caused by *Streptococcus intermedius*, which are relatively rare, but pose a relatively high pathogenic potential. Previous studies showed patients with diseases caused by this bacteria indicating a propensity of this bacteria to the formation of abscesses [1–4]. Our case report 2, however, showed a patient with an invasive infection without abscess formation, which is very rare. In both presented cases, no primary focus was found elsewhere, despite

of the extensive searching [5]. This suggests a hematogenous spread of *Streptococcus intermedius*. The diagnosis of *Streptococcus intermedius* is critical since the growth conditions are anaerobic. When examining CSF, tests may not always include bacteria from this group. For the molecular analysis, the next step then is a panbacterial DNA test with subsequent sequencing (16s rRNA) [1,2,6,7].

Antibiotic therapy before the identification of the pathogen needs to cover a broader spectrum and is achieved by a combination therapy, which includes third generation cephalosporins with metronidazol and, potentially, vancomycin [8]. A targeted therapy shall then be introduced after the causative agent has been identified and sensitivity has been tested. Penicillin is the antibiotic of choice in infections caused by *Streptococcus intermedius* [6–9]. In the case of *Streptococcus intermedius* resistance to penicillin, cefotaxim, teicoplanin or vancomycin are available [9,10].

References

1. Noguchi S, Yatera K, Kawanami T et al. The clinical features of respiratory infections caused by the *Streptococcus anginosus* group. *BMC Pulm Med* 2015; 15: 133. doi: 10.1186/s12890-015-0128-6.
2. Tran MP, Caldwell-McMillan M, Khalife W et al. *Streptococcus intermedius* causing infective endocarditis and abscesses: a report of three cases and review of the literature. *BMC Infect Dis* 2008; 8: 154. doi: 10.1186/1471-2334-8-154.
3. Jouhadi Z, Sadiki H, Hafid I et al. [*Streptococcus intermedius*: a rare cause of brain abscess in children]. *Arch Pediatr* 2013; 20(3): 282–285. doi: 10.1016/j.arcped.2013.01.002.
4. Saijo M, Muroto K, Hirano Y et al. [A patient with *Streptococcus intermedius* brain abscess treated with high dose penicillin G--susceptibility of the isolate to penicillin G and the concentration of penicillin G in cerebrospinal fluid]. *Kansenshogaku Zasshi* 1998; 72(4): 414–417.
5. Moazzam AA, Rajagopal SM, Sedghizadeh PP et al. Intracranial bacterial infections of oral origin. *J Clin Neurosci* 2015; 22(5): 800–806. doi: 10.1016/j.jocn.2014.11.015.
6. Ohara N, Asai K, Ohkusu K et al. [A case of culture-negative brain abscess caused by *Streptococcus intermedius* infection diagnosed by broad-range PCR of 16S ribosomal RNA]. *Brain Nerve* 2013; 65(10): 1199–1203.
7. Saito N, Hida A, Koide Y et al. Culture-negative brain abscess with *Streptococcus intermedius* infection with diagnosis established by direct nucleotide sequence analysis of the 16s ribosomal RNA gene. *Internal med* 2012; 51(2): 211–216.
8. Gilbert DN, Moellering RC, Eliopoulos GM et al. Brain abscess. In: *The Sanford guide to antimicrobial therapy*. 41st ed. Sanford: Antimicrobial Therapy, Inc. 2011.
9. Rozkiewicz D, Daniluk T, Sciepuk M et al. Prevalence rate and antibiotic susceptibility of oral viridans group streptococci (VGS) in healthy children population. *Adv Med Sci* 2006; 51 (Suppl 1): 191–195.
10. Jacobs JA, Stobberingh EE. In-vitro antimicrobial susceptibility of the „*Streptococcus milleri*” group (*Streptococcus anginosus*, *Streptococcus constellatus* and *Streptococcus intermedius*). *J Antimicrob Chemother* 1996; 37(2): 371–375.