

Solitary cerebellar metastasis of uterine cervical carcinoma

Solitární cerebelární metastáza uterinního cervikálního karcinomu

Dear Editor,

Uterine cervical cancer is one of the leading cancers in women as it is the second most common cancer worldwide. It causes approximately 275,000 female deaths yearly [1]. Nevertheless, CNS metastasis of uterine cervical carcinoma are uncommon [2,3]. Cervical cancer metastasis potential is very low (< 10%), and

there is a tendency to enter retroperitoneal lymph nodes, lungs and bone [4]. Cerebral metastasis occurs as part of a disseminated disease with systemic involvement, which has an incidence of 0.5% to 1.2% [5]. The cerebellum is a very unusual site for metastasis. The most common histopathology is shown to be a squamous cell tumor [2].

The authors declare they have no potential conflicts of interest concerning drugs, products, or services used in the study.

Autoři deklarují, že v souvislosti s předmětem studie nemají žádné komerční zájmy.

The Editorial Board declares that the manuscript met the ICMJE "uniform requirements" for biomedical papers.

Redakční rada potvrzuje, že rukopis práce splnil ICMJE kritéria pro publikace zasílané do biomedicínských časopisů.

M. B. Onal¹, A. Kircelli², E. Civelek³, O. Aydin⁴

¹Vocational School of Health Sciences, Acibadem University, Istanbul, Turkey

²Department of Neurosurgery, Istanbul Research Hospital, Baskent University, Istanbul, Turkey

³Department of Neurosurgery, Gaziosmanpaşa Taksim Education and Research Hospital, University of Health Sciences, Istanbul, Turkey

⁴Department of Pathology, Acibadem University, Istanbul, Turkey



Atilla Kircelli, MD.

Department of Neurosurgery
Istanbul Research Hospital
Baskent University

Altunizade Mahallesi
7, Kısıklı Caddesi, Oymacı Sk.
34662 Üsküdar/Istanbul
Turkey

e-mail: atillakircelli@gmail.com

Accepted for review: 15. 6. 2018

Accepted for print: 30. 10. 2018

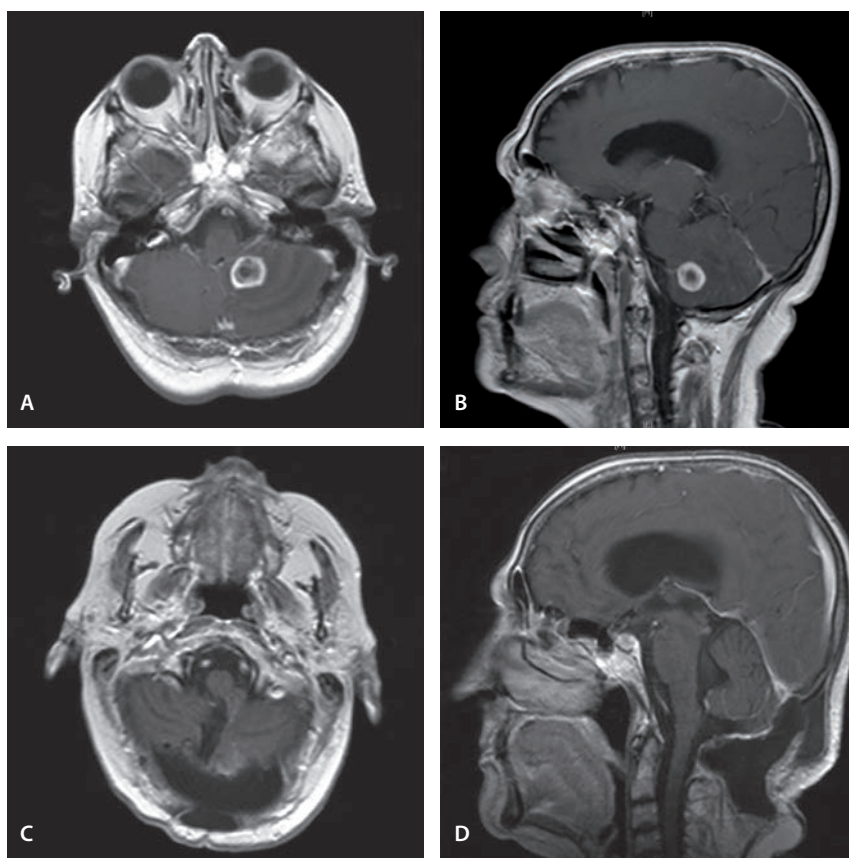


Fig. 1. Preoperative MRI of the brain demonstrates the lesion in the left cerebellar hemisphere with a heterogeneous postcontrast enhancement in axial (A) and sagittal (B) T1-weighted images. Postoperative T1-weighted postcontrast axial (C) and sagittal (D) images reveal the total excision of the tumor.

Obr. 1. Předoperační MR mozku zobrazuje lézi v levé cerebelární hemisféře s heterogenním postkontrastním enhancementem v axiálním (A) a sagitálním (B) T1 váženém obrazu. Pooperační T1 vážené postkontrastní axiální (C) a sagitální (D) obrazy zobrazují úplnou excizi nádoru.

A 65-year-old woman suffering from vaginal bleeding was referred to a gynecology clinic. Pelvic examination resulted in abdominal ultrasonography which revealed a 35 × 33 × 48 mm tumor of the cervix with parametrial invasion. Thorax and upper abdominal tomography were nor-

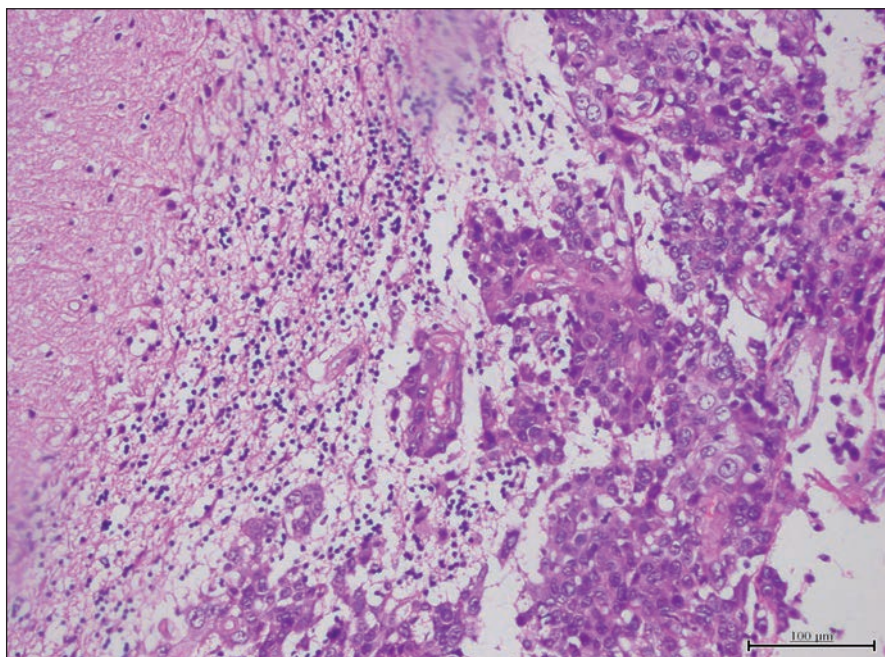


Fig. 2. Paraffin section showing a metastatic squamous cell carcinoma (hematoxylin and eosin).

Obr. 2. Parafinový řez ukazující metastatický karcinom skvamózních buněk (hematoxylin a eosin).

mal. Cervical biopsy was performed. Pathology showed a moderately differentiated invasive squamous cell carcinoma. The disease was staged 2b according to The International Federation of Gynecology and Obstetrics (FIGO) staging, so the patient underwent adjuvant radiation therapy and concurrent cisplatin containing chemotherapy. The patient was symptom free for 6 months. Then, she started to complain of nausea and dizziness. PET did not reveal any metastasis but the symptoms remained, so head tomography was performed, which revealed an occupying lesion in the left cerebellum with a mass effect on the fourth ventricle causing hydrocephalus and increasing intracranial pressure. The patient underwent a mid-line occipital craniotomy and total excision of the mass (Fig. 1), which histologically proved to be squamous cell carcinoma metastasis (Fig. 2). Intraoperatively, the tumor had a medium hardness. It was encapsulated with well-defined planes and soon after the capsule was opened, a grayish yellow mucoid fluid was seen.

She received radiotherapy to the brain 1 month post-surgery. At the end of the

10th radiation therapy, she started vomiting and displayed cerebellar syndrome. Medical treatment showed no recovery. She was sleepy and unconscious. Brain MRI revealed total excision of the left cerebellar metastasis but also tetraventricular hydrocephalus with transependymal cerebrospinal fluid pass. After pressure measurement by lumbar puncture, she underwent surgery for ventriculoperitoneal shunting. She recovered after the procedure. Eight months after cerebellar resection, the patient was dead. Before her death, she had multiple metastases to the lungs and bones.

Henriksen first reported cerebral metastasis of cervical carcinoma in 1949 in an autopsy study [6]. Cervical carcinomas similar to other gynecologic malignancies have a lower tendency to metastasize to the brain, with a rate of 0.4–1.2%. Generally, headache and hemiplegia are the most significant symptoms of brain metastasis; however, dizziness and nausea were the most common complaints of our patient. In the literature, the time from initial diagnosis to metastasis has been reported in a various range of 5 weeks to 8 years [7]. In our patient, me-

tastasis was discovered 6 months after diagnosis. In the literature, brain involvement without systemic involvement of the cervical carcinoma is very rare [8].

The treatment of brain metastasis includes radiation or surgery combined with postoperative radiation therapy. Solitary metastasis and life-threatening masses are some of the surgical indications. The median survival is longer with surgery combined with radiotherapy, which is more effective than radiotherapy treatment alone. Palliative therapy is recommended in multiple intracranial lesions with systemic dissemination [8]. It is reported that surgical resection followed by whole brain radiotherapy is the best choice in solitary brain metastasis cases [5].

Similar case reports in the literature have shown that comorbidities such as lung metastasis, are generally determined at the time of diagnosis. In our opinion, surgical resection should be performed in solitary cerebellum metastasis of cervical cancer, in the absence of another organ metastasis. Otherwise, palliative management should be chosen. Although there are several treatment modalities are available, the prognosis of cerebral metastasis from cervical cancer is still very poor.

References

1. Oaknin A, de Corcuera ID, Rodríguez-Freixinós V et al. SEOM guidelines for cervical cancer. *ClinTransOncol* 2012;14(7):516–519. doi:10.1007/s12094-012-0834-y.
2. Cormio G, Pellegrino A, Landoni F et al. Brain metastases from cervical carcinoma. *Tumori* 1996;82(4): 394–396.
3. Dadlani R, Ghosal N, Hegde AS. Solitary cerebellous metastasis after prolonged remission in a case of uterine cervical adenocarcinoma. *J Neurosci Rural Pract* 2012; 3(2): 185–187. doi: 10.4103/0976-3147.98234.
4. Tajran D, Berek J. Surgical resection of solitary brain metastasis from cervical cancer. *Int J Gynecol Cancer* 2003; 13(3): 368–370.
5. El Omari-Alaoui H, Gaye P, Kebdani T et al. Cerebellous metastases in patients with uterine cervical cancer. Two cases reports and review of the literature. *Cancer Radiother* 2003; 7(5): 317–320.
6. Henriksen E. The lymphatic spread of carcinoma of the cervix and of the body of the uterus: a study of 420 necropsies. *Am J Obstetrics Gynecol* 1949; 58(5): 924–942.
7. Peters P, Bandi H, Efendy J et al. Rapid growth of cervical cancer metastasis in the brain. *J Clinical Neurosci* 2010; 17(9): 1211–1212. doi: 10.1016/j.jocn.2010.01.021.
8. Ikeda SI, Yamada T, Katsumata N et al. Cerebral metastasis in patients with uterine cervical cancer. *Jpn J Clin Oncol* 1998; 28(1): 27–29.