

# A case of multifocal steroid-responsive encephalitis as a cause of intractable frontal lobe seizures

Případ multifokální encefalitidy reagující na léčbu steroidy jako příčiny obtížně zvládnutelných epileptických záchvatů frontálního laloku

## Abstract

We present a case report of relapsing steroid-responsive states of intractable epileptic seizures of frontal lobe origin and psychotic symptoms with a subacute onset. Cerebrospinal fluid examination revealed inflammatory changes with the presence of the oligoclonal bands,  $^{99m}\text{Tc}$ -HMPAO SPECT and  $^{18}\text{F}$ FDG-PET of the brain showed variable regions of hyperperfusion and hypermetabolism in different brain lobes, and video-EEG monitoring revealed migratory epileptic foci in both frontal lobes. Repeated MRI examination was negative, the paraneoplastic etiology was excluded and no system autoimmune disease was detected. We infer that the cause of the intractable frontal lobe seizures was multifocal encephalitis, probably of an autoimmune origin.

## Souhrn

Uvádíme kazuistiku opakovaných stavů obtížně zvládnutelných epileptických záchvatů frontálního laloku a psychotických symptomů reagujících na steroidní léčbu. Likvorologické vyšetření vykazovalo přítomnost zánětlivých změn s přítomností oligoklonálních pásů,  $^{99m}\text{Tc}$ -HMPAO SPECT a  $^{18}\text{F}$ FDG-PET mozku detekovalo variabilní oblasti hyperperfuze a hypermetabolizmu glukózy v různých oblastech mozku a video-EEG monitorace prokázala v průběhu jednotlivých atak onemocnění migrující ložiska epileptické aktivity v obou frontálních lalocích. Opakované MRI vyšetření mozku bylo negativní, vyloučena byla paraneoplastická etiologie a nebylo zjištěno žádné systémové autoimunitní onemocnění. Předpokládáme, že příčinou uvedené klinické symptomatiky je multifokální encefalitis, pravděpodobně autoimunitní etiologie.

P. Bušek, J. Fiksa, D. Tyl,  
V. Línek, E. Nešpor

Neurologická klinika 1. LF UK,  
Kateřinská 30, Praha 2, 128 00



MUDr. Petr Bušek, Ph.D.  
Neurologická klinika 1. LF UK  
Kateřinská 30, 128 00 Praha 2  
e-mail: petrbussek@seznam.cz

Přijato k recenzi: 15. 5. 2007  
Přijato do tisku: 24. 9. 2007

## Key words

autoimmune encephalitis – epilepsy –  
psychosis – steroid-responsive

## Klíčová slova

autoimunitní encefalitis – epilepsie –  
psychóza – steroidní léčba

Acknowledgements: We would like to thank to doc. MUDr. O. Bělohávek, CSc. from the PET Centre of the Na Homolce Hospital for his kind help in evaluating and preparing FDG-PET scans.

### Clinical summary

A 17-year-old girl was presented in July 1996 with a psychotic episode lasting several weeks. In September 1997 paroxysmal states of expressive aphasia appeared accompanied by anxiety, twitches of right upper limb, right face and sometimes right-sided hemiconvulsions, and generalised tonic-clonic seizures. Some seizures were followed by post-paroxysmal Todd's paresis of right limbs. At the same time psychotic symptoms developed with auditory and visual hallucinations, paranoid production, psychomotor agitation and aggressivity. During the video-EEG monitoring focal seizures were registered, the semiology of which corresponded to an epileptic focus in the left frontal lobe accompanied by repetitive theta 6 Hz or repetitive spikes over the left fronto-central region in the scalp EEG. Cranial MRI did not detect any pathology. 1H MR spectroscopy detected a decrease of N-acetylaspartate, creatinine, choline, and inositol and an increase of lactate in white matter of the left frontal lobe.  $^{99m}\text{Tc}$ -HMPAO SPECT (performed during interictal period) showed hyperperfusion in the left fronto-basal region and hypoperfusion in the right parietal and orbitofrontal regions. Magnetic resonance angiography and digital subtraction angiography were negative. Cerebrospinal fluid (CSF) examination revealed mild elevation in cell count (10 cells/mm<sup>3</sup>) with predominance of lymphoplasmocytes, intrathecal synthesis of IgA and IgM; isoelectric focusing showed 15 oligoclonal bands (OCB) in alkaline region. The CSF protein level was normal. There was no evidence of intrathecal anti-Herpes simplex virus, anti-Varicella zoster, anti-Cytomegalovirus, anti-Coxsackie A9, B1, B3, B5, anti-Enterovirus, and anti-Echovirus antibodies in the CSF. Blood studies including complete blood count and general chemistry revealed only mild normocytic anaemia and mild transitory elevation of transaminases. The examination of antinuclear antibodies (ANA), anti-dsDNA antibodies, antibodies against cytoplasm of neutrophils (ANCA), anti-extractable nuclear antigen (ENA) antibodies, anticardiolipin antibodies (ACLA), and rheumatoid factor were negative. The anti-thy-

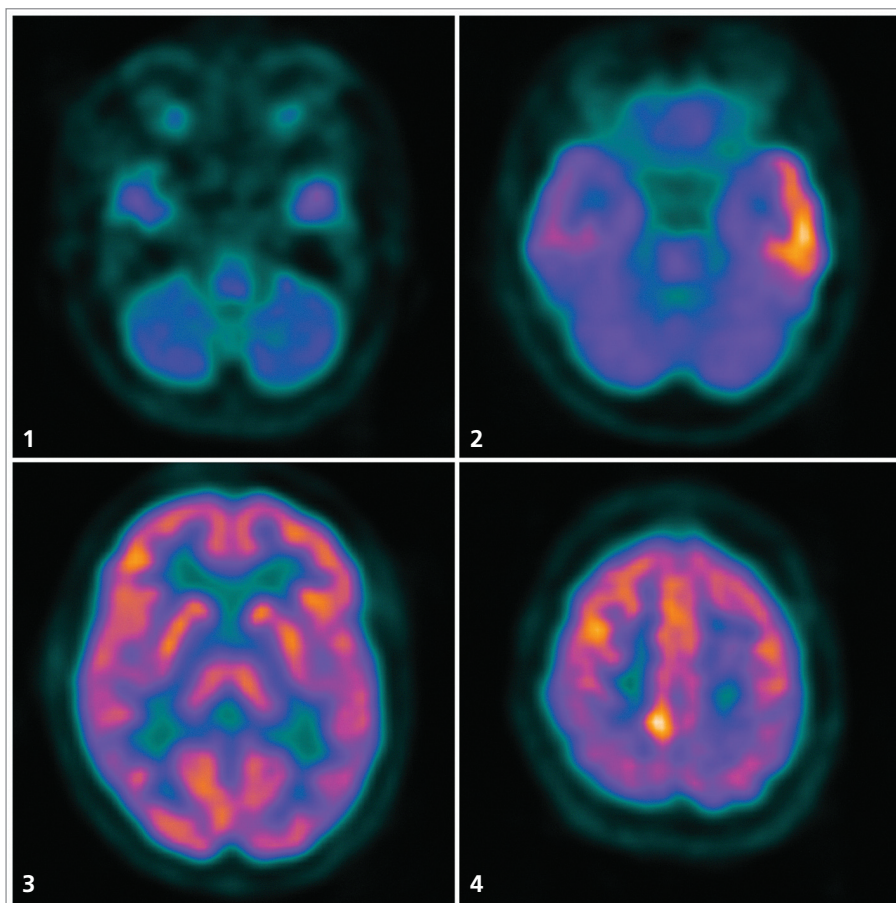


Fig.1–4. FDG-PET six months before the onset of the 3rd attack, transversal sections, caudo-cranial view.

1. Global cerebellar hypometabolism.
2. Prominent hypermetabolism laterally in the left temporal lobe and a moderate degree of hypometabolism in the anteromesial part of the left temporal lobe.
3. Physiological distribution of glucose consumption in a section at the level of basal ganglia.
4. Focal hypermetabolism parasagittally right near vertex.

The FDG-PET scans were performed in the PET Centre of the Na Homolce Hospital.

reperoxidase and anti-thyroglobulin antibodies were negative; the thyreostimulating hormone level was within normal limits. The tumour markers panel was negative. In treatment of epileptic seizures carbamazepine, phenytoine, valproate, primidone, and lamotrigine were used only with partial and transitory effect. The psychomotor agitation was treated with melperone and chlorprothixene. Because of the inflammatory CSF changes, an autoimmune inflammatory etiology was suspected and intravenous methylprednisolone was administered (1000–500–500–250–250 mg per day) followed by oral prednisone 60 mg per day and cyclophos-

phamide 100 mg per day. Several days after starting the immunosuppressive therapy the clinical picture markedly improved with disappearance of epileptic seizures and psychotic symptoms. After several weeks, the immunosuppressive treatment was slowly tapered and the patient was without any problems until July 1999 when she fell ill with pneumonia during which epileptic seizures characterised by twitches of left face and left upper limb with secondary generalisation appeared. The semiology of the epileptic seizures and interictal EEG delta activity over the right frontal region localised the epileptic focus to the right frontal lobe (an oppo-

Table.

	1 <sup>st</sup> attack 1996–1997	2 <sup>nd</sup> attack 1999	3 <sup>rd</sup> attack 2003
Clinical manifestation	Schizoform psychosis, focal epileptic seizures originating in the left frontal lobe with secondary generalisation	Psychotic symptoms, psychomotor agitation, focal epileptic seizures originating in the right frontal lobe with secondary generalisation	Memory impairment, mild disorientation, focal epileptic seizures originating in the right frontal lobe with secondary generalisation
EEG	Interictal spikes and ictal spikes or rhythmic theta over the left fronto-central region	Interictal delta over the right frontal region	Interictal spikes over the right frontal region
CSF	Mild lymphoplasmocytic pleocytosis, 15 OCB, intrathecal IgA, IgM synthesis	Normal cell count, 4 OCB, intrathecal IgA, IgM synthesis	Mild lymphoplasmocytic pleocytosis, 15 OCB, intrathecal IgG, IgA, IgM synthesis
MRI	Normal	Normal	Normal
MR angiography and digital subtraction angiography	Normal	–	–
<sup>99m</sup> Tc-HMPAO SPECT	Hyperperfusion in the left frontobasal region	Hyperperfusion in the right frontal cortex	–
FDG-PET <sup>18</sup>	–	–	Hypermetabolism in the right latero-temporal, right frontal, and left parietal region; hypometabolism in the left mesio-temporal, left frontal region, and globally in the cerebellum
Autoantibodies	Negative	–	Negative

site localisation compared to the previous site of epileptic focus in September 1997). At the same time also psychotic symptoms with psychomotor agitation developed. The cranial MRI was normal and <sup>99m</sup>Tc-HMPAO SPECT revealed hyperperfusion in the right frontal cortex. Thus, the distribution of hyperperfusion also differed from the finding during the first episode in September 1997. The CSF examination showed mononuclear oligocytosis with intrathecal synthesis of IgA and IgM and 4 OCB; the protein level was normal. After treatment of the pneumonia with antibiotics the immunosuppressive treatment was reintroduced with peroral prednisone 30 mg a day and azathioprine 50 mg a day. Several days after starting this treatment the epileptic seizures and the psychotic symptoms disappeared. The prednisone was tapered during several weeks to a lower dose and the immunosuppressive treatment was discontinued in July 2002. One year after discontinuation of prednisone in July 2003 similar clinical symptoms as in the previous episodes reappeared. This time, the character of epileptic

seizures and scalp EEG corresponded to an epileptic focus in the right frontal lobe. The CSF examination showed mild lymphoplasmocytic pleocytosis, normal protein level, intrathecal synthesis of IgA, IgG, and IgM and 15 OCB. Six months before this recurrence, the <sup>18</sup>FDG-PET examination of the brain was performed with a finding of glucose hypermetabolism laterally in the left temporal lobe and parasagittally right near vertex, less prominent hypometabolism in the anteromesial part of the left temporal lobe, and global hypometabolism in the cerebellum (Fig. 1–4). Short after the reappearance of clinical symptoms in July 2003 the <sup>18</sup>FDG-PET was repeated and revealed a changed distribution of hypermetabolic regions, which were in the right lateral temporal region, right frontal lobe and in the left parietal region this time. Hypometabolism was observed mesially in the left temporal lobe, in the left frontal lobe, and again globally in the cerebellum. Cranial MRI was normal. The examination of autoantibodies was repeated with negative finding. An overview of clinical manifestation and la-

boratory findings obtained during individual attacks are shown in the Table. The intravenous administration of methylprednisolone (500mg per day for five consecutive days) followed by peroral treatment with methylprednisolone (slowly tapered to 4 mg per day) and methotrexate (7.5 mg per week) lead to a prompt clinical improvement again. Since that time the patient continues taking methylprednisolone 4mg per day and lamotrigine (200 mg per day). Up to date, the patient is seizure free and without any problems.

## Discussion

To sum it up, the clinical picture was characterised by episodes of subacute development of schizoform psychotic symptoms and intractable frontal lobe seizures with secondary generalisation. The semiology of the epileptic seizures and the scalp EEG showed changing lateralisation of epileptic foci – initially, the epileptic focus was in the left frontal lobe, then in the right frontal lobe and later again in the right frontal lobe. The <sup>99m</sup>Tc-HMPAO SPECT, and <sup>18</sup>FDG-PET also showed changing

lateralisation and localisation of the pathologic process. Moreover, the  $^{18}\text{F}$ FDG-PET finding was multifocal detecting pathologic changes in the temporal and parietal lobes. The  $^{99\text{m}}\text{Tc}$ -HMPAO SPECT hyperperfusion in the left and later in the right frontal lobe can be explained by reactive hyperaemia accompanying the inflammatory process. Analogous finding was previously described in CNS inflammation of different origin [1]. Similarly, the FDG-PET hypermetabolism localised in variable brain lobes can reflect inflammatory changes. The FDG-PET hypermetabolism was described in the limbic encephalitis of both paraneoplastic and non-paraneoplastic form, associated with the voltage-gated potassium channel autoantibodies [2–6]. Another explanation for both the  $^{99\text{m}}\text{Tc}$ -HMPAO SPECT hyperperfusion and the FDG-PET hypermetabolism is that these findings are correlates of accidentally registered ictal SPECT and ictal PET, but this explanation seems less probable considering that the hyperperfusion and hypermetabolism were detected repeatedly during subsequent attacks and the first PET scan was performed out of the attack. We have no explanation for the finding of the regional hypometabolism observed globally in the cerebellum, anteromesially in the left temporal lobe, and during the repeated FDG-PET examination in the left frontal lobe. The finding of the OCB, intrathecal synthesis of the immunoglobulins, the lymphoplasmocytic pleocytosis in the CSF, and the effect of immunosuppressive treatment support the possibility of an autoimmune inflammatory origin.

Functional neuroimaging proved to be more sensitive than MRI in revealing the supposed inflammatory process. MRI repeatedly showed normal results although the FDG-PET $^{18}$  detected prominent pathological changes of glucose metabolism even out of the attack. This finding is similar to the previously reported observation of higher sensitivity of FDG-PET compared to MRI in patients with voltage-gated potassium channel antibodies associated limbic encephalitis [5]. The abnormalities in glucose metabolism detected by FDG-PET $^{18}$  during the period without any clinical symptoms show the evidence of a subcli-

nical activity of the pathological process between the attacks.

Because of the fact that during nine years after the onset of clinical symptoms no malignancy was found and also the tumour markers panel was negative, the paraneoplastic etiology is not probable in our patient. A very similar clinical picture was described in the steroid-responsive encephalopathy associated with autoimmune thyroiditis, which may have normal MRI finding and a good response to steroid treatment, too [7–8]. Nevertheless, there was no evidence of anti-thyroglobulin or anti-thyroperoxidase antibodies in our case.

Caselli et al. described five patients with development of delirium, psychomotor agitation, inflammatory CSF changes and with normal brain MRI finding [9]. These patients were successfully treated with corticosteroids and in some of them relapses of the symptoms appeared after discontinuation of the immunosuppressive therapy. Nevertheless, in 4 of them autoantibodies (anti-Sjögren, anti-cardiolipin, antinuclear, and anti-thyroidal microsomal antibodies) were detected. Josephs et al. presented a similar case report without presence of auto-antibodies [10]. Caselli et al. proposed the term non-vasculitic autoimmune inflammatory meningoencephalitis [9]. In the patients described in these case reports neither OCB in CSF, nor  $^{18}\text{F}$ FDG-PET of the brain were examined. In contrast to our patient, Caselli et al. and Josephs et al. reported only of one isolated epileptic seizure in one of their patients. Conversely, frequent and mostly intractable epileptic seizures were a dominating feature in our patient. Compared to our patient, who was only 17 years old when first clinical symptoms appeared, the patients reported by Caselli et al. and Josephs et al. were considerably older (56–80 years). Based on the finding of inflammatory CSF changes, migratory foci of hypermetabolism and hyperperfusion detected by the PET and SPECT and steroid-responsiveness, we suppose an autoimmune non-vasculitic encephalitis of unknown origin with both the temporal and extratemporal localisation in our patient.

## References

1. Catafau AM, Solá M, Lomeña FJ, Guelar A, Miró JM, Setoain J. Hyperperfusion and early technetium-99m-HMPAO SPECT appearance of central nervous system toxoplasmosis. *J Nucl Med* 1994; 35: 1041–1043.
2. Bien CG, Schulze-Bonhage A, Deckert M, Urbach H, Helmstaedter C, Grunwald T, et al. Limbic encephalitis not associated with neoplasm as a cause of temporal lobe epilepsy. *Neurology* 2000; 55: 1823–1828.
3. Thieben MJ, Lennon VA, Boeve BF, Akshamit AJ, Keegan M, Vernino S. Potentially reversible autoimmune limbic encephalitis with neuronal potassium channel antibody. *Neurology* 2004; 62: 1177–1182.
4. Mochizuki Y, Mizutani T, Isozaki E, Ohtake T, Takahashi Y. Acute limbic encephalitis: A new entity? *Neurosci Letters* 2006; 394: 5–8.
5. Fauser S, Talazko J, Wagner K, Ziyeh S, Jarius S, Vincent A et al. FDG-PET and MRI in potassium channel antibody-associated non paraneoplastic limbic encephalitis: correlation with clinical course and neuropsychology. *Acta Neurol Scand* 2005; 111: 338–343.
6. Salmon E, Sadzot B, Maquet, Franck G. Results of coregistration of mediotemporal  $^{18}\text{F}$ -fluoro-2-deoxy-D-glucose-positron emission tomography (FDG-PET) hyperactivity and 3D magnetic resonance imaging hyperintense lesions in limbic encephalitis. *J Neuroimaging* 2002; 12: 282.
7. Castillo PR, Boeve B, Caselli RJ, Vernino SA, Lucchinetti C, Swanson JW et al. Steroid responsive encephalopathy associated with thyroid autoimmunity: clinical and laboratory findings. *Neurology* 2002; 58(Suppl 3): A248.
8. Mahad DJ, Staugaitis S, Ruggieri P. Steroid-responsive encephalopathy associated with autoimmune thyroiditis and primary CNS demyelination. *J Neurol Sci* 2005; 228: 3–5.
9. Caselli RJ, Boeve BF, Scheithauer BW, O'Duffy JD, Hubder GG. Nonvasculitic autoimmune inflammatory meningoencephalitis (NAIM): a reversible form of encephalopathy. *Neurology* 1999; 53: 1579–1581.
10. Josephs KA, Rubino FA, Dickson DW. Nonvasculitic autoimmune inflammatory meningoencephalitis. *Neuropathology* 2004; 24: 149–152.