

Significant Brain Oedema in Unruptured Brain Arteriovenous Malformation – a Case Report

Signifikantní edém mozku u neprasklé arteriovenózní malformace – kazuistika

Abstract

Mass effect and collateral oedema in an arteriovenous malformation (AVM) are often seen to be associated with previous bleeding. Perilesional oedema can rarely occur in an unruptured AVM and cause clinical symptoms. We present a patient with relatively small left frontal AVM surrounded by substantial brain oedema in whom a generalized epileptic seizure occurred. Both – digital subtraction angiography (DSA) and MRI showed venous outflow abnormality, the most discussed aetiological factor of oedema in unruptured AVMs. The patient was successfully treated with microsurgical resection and made an uneventful recovery.

Souhrn

Perinidální edém u arteriovenózních malformací (AVM) bývá spojován s předchozím krvácením. Zřídka jej nacházíme u neprasklých malformací, kde může být příčinou vzniku epileptických záchvatů či neurologického deficitu. V naší kazuistice prezentujeme případ pacienta s relativně malou arteriovenózní malformací v levém frontálním laloku obklopenou výrazným edémem mozku, u kterého došlo ke generalizovanému epileptickému záchvatu. Mozková angiografie a vyšetření magnetickou rezonancí ukázaly abnormitu odvodné drenážní žíly, což některými autory bývá považováno za etiologický faktor vzniku perinidálního edému u neprasklých AVM. Pacient podstoupil mikrochirurgickou totální resekci AVM s nekomplikovaným pooperačním průběhem.

The authors declare they have no potential conflicts of interest concerning drugs, products, or services used in the study.

Autoři deklarují, že v souvislosti s předmětem studie nemají žádné komerční zájmy.

The Editorial Board declares that the manuscript met the ICMJE "uniform requirements" for biomedical papers.

Redakční rada potvrzuje, že rukopis práce splnil ICMJE kritéria pro publikace zasílané do biomedicínských časopisů.

J. Hanuška, J. Klener

Department of Neurosurgery,
Na Homolce Hospital, Prague



Jan Klener, MD
Department of Neurosurgery
Na Homolce Hospital
Roetgenova 2
150 00 Prague
e-mail: jan.klener@homolka.cz

Accepted for review: 1. 11. 2016

Accepted for print: 5. 4. 2017

Key words

arteriovenous malformation – brain
oedema – unruptured

Klíčová slova

arteriovenózní malformace – edém
mozku – neprasklý

We are grateful to all the colleagues and personnel of the Na Homolce Hospital who have been of an invaluable assistance in creating this case report.

Introduction

Intracranial arteriovenous malformations (AVMs) are congenital vascular lesions including feeding arteries supplying a tortuous collection of vessels („nidus“) lea-

ding blood directly into the draining veins without an intervening capillary bed [1]. Its prevalence is unclear, but its incidence is approximately 1 per 100,000 person-years [2]. Intracranial haemorrhage is the

most common clinical presentation of AVMs, followed by seizures, headache or neurological deficit [1,3–5]. Microsurgical resection, endovascular embolisation and radiosurgery are the treatment modalities used in clinical

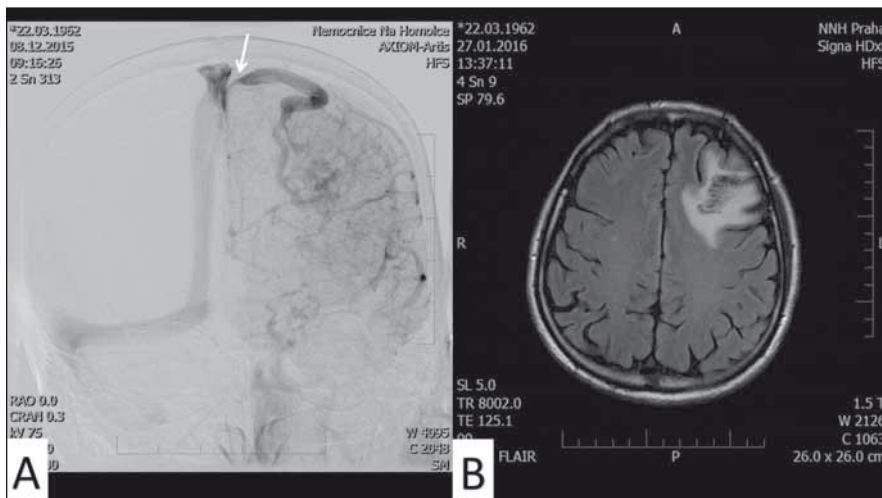


Fig. 1. Preoperative MRI and DSA examination.

Fig. 1A) Cerebral angiography, pial AVM in left frontal lobe fed mainly via the left internal carotid artery and drained by dilated vein with apparent stenosis (white arrow) closed to its inflow to the superior sagittal sinus.

Fig. 1B) MRI (FLAIR T2 weighted imaging), pial AVM with significant brain edema.

practice [5–7]. Brain oedema associated with unruptured AVM is infrequent (1.2–3.9%) [8] and discussed in only a few reports. Venous congestion is considered to be the cause of the oedema [8]. Perilesional brain oedema may increase the rate of progressive non-haemorrhagic symptoms as well as possible haemorrhagic risk [8].

Case report

A 53-year-old man was hospitalized after two generalized tonic-clonic seizures (GTCS) with no history of previous epilepsy or any other neurological disease. On computed tomography (CT) and magnetic resonance imaging (MRI) a lateral frontal AVM was found. No neurological deficit on the cranial nerves and ex-

trémities was observed during neurological examination. Cerebral digital subtraction angiography (DSA) (Axiom-Artis HFS) identified lateral frontal AVM (maximum diameter 39mm axis, Spetzler Martin (SM) grade II) fed mainly via the left internal carotid artery (ACI) and drained by a dilated vein with an apparent stenosis close to its confluence with the superior sagittal sinus. Additional MRI (Signa HDxT 1.5T) showed an AVM with a significant oedema surrounding the lesion and blood stasis in a dilated draining vein proximal to the venous stenosis, no signs of previous bleeding were found (Fig. 1). Because the

AVM was symptomatic and showed an increased risk of a draining vein stenosis, the microsurgical treatment was indicated. The patient underwent surgery 1 month later and the AVM was totally removed by a standard microsurgical technique (Fig. 2).

The patient made an uneventful recovery, no neurological deficit, including seizures, occurred postoperatively. A follow-up cerebral DSA verified complete removal of the AVM (Fig. 3).

Discussion

Perilesional brain oedema associated with unruptured brain AVM is an uncommon finding recognized on CT or MRI scans [8,9] and occurring with incidence of 1.2–3.9% [8]. In 1985, Kumar et al. first described this phenomenon in their paper published in the American Journal of Neuroradiology [10]. Since then, only a few studies have been concerned with this subject and detailed information is lacking.

The aetiological factor of oedema is supposed to be a venous outflow abnormality. Frequent imaging findings in those cases include varicosity in the major cortical draining vein, dilated venous sac [11] or increased venous pressure secondary to severe stenosis of the draining vein [9]. Several studies suggested that perinidal oedema might be caused by a mass effect due to the AVM itself [9,11] and also by a local brain parenchymal hypoxia due to the arterial steal

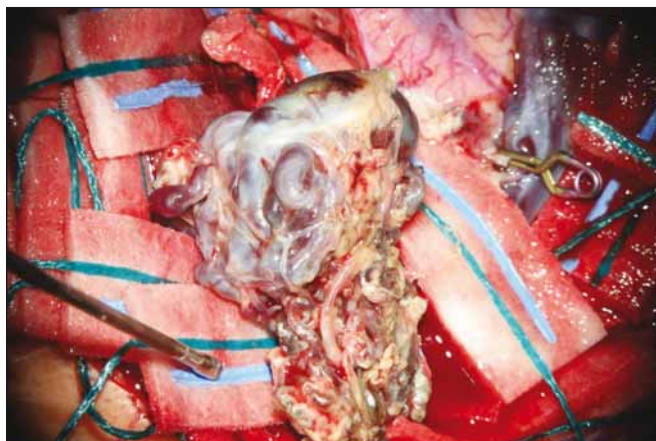


Fig. 2. A photo during the operation, removed pial AVM with draining vein closed by an clip.

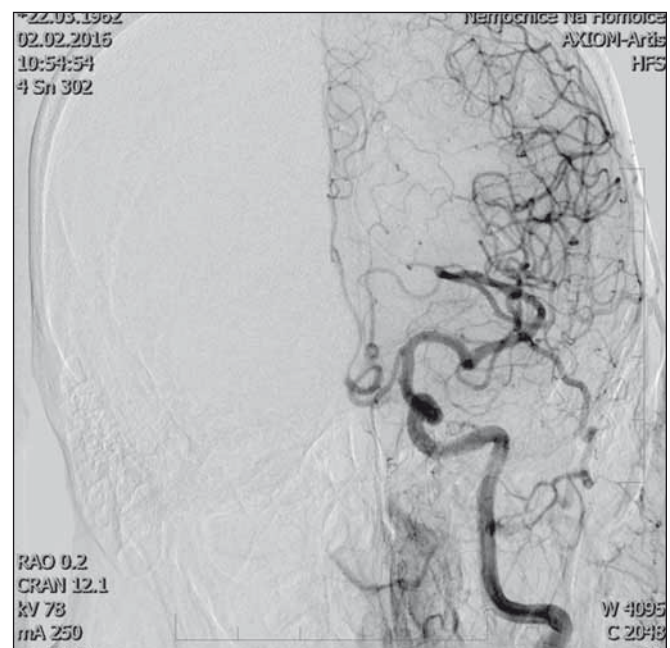


Fig. 3. Postoperative cerebral angiography, complete resection of the pial AVM.

phenomenon [9]. In several studies [12–14], a brain tissue hypoxia around the nidus is shown but it is not present in all cases. Moreover, Nagakawa et al. demonstrated normal vasoreactivity in low perfusion areas using SPECT (Single Photon Emission Computed Tomography), and this is in accordance with the Mayers study. Even if the perinidal hypoxia is present, the hypoperfusion area is not in a misery perfusion [13]. It suggests that oedema does not have its origin in a local hypoxia. However, studies on this issue are lacking. Impaired vascular wall of the venous components of AVMs was described in previous studies [15,16]. Microstructural and signaling molecule abnormalities of the vascular wall and the impact of these changes on occurrence of perinidal oedema are currently the focus of research teams. Promoter polymorphism in the interleukin-6 gene (IL-6), tumour necrosis factor (TNF- α) and infiltration of inflammatory cells and cytokines are demonstrated in vascular wall even in unruptured AVMs [17].

The most common clinical presentations of intracranial AVMs are intracranial haemorrhage (50%), seizures (30%), headache (15%) and neurological deficit (5%) [1,3–5]. In our case report, GTCS was the initial symptom. The frontal lobe location, pial long draining vein, venous outflow stenosis, male sex and the age of less than 65 years are associated with seizure occurrence rate in AVMs [18,19]. Symptoms manifestation is caused by the size (mass effect) and location (eloquent or non-eloquent area) of the lesion and the brain oedema. Grade of the oedema correlates with the clinical manifestation [8]. Kim et al. presented three patients with oedema in AVM treated conservatively whose symptoms worsened with progression of oedema.

DSA finding in the perinidal brain oedema, such as dilated draining vein with

distal stenosis observed in this case report, is also associated with a significantly higher risk of haemorrhagic complications [20,21]. Current treatment decision is based on carefully weighting the risk of a spontaneous hemorrhage against the risk of intervention [17]. In our case report we chose, in agreement with the patient, a microsurgical treatment that is considered a gold standard in low SM grade AVMs with the lowest rate of complications [19].

Conclusion

This case report presents a 53-year-old man with unruptured brain AVM surrounded by substantial parenchymal oedema who was successfully treated with a neurosurgical intervention. This infrequent finding of perilesional oedema in unruptured AVMs significantly influences the rate of non-haemorrhagic symptoms and increases the risk of haemorrhage. This needs to be taken into account when managing patients with intracranial AVMs.

References

1. Abecassis JJ, Xu DS, Batjer HH, et al. Natural history of brain arteriovenous malformations: a systematic review. *Neurosurg Focus* 2014;37(3):E7. doi: 10.3171/2014.6.FOCUS14250.
2. Berman MF, Sciacca RR, Pile-Spellman J, et al. The epidemiology of brain arteriovenous malformations. *Neurosurgery* 2000;47(2):389–96.
3. Stapf C, Mohr JP, Pile-Spellman J, et al. Epidemiology and natural history of arteriovenous malformations. *Neurosurg Focus* 2001;11(5):e1. doi: 10.3171/foc.2001.11.5.2.
4. Tong X, Wu J, Lin F, et al. The effect of age, sex, and lesion location on initial presentation in patients with brain arteriovenous malformations. *World Neurosurg* 2015; 87:598–606. doi: 10.1016/j.wneu.2015.10.060.
5. Darsaut TE, Magro E, Gentric JC, et al. Treatment of brain AVMs (TOBAS): study protocol for a pragmatic randomized controlled trial. *Trials* 2015;16:497. doi: 10.1186/s13063-015-1019-0.
6. Plasencia AR, Santillan A. Embolization and radiosurgery for arteriovenous malformations. *Surg Neurol Int* 2012;3(Suppl 2):90–104. doi: 10.4103/2152-7806.95420.
7. Hartmann A, Mast H, Mohr JP, et al. Determinants of staged endovascular and surgical treatment outcome

of brain arteriovenous malformations. *Stroke* 2005;36(11): 2431–5. doi: 10.1161/01.STR.0000185723.98111.75.

8. Kim BS, Sarma D, Lee SK, et al. Brain edema associated with unruptured brain arteriovenous malformations. *Neuroradiology* 2009;51(5):327–35. doi: 10.1007/s00234-009-0500-4.

9. Shimizu S, Miyasaka Y, Tanaka R, et al. Pial arteriovenous malformation with massive perinidal edema. *Neurol Res* 1998;3(3):249–52.

10. Kumar AJ, Viñuela F, Fox AJ, et al. Unruptured intracranial arteriovenous malformations do cause mass effect. *Am J Neuroradiol* 1985;6(1):29–32.

11. Miyasaka Y, Yada K, Kurata A, et al. An unruptured arteriovenous malformation with edema. *Am J Neuroradiol* 1994;15(2):385–8.

12. Meyer B, Schaller C, Frenkel C, et al. Distributions of local oxygen saturation and its response to changes of mean arterial blood pressure in cerebral cortex adjacent to arteriovenous malformations. *Stroke* 1999;30(12):2623–30.

13. Nakagawa I, Kawaguchi S, Iida J, et al. Postoperative hyperperfusion associated with steal phenomenon caused by a small arteriovenous malformation. *Neurol Med Chir (Tokyo)* 2005;45(7):363–6.

14. Arkan F, Vilalta J, Noguer M, et al. Intraoperative monitoring of brain tissue oxygenation during arteriovenous malformation resection. *J Neurosurg Anesthesiol* 2014;26(4):328–41. doi: 10.1097/ANA.0000000000000033.

15. Zhang R, Zhu W, Su H. Vascular integrity in the pathogenesis of brain arteriovenous malformation. *Acta Neurochir Suppl* 2016;121:29–35. doi: 10.1007/978-3-319-18497-56.

16. Chen W, Guo Y, Walker EJ, et al. Reduced mural cell coverage and impaired vessel integrity after angiogenic stimulation in the Alk1-deficient brain. *Arterioscler Thromb Vasc Biol* 2013;33(2):305–10. doi: 10.1161/ATVBAHA.112.300485.

17. Rutledge WC, Ko NU, Lawton MT, et al. Hemorrhage rates and risk factors in the natural history course of brain arteriovenous malformations. *Transl Stroke Res* 2014;5(5):538–42. doi: 10.1007/s12975-014-0351-0.

18. Shankar JJ, Menezes RJ, Pohlmann-Eden B, et al. Angioarchitecture of brain AVM determines the presentation with seizures: proposed scoring system. *Am J Neuroradiol* 2013;34(5):1028–34. doi: 10.3174/ajnr.A3361.

19. Diaz O, Scranton R. Endovascular treatment of arteriovenous malformations. *Handb Clin Neurol* 2016;136:1311–7. doi: 10.1016/B978-0-444-53486-6.00068-5.

20. Mansmann U, Meisel J, Brock M, et al. Factors associated with intracranial hemorrhage in cases of cerebral arteriovenous malformation. *Neurosurgery* 2000;46(2):272–9.

21. Valavanis A, Yaşargil MG. The endovascular treatment of brain arteriovenous malformations. *Adv Tech Stand Neurosurg* 1998;24:131–214. doi: 10.1016/B978-0-444-53486-6.00068-5.