proLékaře.cz | 26.11.2026



doi: 10.14735/amcsnn2018596

# Thoracic spinal schwannoma with massive intratumoural haemorrhage

## Spinální schwannom v oblasti hrudní páteře s masivním intratumorálním krvácením

Dear Editor,

Schwannomas are benign, slow-growing tumours, arising from the Schwann cells of the nerve sheath. Spinal schwannomas have an incidence of 0.3–0.4 cases in every 100,000 persons per year and account for approximately 13% of all spinal tumours [1].

The classic pattern of growth is dumbbell-shaped. The majority are subdural extramedullary, but completely extradural schwannomas can also be found.

Patients usually present with radiculopathy followed by slowly progressive spinal cord compression syndrome.

The treatment of choice is always surgical, total resection being curative.

Up to this point, there have been only a few cases of schwannomas presenting with intratumoural haemorrhage reported in the literature. We present a case of a thoracospinal schwannoma with acute intralesional bleeding.

A 72-year-old man was admitted with abrupt onset of paraplegia. The patient had a history of high frequency atrial fibrillation and was undergoing treatment with oral anticoagulants. The initial examination showed international normalized ratio (INR) of 9.4. Doppler ultrasonography of the lower limbs revealed no signs of thrombosis. The cerebral CT scan excluded ischaemic or haemorrhagic stroke or subarachnoid haemorrhage.

Upon admission, a neurological exam showed T6 American Spinal Injury Association score (ASIA). A paraplegia, absent deep tendon reflexes in the lower limbs, plantar reflexes, and cutaneous abdominal reflexes and loss of sphincter control. A spinal MRI revealed an extramedullary T5–T6 thoracic lesion (Fig. 1).

The patient underwent emergency surgery. We performed decompressive T4–T7 laminectomies and left T5–T6 facetectomy. We found an encapsulated, red extradural tumour, Asazuma IIb, measuring 4.5 × 2.5 × 1.5 cm, causing massive compression of the spinal cord. The tumour was attached to the T5 left nerve root. A fenestration was made within the tumour capsule in order to perform intracapsular debulking. We found an intratumoural haematoma, which was evacuated. The extraforaminal part of the tumour was gradually brought into the surgical field by staged intracapsular debulking and progressively pulling the capsule inside the spinal canal. As the tumour was easily mobilised through the enlarged foramen, we did not need to perform an extracanalar approach. Finally, the tumour capsula was dissected free from its attachment from the T5 nerve root, achieving total resection (Fig. 2). The histopathological exam revealed an Antoni A schwannoma with intratumoural haemorrhage.

The patient presented no postoperative complications. In the 1st day following surgery, the patient regained sensitivity in his lower limbs and during the following days, he partially regained motor function in the right lower limb (ASIA 2). No sphincteral function was regained. Neurorehabilitation began on the 3rd day after surgery. A postoperative MRI showed T4–T7 laminectomies, complete resection of the tumour and reexpansion of the spinal cord.

Two months after surgery, he had full sensitivity and ASIA 3 motor function in his lower limbs and had regained sphincter control. At the 6- and 12-month follow-ups he had ASIA 4 motor function in his lower limbs.

Schwannomas are slow-growing, benign tumours which only exceptionally present with haemorrhage. Searching the relevant literature, we were able to find only 44 cases from 1930 to 2017. Spinal schwannomas with haemorrhagic onset can be found in any part of the spinal canal, from C1–C2 [2,3] to the cauda equina.

Bleeding can occur intratumourally, in the subarachnoid space and/or in the subdural space. Intratumoural bleeding causes rapid tumour enlargement and patients present with sudden onset of spinal cord compression. Intratumoural bleeding had been reported in only 12 patients until now.

There are a number of theories that can explain the possible mechanism of bleeding. The vascular theory [4] assumes

**The authors declare they have no potential conflicts of interest concerning drugs, products, or services used in the study.**
Autoři deklarují, že v souvislosti s předmětem studie nemají žádné komerční zájmy.
**The Editorial Board declares that the manuscript met the ICMJE "uniform requirements" for biomedical papers.**
Redakční rada potvrzuje, že rukopis práce splnil ICMJE kritéria pro publikace zasílané do biomedicínských časopisů.

A. M. Sandu[1], B. I. David[1], A. Gheorghiu[1], M. A. Fürtös[1], N. Bucur[1], F. M. Brehar[1,2], M. R. Gorgan[1,2]

[1] Neurosurgery Clinic, Bagdasar-Arseni Clinical Hospital, Bucharest, Romania
[2] Carol Davila University of Medicine and Pharmacy, Bucharest, Romania

✉
Felix Mircea Brehar
Neurosurgery Clinic
Bagdasar-Arseni Clinical Hospital
10-12 Berceni Street
041915 Bucharest, Romania
e-mail: felixbrehar@yahoo.com

Accepted for review: 20. 4. 2018
Accepted for print: 9. 8. 2018

proLékaře.cz | 26.11.2026



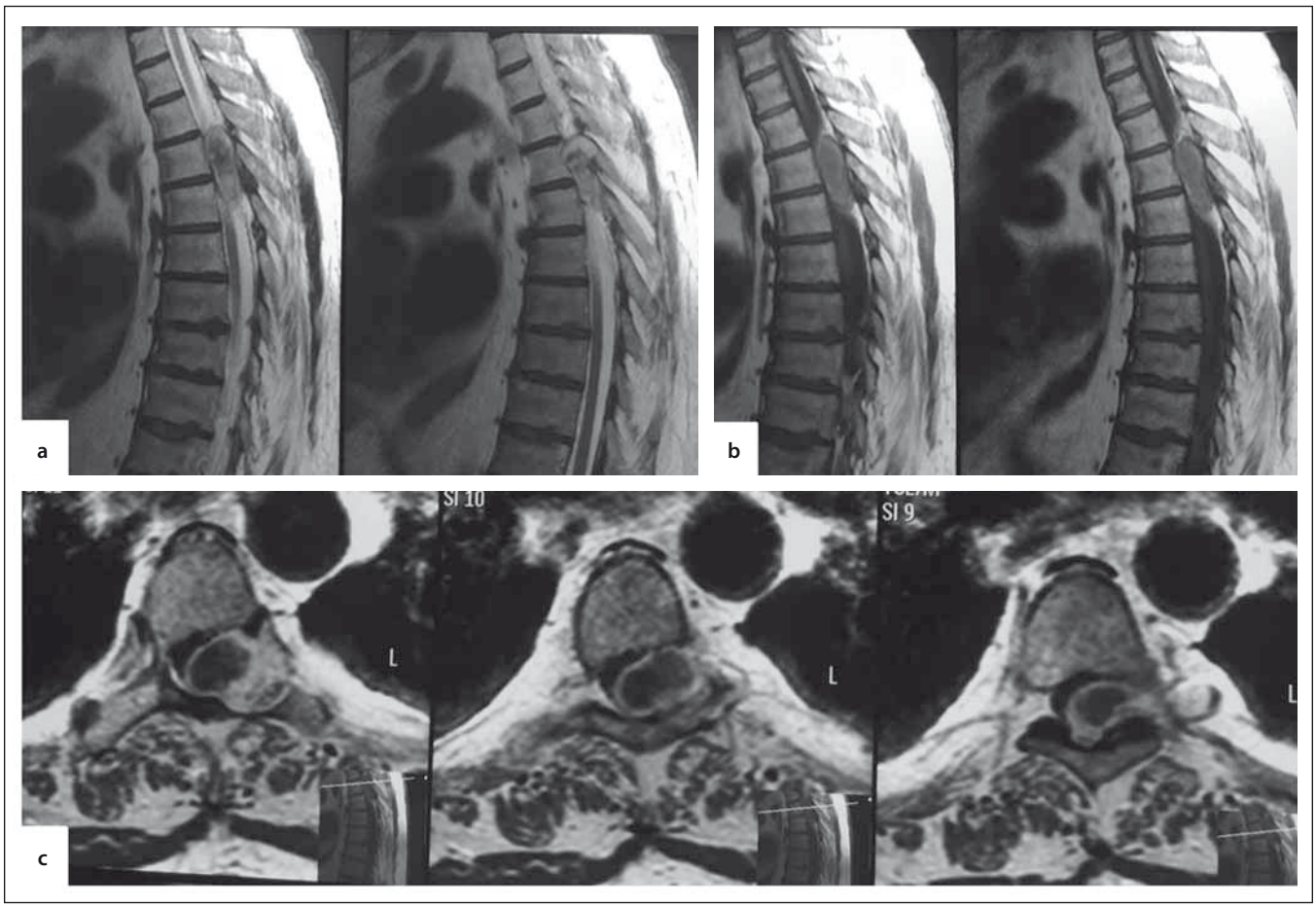


Fig. 1. Spinal MRI. A – sagittal T2W, B – sagittal T1W, C – axial T1W. Extramedullary, inhomogeneous, thoracic lesion, occupying the spinal canal, compressing the spinal cord and extending extraforaminally, enlarging the left T5–6 foramen.

T1W – T1-weighted image; T2W – T2-weighted image

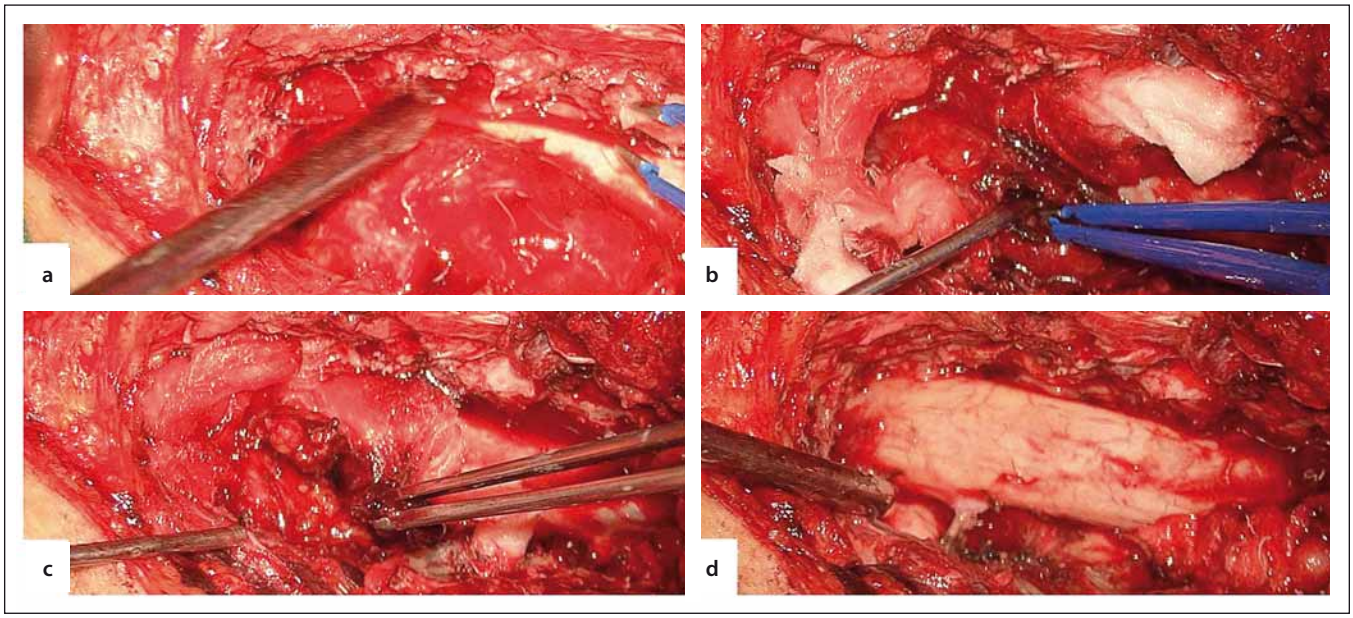


Fig. 2. Intraoperative images. A – encapsulated, extramedullary tumour, B – fenestration in the tumour capsule, C – evacuation of an intracapsular haematoma, D – final aspect with total resection of the tumour.

proLékaře.cz | 26.11.2026



that the tumour induces the formation of abnormal vessels and thrombosis. The central ischaemic necrosis theory presumes that haemorrhage appears due to unequal balance between the tumour growth and neo-vessel formation. The mechanical theory implies rupture of the peritumoural vessels due to traction induced by tumour growth [5]. Furthermore, secondary bleeding from the tumour may occur due to the misuse of oral anticoagulants [6,7] or traumatic events [8].

We consider that prolonged overdose of oral anticoagulants favoured bleeding from an already existing spinal schwannoma. The patient had no history of neurological deficits, although he had a benign spinal tumour, slowly growing for a long period of time, causing enlargement of the vertebral foramen and posterior arch atrophy compression. The patient became symptomatic only after acute bleeding occurred inside the tumour, causing massive and sudden expansion of the capsule.

Surgery for thoracic schwannomas consists in posterior (hemilaminectomy, laminectomy, ± facetectomy), posterolateral (transpedicular, costotransversectomy), lateral (lateral extracavity thoracic), anterior (transthoracic) or combined approaches. The surgery chosen for treatment of our lesion was a posterior approach T4–T7 laminectomy. We chose this wide approach in order to get an access to the entire tumour mass and one level above and one level below the lesion. Besides good visualisation of both the tumour and levels above and below the lesion, a wide opening of the spinal canal is indicated in patients with acute spinal compression syndrome because it provides large decompression of the spinal cord. The left facetectomy was needed in a posterior approach to gain access to the intraforaminal and extraforaminal parts of the tumour. The posterior approach provides the widest spinal decompression and it is suitable in large tumours because the larger the tumour, the bigger the surgical corridor. We were able to preserve the nerve root, although in this location the nerve root can be safely sectioned.

The particularity of this case is unusual presentation with massive intratumoural bleeding in a thoracic schwannoma. This rare case suggests that neurosurgeons should be aware of the possible rapid evolution and abrupt neurological deterioration of a patient with a spinal schwannoma, especially when the patient is following chronic anticoagulant therapy.

Spinal schwannomas presenting with haemorrhage are extremely rare, only 44 cases have been reported since 1930. There are a number of theories that can explain intratumoural haemorrhage; however, one must not exclude secondary reasons, such as improper dosing of oral anticoagulants. Furthermore, we emphasise the need to include intratumoural bleeding in a spinal schwannoma as a differential diagnosis in patients presenting with abrupt neurological deficit. Surgery is the treatment of choice in patients with acute spinal cord compression and intracanalar lesions, to ensure a good neurological outcome.

## References

**1.** Guha D, Davidson B, Nadi M et al. Management of peripheral nerve sheath tumors: 17 years of experience at Toronto Western Hospital. J Neurosurg 2018; 128(4): 1226–1234. doi: 10.3171/2017.1.JNS162292.
**2.** Chalif DJ, Black K, Rosenstein D. Intradural spinal cord tumour presenting as a subarachnoid hemorrhage: magnetic resonance imaging diagnosis. Neurosurgery 1990; 27(4): 631–634.
**3.** Ciappetta P, D'Urso PI, Colamaria A. Giant craniovertebral junction hemorrhagic schwannoma: case report. Neurosurgery 2008; 62(5): E1166. doi: 10.1227/01.neu.0000325881.21118.a6.
**4.** Cordon T, Bekar A, Yaman O. Spinal subarachnoid hemorrhage attributable to schwannoma of the cauda equina. Surg Neurol 1999; 51(4): 373–375.
**5.** Luxon LM, Harrison MJ. Subarachnoid hemorrhage and papilledema due to a cervical neurilemmoma: case report. J Neurosurg 1978; 48(6): 1015–1018. doi: 10.3171/jns.1978.48.6.1015.
**6.** Motomochi M, Makita Y, Nabeshima S et al. Spinal subarachnoid hemorrhage due to a thoracic neurinoma during anticoagulation therapy – a case report. Neurol Med Chir (Tokyo) 1981; 21(7): 781–784.
**7.** Ichinose T, Takami T, Yamamoto N et al. Intratumoral hemorrhage of spinal schwannoma of the cauda equina manifesting as acute paraparesis – case report. Neurol Med Chir (Tokyo) 2009; 49(6): 255–257.
**8.** Nadeem M, Mansoor S, Assad S et al. Spinal schwannoma with intradural intramedullary hemorrhage. Cureus 2017; 9(3): e1086. doi: 10.7759/cureus.1086.

**Na webu csnn.eu je k dispozici rozšířená verze tohoto článku.**