

# Chondroblastic osteosarcoma of maxilla, a patient with Li-Fraumeni syndrome

## Chondroblastický osteosarkom maxily, pacientka s Li-Fraumeni syndromem

### Abstract

Osteosarcoma of the jaw is a very rare and highly malignant tumor, which could be a manifestation of Li-Fraumeni syndrome – an inherited cancer syndrome characterized by a high frequency and wide spectrum of early onset neoplasms. Incidence of jaw osteosarcoma is only about 0.07/100,000 per year. The tumor's stage and possibility of complete surgical removal have the biggest impact on patient prognosis. Because rare, osteosarcomas are often misdiagnosed initially, which delays treatment and worsens the prognosis. We present a 32-year-old female patient with Li-Fraumeni syndrome and initially misdiagnosed chondroblastic osteosarcoma. After incomplete resection and early local recurrence, which completely filled the defect after subtotal maxillectomy, we achieved curative response and more than 7 years disease-free survival with chemo-radiotherapy. Furthermore, we describe symptoms, diagnosis, and treatment of this rare disease, and also focus on Li-Fraumeni syndrome. Outcome of this case report disagrees with the widely held tenet that chemo-radiotherapy of osteosarcoma of the jaw is considered only a palliative treatment, unexpected response of some tumors to treatment, and the role of *p53* mutations still are not clear and are the object of extensive investigations.

### Souhrn

Osteosarkom čelistních kostí představuje velice vzácný a vysoce zhoubný novotvar, který může být jedním z projevů Li-Fraumeniho syndromu – dědičného onemocnění, charakterizovaného vysokou pravděpodobností časného vzniku širokého spektra maligních nádorů. Incidence osteosarkomů čelistních kostí je asi 0,07/100 000. Prognózu pacienta nejvíce ovlivňuje stádium tumoru a možnost kompletního radikálního odstranění nádoru. Vzhledem k vzácnosti tohoto onemocnění bývají osteosarkomy čelistí zpočátku často špatně diagnostikovány, což vede ke zpoždění v zahájení léčby a zhoršení prognózy. V tomto článku prezentujeme případ 32leté pacientky s Li-Fraumeni syndromem postižené chondroblastickým osteosarkomem, který také nebyl v úvodu správně diagnostikován. Po nekompletní resekci a časně lokální recidivě, která zcela vyplnila defekt po subtotální maxilektomii, bylo chemoradioterapií dosaženo kurativní odpovědi a více než 7letého přežití bez návratu onemocnění. Dále ve sdělení popisujeme příznaky, diagnostiku a léčbu tohoto vzácného onemocnění a také se zaměřujeme na Li-Fraumeniho syndrom. Zajímavostí tohoto případu je kurativní odpověď osteosarkomu po podání chemoradioterapie, která je všeobecně pokládána jen za paliativní léčbu. Nečekaná odpověď některých nádorů na léčbu, stejně jako role mutace genu *p53* stále nejsou zcela objasněny a jsou předmětem rozsáhlého výzkumu.

The authors declare they have no potential conflicts of interest concerning drugs, products, or services used in the study.

Autoři deklarují, že v souvislosti s předmětem studie nemají žádné komerční zájmy.

The Editorial Board declares that the manuscript met the ICMJE "uniform requirements" for biomedical papers.

Redakční rada potvrzuje, že rukopis práce splnil ICMJE kritéria pro publikace zasílané do biomedicínských časopisů.

**J. Zelinka, J. Blahák, Z. Daněk, O. Bulík**

Department of Oral and Maxillofacial Surgery, University Hospital Brno, Czech Republic  
Faculty of Medicine, Masaryk University, Brno, Czech Republic



**Jiří Zelinka, MD**  
Department of Oral and Maxillofacial Surgery  
University Hospital Brno  
Jihlavská 20  
652 00 Brno  
Czech Republic  
e-mail: zelinka.jiri@email.cz

Accepted for review: 13. 7. 2018

Accepted for print: 16. 8. 2018

### Key words

chondroblastic osteosarcoma – Li-Fraumeni syndrome – jaw

### Klíčová slova

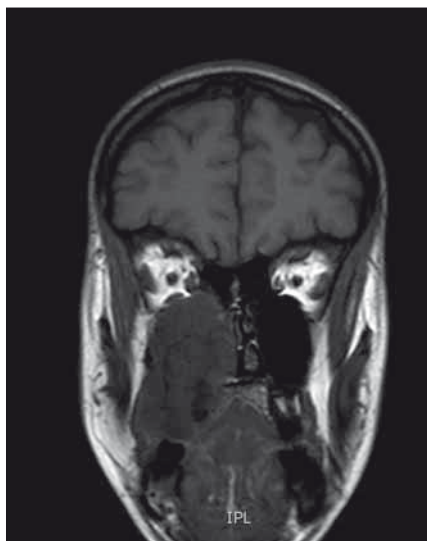
chondroblastický osteosarkom – Li-Fraumeni syndrom – čelist

### Introduction

Osteosarcoma is highly malignant bone tumor in which mesenchymal cells produce osteoid. There are three histological subtypes of osteosarcomas – osteoblastic, chondroblastic and fibroblastic, depending on predominance of the neoplastic component. Although they are the second

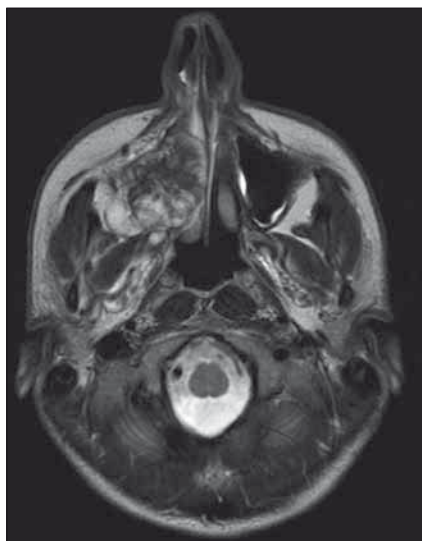
most common primary malignant bone tumor after multiple myeloma, they are still very rare [1]. Incidence of osteosarcoma of the jaw is about 0.07 case per 100,000 population per year [2]. Men develop osteosarcoma more often than women (about 60% of patients with jaw osteosarcoma are men) [1,2]. There are some differences

between osteosarcomas of the jaw and those of the long bones, which are more common. The peak incidence for jaw osteosarcoma is in the 3<sup>rd</sup>–4<sup>th</sup> decade, while the average age of occurrence of conventional osteosarcoma is about decade earlier [1,2]. Also, in biological behavior osteosarcoma of jaws differs from conventional osteosarcomas by



**Fig. 1. MRI coronar view – demonstrates large mass in the maxilla extending to the nasal cavity, also causing bulging and destruction of hard palate.**

Obr. 1. MR koronární pohled – zobrazuje masivní hmotu v horní čelisti až do nosní dutiny, což také způsobuje deviace a destrukci tvrdého patra.



**Fig. 2. MRI transverse view – sarcoma in the right maxilla, obstructing right part of nose, deviating nasal septum and expanding into infratemporal fossa.**

Obr. 2. MR příčný/transverzální pohled – sarkom v pravé maxile, obstrukce pravé části nosu, odklonění nosní přepážky a rozšíření do infratemporální fossy.

a lower incidence of metastasis and better prognosis, on the other hand the radical surgical treatment as well as radiotherapy of sarcomas of the bones of the face can change negatively and influence quality of life, due to function deficits and esthetic of the face, especially when healing complications after radiotherapy occur [1–4]. The etiology of osteosarcoma of the jaws is not known, it has been associated with radiotherapy, Paget disease, trauma, etc. Osteosarcomas are also characteristic for Li–Fraumeni syndrome (LFS), which is a rare, dominantly inherited cancer syndrome characterized by high frequency of early onset and a wide spectrum of neoplasms. Most common are sarcomas, premenopausal breast carcinomas, carcinomas of the lung, skin, pancreas and adrenal cortex, leukemia, and brain tumors [2,3,5–8]. Classic LFS was defined as proband, with sarcoma diagnosed under age 45 years, who has a first degree relative with any cancer under 45 years, and another first- or second-degree relative with either any cancer under 45 years or a sarcoma at any age [9].

### Case report

A 32-year-old woman was referred to the Department of Oral and Maxillofacial Surgery, University Hospital Brno, for gradually enlarg-

ing swelling on the right side of the hard palate. For about a month her dentist treated the condition as odontogenic infection, by extraction of the second right upper molar, which was not vital. She also complained about pressure in the right maxilla. Intraoral examination demonstrated an extraction socket without any pathology, and painless, firm swelling of the right hard palate. Patient history revealed a high risk for malignant disease caused by the presence of LFS and *p53* mutation in patient's family. The patient in the past underwent genetic testing and she is a *p53* germ-line mutation carrier. The patient had not informed her dentist about this condition. Panoramic radiography and Water's view of skull revealed a radiopaque mass in the right maxillary sinus. An incisional biopsy was performed, but microscopic examination showed only chronic inflammatory infiltration.

Continuing suspicion of a malignant lesion led us to further investigation. Another incisional biopsy and head CT scan were performed. Histopathological examination of the second specimen established the final diagnosis of high grade (G3) chondroblastic osteosarcoma with *TP53* mutation in 100% of the tumor cells. The CT image showed a lesion inside the right maxillary sinus extending to the nasal cavity, ethmoidal

cells, and pterygopalatine fossa. For better anatomic definition, a head MRI was performed (Fig. 1, 2). Bone scintigraphy, chest CT scan, and ultrasonography of neck, abdomen, and pelvis showed no metastatic spread of osteosarcoma. During 2 weeks there was visible local progression of the disease; tumorous spread to the vestibule, and also onto the alveolar ridge. Patient started to complain about nasal obstruction. Patient underwent subtotal maxillectomy, but the tumor was too large and not amenable to complete surgical intervention, mainly in the pterygopalatine fossa. Local recurrence began soon after surgery and the tumor mass completely filled the defect after previous operation. The oncologists decided to use palliative chemotherapy and radiotherapy. After four cycles of chemotherapy (doxorubicin, cisplatin) (the 3<sup>rd</sup> and 4<sup>th</sup> cycles of chemotherapy were reduced 25% for poor tolerance and toxicity), and locoregional radiotherapy 57.2 Gy (26 × 2.2 Gy), complete remission of the disease was achieved. Almost 7 years after adjuvant therapy, the patient was without recurrence of the tumor. The defect after subtotal maxillectomy was covered with an obturator prosthesis, with good function and esthetic, no impaired wound healing after chemotherapy and radiotherapy had occurred and good quality of life was achieved.

### Discussion

Osteosarcoma is a highly malignant, but rare, tumor. Its incidence is about 1 case per 100,000 persons, with approximately 4% to 8% arising in the jaw. As a result, with few case reports or retrospective studies available, diagnosis, mainly in the early stages, is made more difficult [2,3,10,11]. In August's review of 30 osteosarcomas of the jaw 13 were initially misdiagnosed as odontogenic infection, as in the case presented here [3]. Differential diagnosis of chondroblastic osteosarcoma, besides inflammation, includes fibrous dysplasia, Paget's disease, high-grade carcinoma, Ewing's sarcoma, and chondrosarcoma, which has similar histological features but better prognosis and lower potential for metastasis than chondroblastic osteosarcoma [12–14].

Symptoms of osteosarcomas of the jaws are not specific. Most patients complain of a mass or swelling, about half of the patients suffer pain; other symptoms are loose teeth or displacement of teeth,

paresthesia, toothache, bleeding, and nasal obstruction. Radiological appearance may be a radiolucent, radiopaque, or mixed. In a study of 46 patients with craniofacial osteosarcomas the dominant pattern in mandibular tumors was osteoblastic, while in other craniofacial areas it was osteolytic. Plain films are of limited worth, while CT provides perfect anatomic definition of the tumor, and MRI is even more effective [15]. Histological evaluation of the biopsy specimen is always necessary to confirm diagnosis. Also, in the case presented the patient's report of hard palate swelling was initially misdiagnosed as inflammation. The patient was later discovered to have LFS and is a *p53* germ-line mutation carrier. This syndrome is characterized by a high frequency of early onset of various tumors. It is a rare condition, with mutations of *p53* identified in 60% to 80% of families with LFS [16,17]. Wu et al. report that men with germ-line *p53* mutation have 151-fold higher odds of developing cancer than those with no mutations; women have even higher odds – 1.075-fold. Lifetime risk of cancer was estimated at about 70% in males, and nearly 100% in females in LFS families [18,19].

There is still ethical controversy about genetic testing of possible *p53* mutation carriers, especially in children. The patient in this case is the mother of two children, 6 and 11 years old, who have not been tested yet. The data show the importance of screening and follow up of individuals with LFS; nevertheless, no international consensus on clinical surveillance recommendations has been established. There are varying strategies in different countries. For example in the United States the National Comprehensive Cancer Network published the following guidelines: monthly breast self-exam starting at age 18; clinical breast exam every 6 months starting at age 20–25 or 5–10 years before the earliest known breast cancer in the family; annual mammogram or breast MRI starting at age 20–25; discuss option of risk-reducing mastectomy; annual physical exam, especially focused on skin and neurological assessment; colonoscopy every 2–5 years; additional organ-targeted surveillance based on family history [20]. The goal of screening is early establishment of a correct diagnosis, and curative treatment of tumors.

One difficulty with disease surveillance in LFS patients is that the spectrum of tumors is very wide and may be found in almost

every site of the body. So, every doctor taking care of a patient with LFS, including the dentist, should be aware of the high risk of malignant disease to avoid delayed tumor recognition. For osteosarcomas of the jaw that are too large for radical resection the prognosis is very poor. In Clark's review of 66 patients the recurrence rate for large tumors was 80% within 24 months, and with recurrence, the chances for survival were greatly decreased [1].

The presented case is interesting for several reasons, some of them are in disagreement with widely held tenets. First, chemotherapy and radiotherapy alone are generally considered to be palliative, with mortality estimated to be 100% [3]. In this case, early local recurrence completely filled the postoperative defect before any adjuvant therapy was set, but after chemoradiotherapy complete remission was achieved, with no evidence of recurrence after almost 7 years. Second, the basis of tumor response to cancer treatment is still poorly understood; according to some studies tumor cells with mutations in *p53* resist apoptosis, chemotherapy, and radiotherapy [21–27]. The response to chemotherapy and radiotherapy in the presented case was unexpected, with a curative outcome despite the patient being a *p53* germ-line mutation carrier. Third, there is controversy about radiotherapy in patients with LFS. *p53* germ-line mutation carriers have abnormal sensitivity to radiogenic carcinogenesis, and there is evidence that radiation-induced tumors frequently occur in the radiation field, radiotherapy also carries a risk of osteoradionecrosis of the jaw, xerostomia, radiation dermatitis, delayed wound healing and so on. So, it is believed that, if possible, radiotherapy should be avoided [6,28]. In this case, after very early local relapse, with very poor long-term prognosis, and knowledge that radiation-induced tumors occurred with latency often longer than 10 years, the oncologists decided to use a combination of radiotherapy and chemotherapy to achieve the best possible control of local spread.

After almost 7 years, patient is without any clinical or radiological sign of recurrence. Careful long-term follow-up of patients with LFS is crucial. Individuals with the *p53* mutation are also at very high risk of developing secondary tumors, and radiation-induced sarcoma as a late

sequel of radiation therapy. The goal of this article was to present and describe a rare tumor and syndrome with an unexpected curative response to palliative treatment.

## References

- Clark JL, Unni KK, Dahlin DC et al. Osteosarcoma of the jaw. *Cancer* 1983; 51(12): 2311–2316.
- Garrington GE, Scofield HH, Cornyn J et al. Osteosarcoma of the jaws. Analysis of 56 cases. *Cancer* 1967; 20(3): 377–391.
- August M, Magennis P, Dewitt D. Osteogenic sarcoma of the jaws: factors influencing prognosis. *Int J Oral Maxillofac Surg* 1997; 26(3): 198–204.
- Chindia ML. Osteosarcoma of the jaw bones. *Oral Oncol* 2001; 37(7): 545–547.
- Chabchoub I, Gharbi O, Remadi S et al. Postirradiation osteosarcoma of the maxilla: a case report and current review of literature. *J Oncol Internet* 2009; 876138. doi: 10.1155/2009/876138.
- Chompret A. The Li-Fraumeni syndrome. *Biochimie* 2002; 84(1): 75–82.
- Varley JM, Evans DG, Birch JM. Li-Fraumeni syndrome – a molecular and clinical review. *Br J Cancer* 1997; 76(1): 1–14.
- Li FP, Fraumeni J, Joseph F. Soft-tissue sarcomas, breast cancer, and other neoplasms. A familial syndrome? *Ann Intern Med* 1969; 71(4): 747–752.
- Li FP, Fraumeni JF, Mulvihill JJ et al. A cancer family syndrome in twenty-four kindreds. *Cancer Res* 1988; 48(18): 5358–5362.
- Cade S. Malignant disease and its treatment by radium. London: Simpkin Marshall 1952.
- George A, Mani V, Sunil S et al. Osteosarcoma of maxilla – a case of missed initial diagnosis. *Oral Maxillofac Pathol J* 2010; 1: 1–7.
- Gupta N, Rajwanshi A, Gupta P et al. Chondroblastic osteosarcoma of the temporal region: a diagnostic dilemma. *Diagn Cytopathol* 2011; 39(5): 377–379. doi: 10.1002/dc.21440.
- Saito K, Unni KK, Wollan PC et al. Chondrosarcoma of the jaw and facial bones. *Cancer* 1995; 76(9): 1550–1558.
- Amaral MB, Buchholz I, Freire-Maia B et al. Advanced osteosarcoma of the maxilla: a case report. *Med Oral Patol Oral Cirugia Bucal* 2008; 13(8): E492–E495.
- Lee Y, Van Tassel P, Nauert C et al. Craniofacial osteosarcomas: plain film, CT, and MR findings in 46 cases. *Am J Roentgenol* 1988; 150(6): 1397–1402. doi: 10.2214/ajr.150.6.1397.
- Kleihues P, Schauble B, zur Hausen A et al. Tumors associated with *p53* germline mutations: a synopsis of 91 families. *Am J Pathol* 1997; 150(1): 1–13.
- Olivier M, Goldgar DE, Sodha N et al. Li-Fraumeni and related syndromes: correlation between tumor type, family structure, and TP53 genotype. *Cancer Res* 2003; 63(20): 6643–6650.
- Malkin D. Li-Fraumeni Syndrome. *Genes Cancer* 2011; 2(4): 475–484. doi: 10.1177/1947601911413466.
- Wu CC, Shete S, Amos CI et al. Joint effects of germ-line *p53* mutation and sex on cancer risk in Li-Fraumeni syndrome. *Cancer Res* 2006; 66(16): 8287–8292. doi: 10.1158/0008-5472.CAN-05-4247.
- Mai PL, Malkin D, Garber JE et al. Li-Fraumeni syndrome: report of a clinical research workshop and creation of a research consortium. *Cancer Genet* 2012; 205(10): 479–487. doi: 10.1016/j.cancergen.2012.06.008.
- Bergamaschi D, Gasco M, Hiller L et al. *p53* polymorphism influences response in cancer chemotherapy via

modulation of p73-dependent apoptosis. *Cancer Cell* 2003; 3(4): 387–402.

**22.** McIlwraith AJ, Vasey PA, Ross GM et al. Cell cycle arrests and radiosensitivity of human tumor cell lines: dependence on wild-type p53 for radiosensitivity. *Cancer Res* 1994; 54(14): 3718–3722.

**23.** Weller M. Predicting response to cancer chemotherapy: the role of p53. *Cell Tissue Res* 1998; 292(3): 435–445.

**24.** Huang HY, Illei PB, Zhao Z et al. Ewing sarcomas with p53 mutation or p16/p14ARF homozygous deletion: a highly lethal subset associated with poor chemoresponse. *J Clin Oncol* 2005; 23(3): 548–558. doi: 10.1200/JCO.2005.02.081.

**25.** Brown JM, Wouters BG. Apoptosis, p53, and tumor cell sensitivity to anticancer agents. *Cancer Res* 1999; 59(7): 1391–1399.

**26.** Wunder JS, Gokgoz N, Parkes R et al. TP53 mutations and outcome in osteosarcoma: a prospective, mul-

ticenter study. *J Clin Oncol* 2005; 23(7): 1483–1490. doi: 10.1200/JCO.2005.04.074.

**27.** Keshelava N, Zuo JJ, Chen P et al. Loss of p53 function confers high-level multidrug resistance in neuroblastoma cell lines. *Cancer Res* 2001; 61(16): 6185–6193.

**28.** Limacher JM, Frebourg T, Natarajan-Ame S et al. Two metachronous tumors in the radiotherapy fields of a patient with Li-Fraumeni syndrome. *Int J Cancer* 2001; 96(4): 238–242.