

# Anterior choroidal artery aneurysm

## Aneuryzma arteria choroidea anterior

Dear editorial office,  
Anterior choroidal artery aneurysms (AChoAA) represent 2–5% of intracranial aneurysms [1,2]. As with other aneurysms of the supraclinoid segment of internal carotid artery (ICA) they are considered rather easily accessible surgical goals. Nevertheless, the tight anatomical relations between ICA, its main branches and perforating branches make it a surgically demanding area. The problematic feature might be the position and number of the arteries themselves. Also, the relationship between the artery and the aneurysm is critical, as the vessel might be distorted or completely hidden by the sac [1,2]. Therefore, a thorough knowledge of possible anatomical variations is vital for a surgeon. Safe position of AChoA during clipping is also crucial because its occlusion might result in severe consequences, such as contralateral hemiplegia, hemianesthesia, and hemianopia [3]. Intraoperative accidental occlusion of AChoA or one of its main branches is considered the main cause of vascular insufficiency leading to permanent postoperative morbidity. To prevent this, firstly the AChoA area should be precisely investigated. However, DSA is not often accurate enough to determine clear anatomy of the arterial branching. Therefore, perioperative electrophysiological motor evoked potentials (MEP) monitoring is considered necessary for avoiding territorial ischemia. AChoA generally supplies the posterior limb of the internal capsule, hence monitoring of pyramidal tract integrity during surgery might be reassuring while a clip is being placed [4,5].

The aim of this case report is to emphasize the complexity of surgical clipping of aneurysms in the anatomically complicated area of AChoA if important perforators arise in close proximity or directly from the aneurysm. We also suggest the necessity of intraoperative monitoring for successful results.

A 44-year-old female patient was examined for several non-specific symptoms, such as remittent headache, left retrobulbar pressure, vertigo, and upper limb acro-

paresthesia. CT and CTA showed incidental finding of left unruptured AChoAA with diameter of 6 mm. DSA confirmed that the choroidal artery was arising from the neck of the sac (Fig. 1). After discussion within our cerebrovascular team, it was decided to proceed with surgical treatment of the aneurysm as the conventional coiling procedure would have a high risk of subsequent occlusion of AChoA, with a potential poor clinical outcome.

We chose the lateral supraorbital approach to reach the aneurysm. After release of cerebrospinal fluid from the chiasmatic cistern to relax the surrounding brain, we dissected the arachnoid from the medial side of ICA to expose a thin posterior communicating artery (PCoA) and AChoA with its two branches tightly encircling the fundus of the aneurysm. AChoA arose from the proximal part of the neck. The anatomical relations did not allow us to approach the neck of the aneurysm from either the medial or the lateral side; neither was possible to separate the artery from the fundus. After quick reconsideration we decided to occlude the aneurysm using the Yasargil titanium T-bar clip (B. Braun Medical s.r.o., Prague, Czech Republic) from above during occlusion of ICA with a temporary clip. After doing so, we used Microvascular Doppler ultrasonography (MVDS) to check for flow in surrounding vessels, including AChoA. Confident that the blood supply was safe, we decided to add another fenestrated clip for a tiny remnant distally on the neck of the aneurysm. However, at the time of application we witnessed a MEP modification, signalling a lower signal to contralateral hand. We then saw a conflict between the second clip and the perforating branches coming from ICA bifurcation, which were previously out of view. After removal of the clip, the MEP normalized. Knowing that, rather than adding another clip to the area of many crucial perforating branches, we decided to only slightly adjust position of the T-bar clip to both exclude the remnant and not to compromise flow in other vessels. MVDS and indocyanine green (ICG) confirmed that the sac had been excluded from the circulation.

**The authors declare they have no potential conflicts of interest concerning drugs, products, or services used in the study.**

Autoři deklarují, že v souvislosti s předmětem studie nemají žádné komerční zájmy.

**The Editorial Board declares that the manuscript met the ICMJE “uniform requirements” for biomedical papers.**

Redakční rada potvrzuje, že rukopis práce splnil ICMJE kritéria pro publikace zasílané do biomedicínských časopisů.

**H. Zítek<sup>1</sup>, A. Hejčíl<sup>1,2</sup>, F. Cihlák<sup>3</sup>,  
A. Sejkorová<sup>1</sup>, M. Sameš<sup>1</sup>**

<sup>1</sup>Neurochirurgická klinika Fakulty zdravotnických studií UJEP a Masarykovy nemocnice v Ústí nad Labem

<sup>2</sup>Mezinárodní centrum klinického výzkumu, FN u sv. Anny v Brně

<sup>3</sup>Radiologická klinika UJEP a Masarykovy nemocnice v Ústí nad Labem



**MUDr. Hynek Zítek**  
Neurochirurgická klinika UJEP  
a Masarykova nemocnice  
Ústí nad Labem  
Sociální péče 3316/12A  
401 13 Ústí nad Labem  
e-mail: hynek.zitek@gmail.com

Accepted for review: 24. 1. 2019

Accepted for print: 4. 4. 2019

The patient had an uneventful postoperative course. The CTA after surgery did not show any evidence of complication or remnant of the aneurysm (Fig. 2).

Ongoing studies dealing with both surgical and endovascular procedures securing AChoAA are important because ischemic complications in the above described AChoA territory may lead to severe consequences, known as anterior choroidal artery syndrome [1–3].

The position of AChoA, a small vessel with significant but variable hemodynamics, in close proximity of aneurysm makes surgical

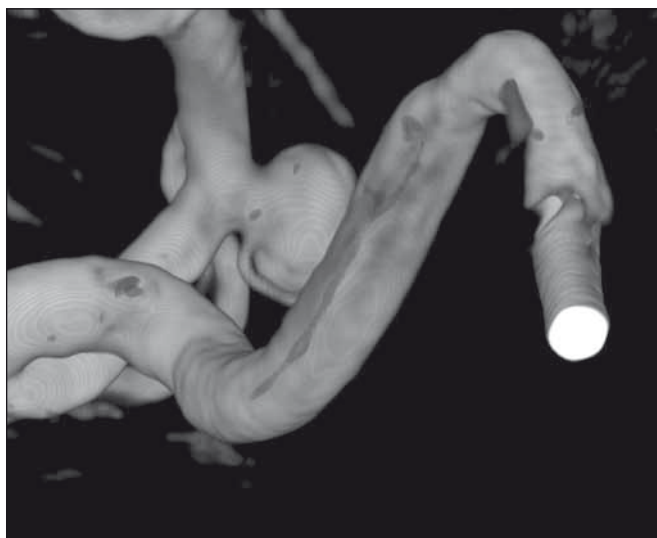

Fig. 1. Angiography 3D reconstructions showing anterior choroidal artery arising from the aneurysm neck.

Obr. 1. 3D rekonstrukce angiografie zobrazující arteria choroidea anterior vystupující z krčku aneurysmatu.

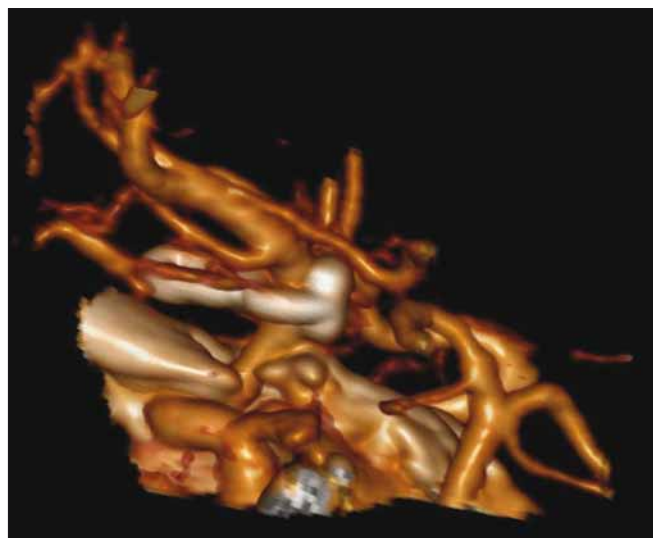


Fig. 2. Postoperative CTA reconstruction demonstrating a T-bar clip fully excluding the aneurysm from circulation.

Obr. 2. Pooperační rekonstrukce CTA zobrazující klip typu T-bar zcela vyřazující aneurysma z cirkulace.

clipping a demanding procedure. Additionally, the goal of complete occlusion of the sac has to be achieved while preserving other close structures, namely PCoA, ICA perforators, AChoA branches, and the oculomotor nerve. Only with exact anatomical perception with temporary clips in place can the optimal final clip be chosen and kinking or occlusion of the adjacent branches prevented. The blade in proximity of the origin of AChoA should be placed a small distance away from the origin to avoid any constriction of it [6].

The complex anatomy of AChoA and potential severe outcome in cases of ischemic infarction after clipping have taught us to use several monitoring intraoperative techniques. Firstly, we routinely use MVDS with a 1-mm probe. MVDS is able to assess obliteration of aneurysm after clipping, direction and velocity of local blood flow of adjacent vessels, and collateral flow after possible trapping of a sac at a specific point in time [7]. Another monitoring method during clipping of AChoAA that we regularly use is MEP monitoring. It is considered a highly sensitive method in reflecting po-

tential functional motor deficit [4,5]. In comparison to MVDS, MEP monitoring allows us to get a continuous view of functional integrity; therefore we consider that a combination of these methods during AChoAA clipping is strongly preferable and helps the surgeon to avoid possible irreversible ischemia. As no intraoperative method is totally reliable, we also add ICG angiography to exclude a neck remnant or residual sac filling, and also to assess blood flow in neighbouring arteries [8,9].

Surgical treatment of aneurysms of AChoA may be associated with significant complications for the patient. With support of the presented case, we claim that surgical clipping, along with the aid of the monitoring methods, is a safe method even with anatomical obstacles, and is a good alternative to endovascular treatment.

## References

1. Friedman JA, Pichelmann MA, Piepgras DG et al. Ischemic complications of surgery for anterior choroidal artery aneurysms. *J Neurosurg* 2001; 94(4): 565–572. doi: 10.3171/jns.2001.94.4.0565.
2. Lehecka M, Dashti R, Laakso A et al. Microneurosurgical management of anterior choroid artery aneurysms.

*World Neurosurg* 2010; 73(5): 486–499. doi: 10.1016/j.wneu.2010.02.001.

3. Foix Ch, Chavany JA, Hillemand P. Oblitération de l'artère choroïdienne antérieure. Ramollissement cérébral, hémiparésie, hémianesthésie et hémianopsie. *Soc Ophthalmol* 1925: 221–223.

4. Neuloh G, Schramm J. Monitoring of motor evoked potentials compared with somatosensory evoked potentials and microvascular Doppler ultrasonography in cerebral aneurysm surgery. *J Neurosurg* 2004; 100(3): 389–399. doi: 10.3171/jns.2004.100.3.03893

5. Suzuki K, Kodama N, Sasaki T et al. Intraoperative monitoring of blood flow insufficiency in the anterior choroidal artery during aneurysm surgery. *J Neurosurg* 2003; 98(3): 507–514. doi: 10.3171/jns.2003.98.3.0507.

6. Lee YS, Park J. Anterior choroidal artery aneurysm surgery: ischemic complications and clinical outcomes revisited. *J Korean Neurosurg Soc* 2013; 54(2): 86–92. doi: 10.3340/jkns.2013.54.2.86.

7. Shibata Y, Fujita S, Kawaguchi T et al. Use of microvascular Doppler sonography in aneurysm surgery on the anterior choroidal artery. *Neurol Med Chir (Tokyo)* 2000; 40(1): 30–37. doi: 10.2176/nmc.40.30.

8. Dashti R, Laakso A, Niemelä M et al. Microscope-integrated near-infrared indocyanine green videoangiography during surgery of intracranial aneurysms: the Helsinki experience. *Surg Neurol* 2009; 71(5): 543–550. doi: 10.1016/j.surneu.2009.01.027.

9. de Oliveira JG, Beck J, Seifert V et al. Assessment of flow in perforating arteries during intracranial aneurysm surgery using intraoperative near-infrared indocyanine green videoangiography. *Neurosurgery* 2008; 62 (6 Suppl 3): 1300–1310. doi: 10.1227/01.neu.0000333795.21468.d4.

Na webu csnn.eu naleznete rozšířenou verzi tohoto článku.  
Please visit csnn.eu for an extended version of this article.