proLékaře.cz | 24.4.2024

doi: 10.48095/cccsnn2021214

Primary diffuse large B-cell lymphoma of the parietal bone

Primární difuzní velkobuněčný B-lymfom temenní kosti

Dear editor,

Primary bone lymphoma (PBL) is a rare disease that accounts for about 5% of all extranodal lymphomas, and the most common subtype is a non-Hodgkin diffuse large B-cell lymphoma (DLBCL) represent approximately 50–92% of PBLs [1]. Much more common plasma cell tumors are not included in this entity. The lesion may be in a single focus or disseminated, since polyostotic disease occurs in approximately 15–20% of patients. PBL should be distinguished from much more common secondary bone involvement in the case of nodal or other extranodal lymphoma, whereas these may be indistinguishable [1]. The most frequent sites of PBL are the femur, spine, and pelvic bones. PBL of the skull is uncommon. Herein,

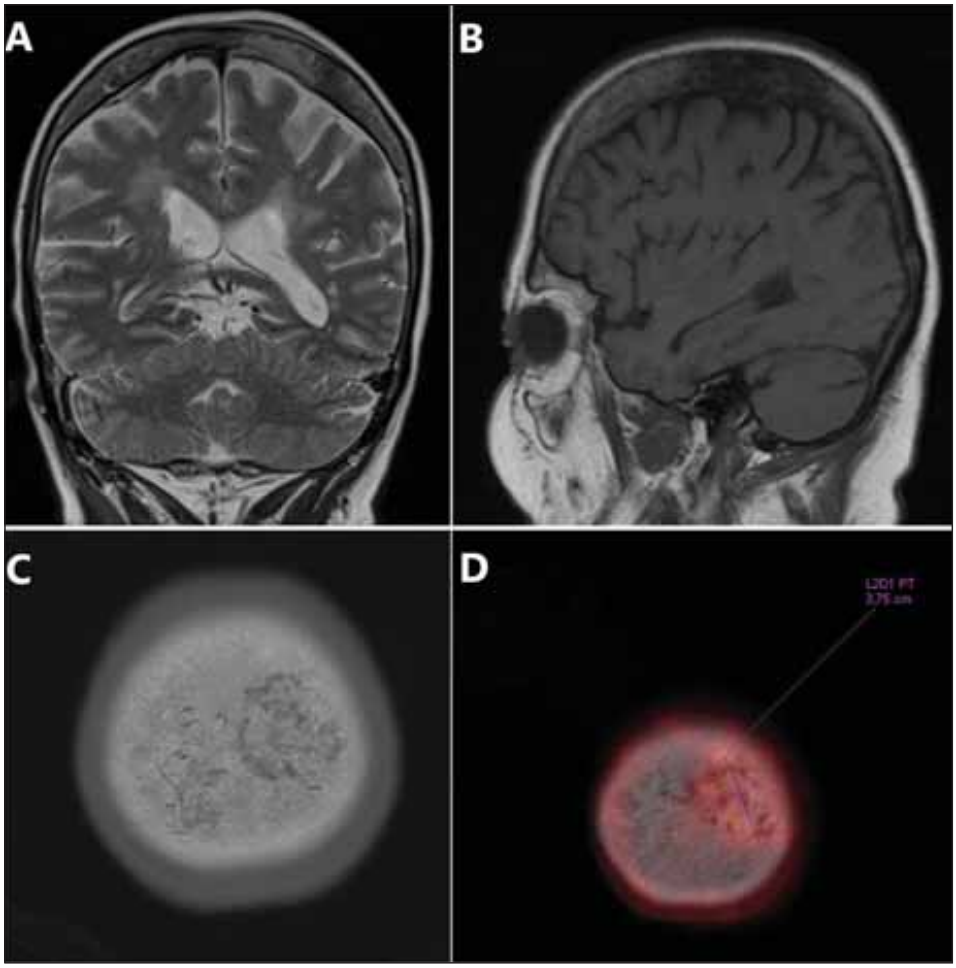

Fig. 1. (A) MRI – coronary T2W image. Atypical signal in the left parietal bone in comparison to opposite side; (B) MRI – sagital non-enhanced T1W image. Pathological enhancement in the parietal bone lesion; (C) "Bone window" CT image. Osteolytic changes in the left parietal bone; (D) PET/CT image. Increased accumulation in the parietal bone lesion.

Obr. 1. (A) MR – T2 vážený koronární snímek. Atypický signál v levé temenní kosti v porovnání s pravou stranou; (B) MR – T1 vážený nativní sagitální snímek. Patologické sycení temenní kosti v oblasti léze; (C) CT „kostní okno". Osteolýza v levé temenní kosti; (D) PET/CT vyšetření. Zvýšená akumulace v ložisku v temenní kosti.

The Editorial Board declares that the manuscript met the ICMJE "uniform requirements" for biomedical papers.

Redakční rada potvrzuje, že rukopis práce splnil ICMJE kritéria pro publikace zasílané do biomedicínských časopisů.

J. Hrudka[1], V. Eis[1], Z. Prouzová[1], M. Holešta[2], I. Zubatá[3], F. Šámal[4]

[1] Department of Pathology, 3rd Faculty of Medicine, Charles University, University Hospital Královské Vinohrady, Prague, Czech Republic
[2] Department of Radiodiagnostics, 3rd Faculty of Medicine, Charles University, University Hospital Královské Vinohrady, Prague, Czech Republic
[3] Department of Hematology, 3rd Faculty of Medicine, Charles University, University Hospital Královské Vinohrady, Prague, Czech Republic
[4] Department of Neurosurgery, 3rd Faculty of Medicine, Charles University, University Hospital Královské Vinohrady, Prague, Czech Republic

✉
Jan Hrudka, MD, PhD
Department of Pathology
3rd Faculty of Medicine
Charles University
Kralovske Vinohrady University Hospital
Ruská 87, 100 00 Prague
Czech Republic
e-mail: jan.hrudka@lf3.cuni.cz

Accepted for review: 10. 2. 2021
Accepted for print: 23. 3. 2021

proLékaře.cz | 24.4.2024

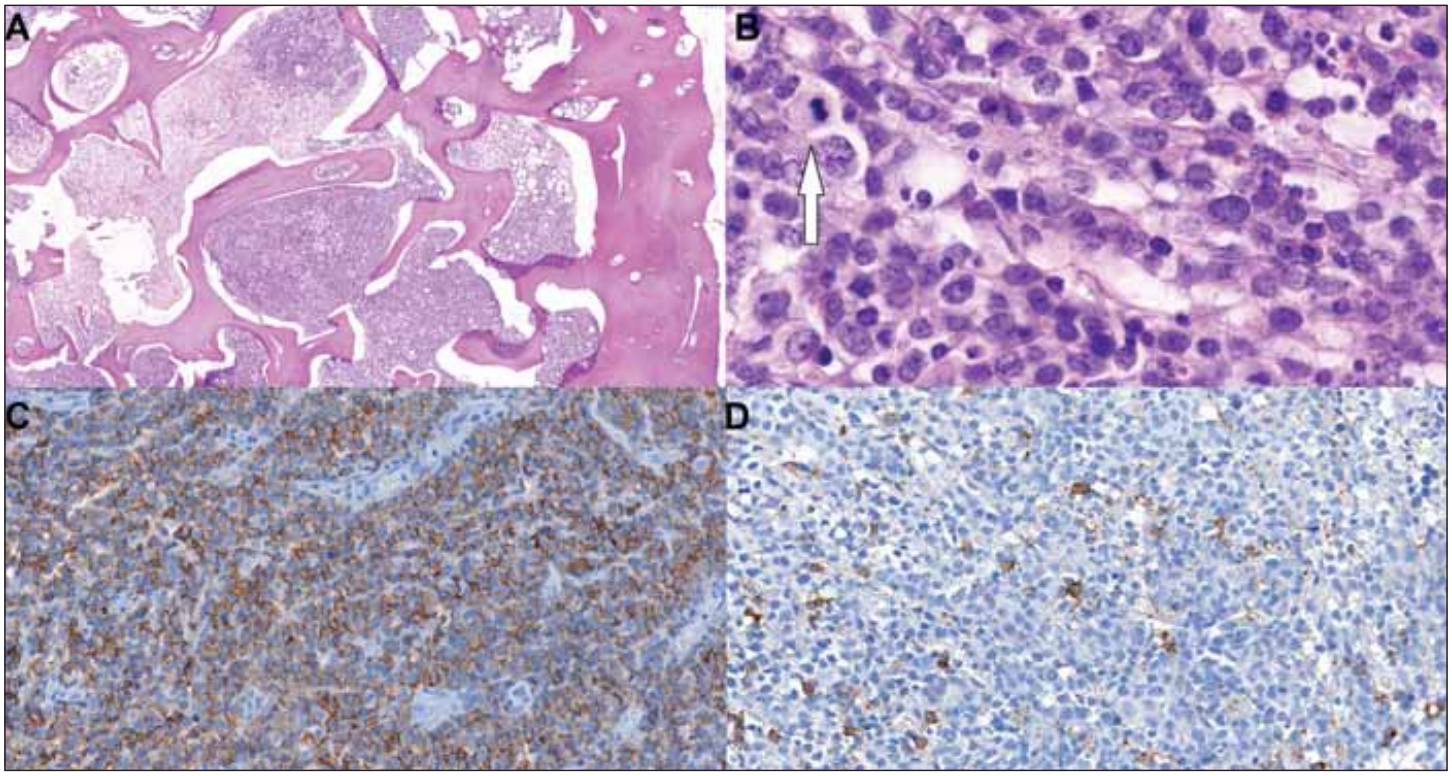

Fig. 2. Histology showing bone marrow spaces diffusely infiltrated by abundant large non-cohesive cells with sparse cytoplasm, atypical vesicular nuclei, and mitotic figures (arrow).
(A) hematoxylin and eosin, 4.4 ×;
(B) hematoxylin and eosin, 146.1 ×;
(C, D) immunohistochemistry showing hallmarks of B-cell lymphoma:
(C) membranous positivity of CD20 in large atypical cells (53.7×),
(D) CD138 (59.1×) stains only admixed plasma cells, large cells are negative.
Obr. 2. Histologické snímky ukazující kostní dřeňové prostory difúzně infiltrované hojnými velkými nekohezivními buňkami s málo objemnou cytoplazmou, atypickými měchýřkovitými jádry, s mitotickou aktivitou (šipka).
(A) hematoxylin eosin, 4,4 ×;
(B) hematoxylin eosin, 146,1 ×;
(C, D) imunohistochemie se znaky B-buněčného lymfomu:
(C) membránová pozitivita CD20 ve velkých atypických buňkách (53,7×),
(D) CD138 (59,1×) barví jen příměs plazmatických buněk, velké buňky jsou negativní.

we present a rare case of a female patient with primary DLBCL of the parietal bone.

70-year-old Caucasian woman presented with a palpable slightly painful induration on the calva. The lesion was found in a control PET scan performed due to breast carcinoma in the patient`s history. The subtype of breast carcinoma was not known at the recent presentation. The patient underwent a right-sided mastectomy and combined adjuvant radiotherapy, hormonal therapy, and chemotherapy with doxorubicine and endoxan because of mammary carcinoma resected 14 years prior to recent presentation. The PET/CT and MRI showed a focal lesion in the left parietal bone with markedly increased accumulation of 2-deoxy-2-(^{18}F)--fluoro-D-glucose without signs of intracranial propagation. There was an infiltrative focus measuring 32 × 28 × 12 mm in the left paramedial vertex region on the CT scan (Fig. 1). At presentation, the blood count, serum biochemistry, and viral hepatitis serology showed no significant pathological findings. The patient was referred to undergo a neurosurgical resection of the skull lesion. The left parietal part of the pathologically altered skull was resected. The dura mater was not infiltrated with the tumorous mass. The bone defect was immediately substituted with cranioplasty using Palacos material (Heraeus, Wehrheim, Germany). No severe complications occurred during surgery. The sample of bone measuring 20 × 15 × 14 mm was sent for a standard histopathological examination. The bone tissue was formalin-fixed, decalcified in formic acid, and paraffin-embedded.

Microscopically, we saw bone tissue with thickened bony trabeculae. Marrow spaces were filled up with diffuse infiltration consisting of large non-cohesive closely packed cells with frank cytonuclear atypia, vesicular nuclei, and multiple nucleoli focally with a single prominent nucleolus. The atypical cell population displayed numerous mitoses accounted for approx. 5 mitotic figures per 1 high power field (Fig. 2). The tumor infiltration was partly necrotic with leukocytes. An immunohistochemical examination was performed. The tumor cells were negative in cytokeratin 7, GATA 3, cytokeratin 20, S100 protein, and a cluster of differentiation 138 (CD138), but there was an unequivocal positivity in common leukocyte antigen (LCA seu CD45), which led to a suspicion of lymphoma. Further detection of CD79a, CD20, BCL6, and CD30 (in approx. 40% of tumor cells) was noted (Fig. 2). The rest of the examined markers – cyclin D1,

prolékaře.cz | 24.4.2024

CD23, CD10, transcriptional factor multiple myeloma 1 (MUM1), and CD5 – were negative. The BCL2, C-MYC, and Ki67 immunohistochemistry had no positive reaction: we interpret this as false negative probably caused by formic acid decalcification artifacts. The histological and immunohistochemical findings lead to the diagnosis of DLBCL with germinal-center (GC)-like immunophenotype and partial CD30 positivity.

Based on the diagnosis of DLBCL of the skull, a restaging PET/CT and staging bone-marrow trephine biopsy of the iliac bone were performed. Except for changes following craniotomy, the restaging PET/CT showed metabolic and morphological progression in the left-sided skull lesion. Recently, several smaller hypermetabolic foci in the contralateral parietal and frontal bone occurred. There were no further significant hypermetabolic foci in the skeleton or in the viscera including lymph nodes. The bone marrow biopsy, smear cytology, and flow cytometry were free of lymphoma involvement. The lymphoma was stage IIE according to Lugano classification. Based on all of the findings mentioned above, the patient was referred to standard combined therapy. The patient underwent 6 cycles of R-CHOP (rituximab, cyclophosphamide, doxorubicin, vincristine, and prednisolone), 2 administrations of rituximab and 3 intrathecal metothrexate administrations as CNS prophylaxis. Eight months after diagnosis, there was a full regression of the clinical and radiological findings.

Concerning PBL of the skull, there are several references about lymphoma arising at the skull base, usually affecting elderly patients [2], clinically presenting with diplopia, trigeminal hyperesthesia, headache, facial nerve lesion, B-symptoms, and hearing loss. The onset is usually abrupt [2]. Concerning lymphomas of the cranial vault, there are references mostly describing B-cell non-Hodgkin lymphomas including all of the subcutaneous, bone, and intracranial lesions [3–7], with a palpable or painful mass as the main clinical symptom. A subset of cranial vault B-lymphomas was associated with HIV infection [4]. There was no suspicion of HIV in our case.

Radiologically, the differential diagnosis of cranial vault PBL includes meningioma, granulomatous and malignant osteolytic processes, i.e., multiple myeloma, metastatic carcinoma, melanoma, or sarcoma. The key to proper diagnosis is surgical biopsy and appropriate immunohistochemistry. DLBCL has a growth pattern with an incohesive dense diffuse population of atypical cells; some of them may contain cells with immunoblastic appearance that encumber distinction from plasmacytic bone tumors [1]. An accurate histological diagnosis of large cell lymphomas of bone may be difficult because of the accompanying abundant fibrosis with osteoid formation, decalcification and crush artifacts, and observations that the large lymphoma cells may form small clusters that resemble carcinoma. Thus, an immunohistochemical study is required to establish the accurate diagnosis of primary DLBCL in bone.

In comparison with the other primary malignant bone tumors including sarcomas and multiple myeloma, DLBCL has a favorable prognosis. The 5-year cause-specific survival was 96% [8]. The progression free survival was 83% at 4 years [9]. Moreover, there is a trend towards improved outcome with the addition of targeted anti-CD20 therapy with rituximab; most PBL cases are of the GC-like phenotype harboring a favorable prognosis [10].

In conclusion, we report a very rare case of a primary DLBCL arising in the cranial vault as a rare differential diagnostic alternative of a much more common plasmocytic myeloma or metastatic carcinoma. Cranial vault lymphomas have a favorable prognosis compared to other skull malignancies.

Ethical principles

This work was performed in line with institutional ethical standards. The text and figures do not contain any person identifying information.

Financial support

This work was supported by the Charles University research program PROGRES Q 28 (Oncology). The fund covers all institution publications related to oncology.

Conflict of interest

The authors declare they have no potential conflicts of interest concerning drugs, products, or services used in the study.

References

1. Cleven AHG, Ferry JA. Primary non-Hodgkin lymphoma of bone. In: WHO Classification of Tumours Editorial Board. Soft tissue and bone tumours. Lyon (France): International Agency for Research on Cancer 2020: 489–491.

2. Marinelli JP, Modzeski MC, Lane JI et al. Primary skull base lymphoma: manifestations and clinical outcomes of a great imitator. Otolaryngol Head Neck Surg 2018; 159(4): 643–649. doi: 10.1177/0194599818773994.

3. Thurnher MM, Rieger A, Kleibl-Popov C et al. Malignant lymphoma of the cranial vault in an HIV-positive patient: imaging findings. Eur Radiol 2001; 11(8): 1506–1509. doi: 10.1007/s003300000754.

4. Duyndam DA, Biesma DH, van Heesewijk JP. Primary non-Hodgkin's lymphoma of the cranial vault; MRI features before and after treatment. Clin Radiol 2002; 57(10): 948–950. doi: 10.1053/crad.2002.1062.

5. Chan DY, Chan DTM, Poon WS et al. Primary cranial vault lymphoma. Br J Neurosurg 2018; 32(2): 214–215. doi: 10.1080/02688697.2016.1226262.

6. El Asri AC, Akhaddar A, Baallal H et al. Primary lymphoma of the cranial vault: case report and a systematic review of the literature. Acta Neurochir (Wien) 2012; 154(2): 257–265. doi: 10.1007/s00701-011-1124-0.

7. Kanaya M, Endo T, Hashimoto D et al. Diffuse large B-cell lymphoma with a bulky mass in the cranial vault. Int J Hematol 2017; 106(2): 147–148. doi: 10.1007/s12185-017-2229-x.

8. Beal K, Allen L, Yahalom J. Primary bone lymphoma: treatment results and prognostic factors with long-term follow-up of 82 patients. Cancer 2006; 106(12): 2652–2656. doi: 10.1002/cncr.21930.

9. Alencar A, Pitcher D, Byrne G et al. Primary bone lymphoma – the University of Miami experience. Leuk Lymphoma 2010; 51(1): 39–49. doi: 10.3109/10428190903308007.

10. Heyning FH, Hogendoorn PC, Kramer MH et al. Primary lymphoma of bone: extranodal lymphoma with favourable survival independent of germinal centre, post-germinal centre or indeterminate phenotype. J Clin Pathol 2009; 62(9): 820–824. doi: 10.1136/jcp.2008.063156.