

Treatment of a large supraclinoid aneurysm via clipping with a prophylactic low-flow bypass

Léčba velkého supraklinoidního aneuryzmatu pomocí klipu s profylaktickým nízkoprůtokovým bypassem

Dear editorial office,

Large supraclinoid aneurysms can cause visual deficits by two mechanisms: direct compression of the optic nerve or rarely by ischemic stroke due to embolization. In our case, direct clipping of a large ventral carotid wall aneurysm resulted in an immediate decompression of visual pathways and eliminated the source of embolization. Furthermore, due to a positive balloon occlusion test (BOT), a prophylactic bypass was performed in order to protect the brain from ischemia during temporary clipping of the internal carotid artery (ICA) using three fenestrated clips.

Rhoton's simple classification describes only 4 ICA segments: C1 cervical, C2 petrous, C3 cavernous, and C4 supraclinoid. Supraclinoid aneurysms (C4) are defined as intradural aneurysms of the ICA, which arise between the distal dural ring and the terminal carotid bifurcation. Lawton categorized these lesions of the paraclinoid (supraclinoid) region in more detail as ophthalmic, superior hypophyseal, and variant aneurysms. Variant aneurysms include dorsal carotid, carotid cave, clinoid segment, and ventral carotid aneurysms [1].

A 62-year-old male suffered from an ischemic stroke in 2014, presenting with visual impairment. Brain CT showed a hyperdense lesion in the paraclinoid region on the right side with several calcifications surrounding the lesion. No subarachnoid hemorrhage was present. A diffusion-weighted imaging MRI (DWI-MRI) identified an acute ischemic lesion in the temporo-parietal region. A visual field examination confirmed inferior contralateral quadrantanopia. Three years later, the patient suffered from the second ischemic episode. MRA was performed showing a complex paraclinoid aneurysm with an inferiorly directed fundus and a wide neck (11 × 15 × 14 mm), 2 mm distal to the

origin of the ophthalmic artery (Fig. 1). The visual field examination showed signs of the inferior right optic nerve compression in addition to the original findings.

Further examinations excluded other causes of stroke such as carotid artery stenosis or cardiogenic embolism. After discussing the case with the neurovascular team, a patient consensus was reached to treat the lesion using a microsurgical technique allowing a direct decompression of the visual pathway as well as concurrently eliminating the source of embolization. The patient first underwent a BOT, which showed insufficient collateral flow thus confirming the need for a prophylactic bypass during the anticipated temporary clipping of the cervical carotid artery during the intended tandem angled fenestrated clipping procedure. Due to the favorable distal location of the sac, we did not anticipate the need for permanent carotid occlusion and therefore we did not even consider the preparation of a bypass with a higher flow rate.

During surgery, the cervical ICA was first exposed to obtain proximal control. Secondly, dissection of the superficial temporal artery (STA) was performed, along with a pterional craniotomy and anastomosis of the parietal branch of the STA with an M4 segment branch of the right middle cerebral artery (MCA). In the next step, temporary clipping of the ICA in the cervical portion was performed for 5 min in order to decrease flow in the aneurysm and simultaneously to allow flow from the external carotid artery to the STA-MCA anastomosis. Dissection of the aneurysm revealed evident direct compression of the right optic nerve. Finally, 3 tandem right-angled fenestrated clips (placed heel to toe, all in the same direction) were applied to the neck of the aneurysm. Transcranial Doppler as well as indocyanine green verified the pos-

The Editorial Board declares that the manuscript met the ICMJE "uniform requirements" for biomedical papers.

Redakční rada potvrzuje, že rukopis práce splnil ICMJE kritéria pro publikace zasílané do biomedicínských časopisů.

I. Concepción^{1,2}, A. Hejčl^{1,3,4}, J. Lodin¹, M. Sameš¹

¹ Department of Neurosurgery, University J. E. Purkyně, Masaryk Hospital, Ústí nad Labem, Czech Republic

² Department of Neurosurgery, Complejo Hospitalario Metropolitano Dr. Arnulfo Arias Madrid, Panamá, Panama

³ International Clinical Research Center, St. Anne's University Hospital, Brno, Czech Republic

⁴ Institute of Experimental Medicine, Academy of Sciences of the Czech Republic, Prague, Czech Republic



Prof. Martin Sameš, MD, Csc.
Department of Neurosurgery
University J. E. Purkyně,
Masaryk Hospital
Sociální péče 3316
400 11 Ústí nad Labem
Czech Republic
e-mail: martin.sames@kzcr.eu

Accepted for review: 9. 12. 2020

Accepted for print: 20. 5. 2021

terior communicating artery and choroidal artery flow. Postoperative CTA (Fig. 2) confirmed successful occlusion of the aneurysm without a visible remnant. No new infarctions were apparent on the CT scan and the patient had no new visual or motor deficits. The postoperative course was uneventful as the patient quickly improved and was

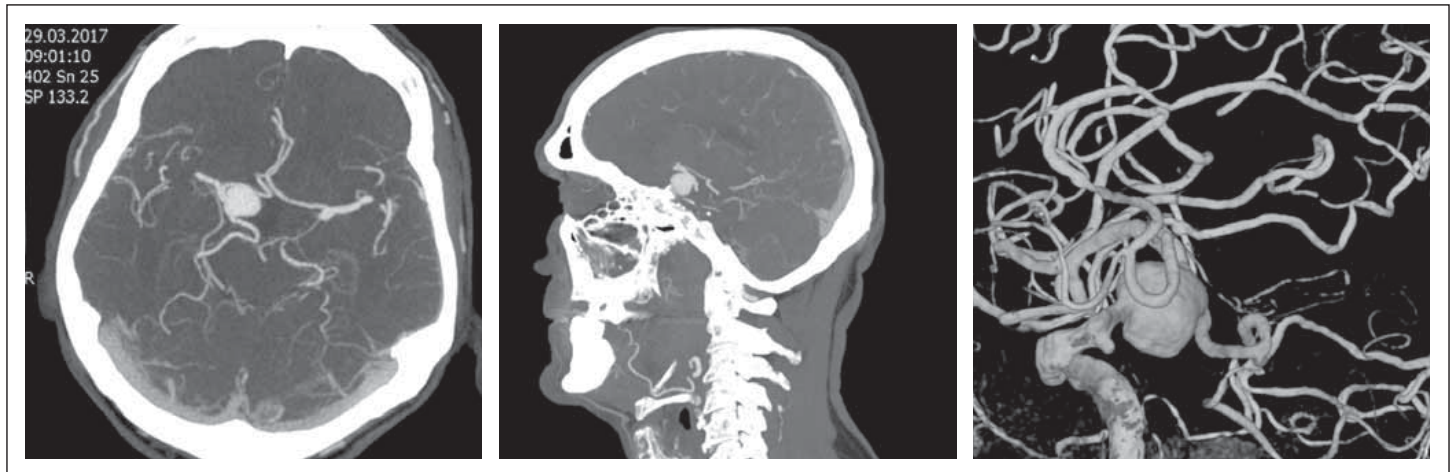


Fig. 1. Preoperative CTA and DSA. Complex ventral carotid wall aneurysm ($11 \times 15 \times 14$ mm) on the right 2 mm distal to the origin of the ophthalmic artery and involving the posterior communicating segment of the internal carotid artery with a fetal-type posterior communicating artery arising from the aneurysm sac. The anterior choroidal artery was distal to the aneurysm.

Obr. 1. Předoperační CTA a DSA. Komplexní aneurysma ventrální stěny karotidy ($11 \times 15 \times 14$ mm) umístěné vpravo 2 mm distálně od odstupu arteria ophthalmica a zahrnující zadní komunikující segment arteria carotis interna a arteria communicans posterior fetálního typu, odstupující přímo z vaku aneurysmatu. Arteria chorioidea anterior odstupuje distálně od výdutě.

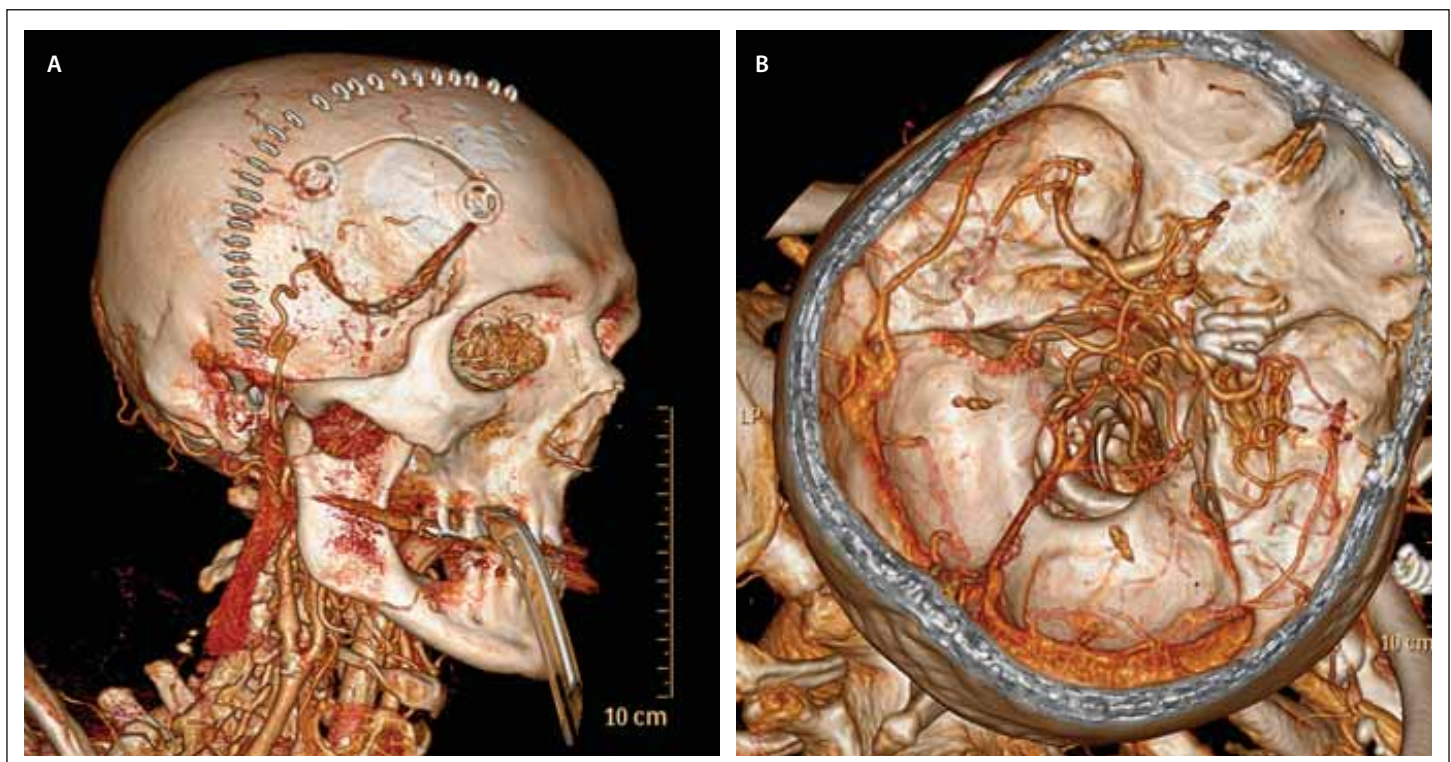


Fig. 2. Postoperative 3D CTA. (A) The STA-MCA prophylactic bypass is apparent. (B) Three tandem fenestrated clips were used to exclude the aneurysm from circulation.

MCA – middle cerebral artery; STA – superficial temporal artery

Obr. 2. Pooperační 3D CTA. (A) Profylaktický STA-MCA bypass. (B) Tři tandemové fenestrované klipy byly aplikovány k vyřazení aneurysmatu z oběhu.

MCA – arteria cerebri media; STA – arteria temporalis superficialis

promptly released. One year after the procedure, CTA was performed – without residue or recurrence of the aneurysm. Two years after clipping, the patient's visual field deficit was only affected by the ischemic event.

The most common presentation of this group of unruptured aneurysms is the visual disturbance due to a direct compression of the optic pathway. However, in rare cases, a giant thrombosed aneurysm may present

with ischemic stroke due to embolization. In our patient, the visual field was initially affected by an ischemic lesion of the optic radiation and later, in 2017, his vision was affected by a direct compression of the optic

nerve by the aneurysm sac. Calviere et al have suggested that unruptured intracranial artery aneurysms can be revealed by cerebral ischemia [2].

The treatment of large and giant paraclinoid aneurysms has always been a challenge in neurovascular practice. In recent years, the use of endovascular techniques utilizing flow diverters (FD) and coils has become increasingly popular [3]. However, the rate of post-operative visual improvement was significantly lower among patients treated with coiling compared to those treated with FD or clipping [3]. In the meta-analysis performed by Touze et al, the overall aneurysm occlusion rate of cases treated with a flow diverter was 85% [4]. Occurrence of ophthalmic complications after FD deployment varies in the literature from 0 to 39.1%. In the same meta-analysis, the authors describe an overall rate of ophthalmic artery patency of 90%. The main reported ophthalmic complications include retinal emboli, visual field defects, amaurosis fugax [4], and optic nerve ischemic atrophy [5]. These may be related to small emboli released from the stent, from modified blood flow in the ophthalmic artery after FD placement, or due to the insufficient blood flow from external carotid artery collaterals supplying the occluded ophthalmic artery [4,5]. These devices are relatively new in the management of these complex aneurysms, and the rate and management of complications is just beginning to be understood [6].

On the other hand, surgical clipping has the advantage of an immediate aneurysm

deflation and optic nerve decompression resulting in visual improvements and high rates of aneurysm occlusion [7]. Orlický et al also concluded that aneurysms with visual dysfunction should be treated surgically within three months of symptom manifestation if possible. [7]. Microsurgery offers the advantage of durability, with a long-term recurrence rate of less than 5% compared to 20% in cases of endovascular treatment. Although endovascular intervention is likely safer for many patients, microsurgery is an option for those with symptomatic optic apparatus compression, young age, and an aneurysm location minimally complicated by skull base anatomy [8]. Cohen-Gadol published an occlusion rate of 91%, a recurrence rate of 3.1%, ophthalmic artery patency of 99.5%, and good clinical outcomes (modified Rankin scale 0–2) in 96.2% of cases [8]. Similar results have been described in other studies [9,10].

Revascularization techniques are helpful for giant supraclinoid aneurysms especially in cases with a positive BOT, suggesting insufficient collateral blood flow. In our case report, we did not consider flow replacement and permanent carotid occlusion as the nature of the aneurysm allowed a direct clipping. A key decision was the use of the prophylactic bypass to protect the brain during a temporary cervical ICA clipping.

Financial support

The study was supported by grant No. 17-32872A from the Czech Health Research Council (AZVČR).

Conflict of interest

The authors declare they have no potential conflicts of interest.

References

1. Lawton M. Seven aneurysms. Tenets and technique for clipping. New York: Stuttgart Thieme 2011.
2. Calviere L, Viguiere A, Da Silva NA et al. Unruptured intracranial aneurysm as a cause of cerebral ischemia. *Clin Neurol Neurosurg* 2011; 113(1): 28–33. doi: 10.1016/j.clineuro.2010.08.016.
3. Silva M, See A, Khandelwal P et al. Comparison of flow diversion with clipping and coiling for the treatment of paraclinoid aneurysms in 115 patients. *J Neurosurg* 2019; 130: 1505–1512. doi: 10.3171/2018.1.JNS171774.
4. Touzé R, Gravelier B, Rolla-Bigliani C et al. Occlusion rate and visual complications with flow-diverter stent placed across the ophthalmic artery's origin for carotid-ophthalmic aneurysms: a meta-analysis. *Neurosurgery* 2020; 86(4): 455–463. doi: 10.1093/neuros/nyz202.
5. Rouchaud A, Leclerc O, Benayoun Y et al. Visual outcomes with flow-diverter stents covering the ophthalmic artery for treatment of ICA aneurysms. *AJNR Am J Neuroradiol* 2015; 36(2): 330–336. doi: 10.3174/ajnr.A4129.
6. Al-Mufti F, Cohen E, Amuluru K et al. Bailout strategies and complications associated with the use of flow-diverting stents for treating intracranial aneurysms. *Intervent Neurol* 2019; 8(1): 38–54. doi: 10.1159/000489016.
7. Orlický M, Sameš M, Hejčl A et al. Carotid-ophthalmic aneurysms – our results and treatment strategy. *Br J Neurosurg* 2015; 29(2): 237–242. doi: 10.3109/02688697.2014.976176.
8. Cohen-Gadol A. Revascularization, low-flow and high revascularization. *Neurosurgical Atlas. Vascular volume* [online]. Available from URL: <https://doi.org/10.18791/nsatlas.v3.ch05.2>.
9. Kamide T, Tabani H, Safaee M et al. Microsurgical clipping of ophthalmic artery aneurysms: surgical results and visual outcomes with 208 aneurysms. *J Neurosurg* 2018; 129(6): 1511–1521. doi: 10.3171/2017.7.JNS17673.
10. Matano F, Tanikawa R, Kamiyama H et al. Surgical treatment of 127 paraclinoid aneurysms with multifarious strategy: factors related with outcome. *World Neurosurg* 2016; 85: 169–176. doi: 10.1016/j.wneu.2015.08.068.