

Polymorphous low-grade neuroepithelial tumor of the young

Polymorfní low-grade neuroepiteliální tumor mladých

Dear editors,

Hereby we would like to present a case report of a 27-year-old male patient with drug-resistant structural epilepsy based on the diagnosis of the polymorphous low-grade neuroepithelial tumor of the young (PLNTY), first reported by Huse et al in 2017 [1]. PLNTY is a sporadic epileptogenic tumor characterized by an oligodendroglial-like component, diffuse CD34 expression, and alteration of the mitogen-activated protein (MAP) kinase signaling pathway. It shares multiple characteristics with other diffuse low-grade gliomas, especially with oligodendroglioma; nevertheless, its distinction is crucial because of the favorable prognosis of PLNTY.

The patient reported the first focal to bilateral tonic-clonic seizure (FBTCS) at the age of 23 years. At that time, medication with levetiracetam was introduced, which was subsequently switched to lamotrigine because of side-effect (hallucinations). The medication was completely stopped after 2 years of seizure freedom. After 1 year, the seizures recurred. The patient reported FBTCS without any aura. He experienced postictal confusion, sleepiness, agitation and aphasia. The initial CT scan displayed a subtle right parietal lobe lesion with calcifications corresponding to the expected epileptogenic focus area. The following MRI revealed a heterogeneous subcortical lesion in the right

postcentral gyrus suggestive of cavernoma (Fig. 1). The patient was indicated for surgery consisting of lesionectomy. The intraopera-

The Editorial Board declares that the manuscript met the ICMJE "uniform requirements" for biomedical papers.

Redakční rada potvrzuje, že rukopis práce splnil ICMJE kritéria pro publikace zasílané do biomedicínských časopisů.

**M. Hendrych¹, J. Hemza²,
J. Kočvarová³, E. Pešlová³,
D. Sochůrková², I. Doležalová³,
E. Brichtová², M. Pail³, M. Brázdil³,
R. Jančálek², J. Vaníček⁴,
M. Hermanová¹**

¹ First Department of Pathology, Faculty of Medicine, Masaryk University, St. Anne's University Hospital Brno, Czech Republic

² Department of Neurosurgery, Faculty of Medicine, Masaryk University, St. Anne's University Hospital Brno, Czech Republic

³ Brno Epilepsy Center, Department of Neurology, Faculty of Medicine, Masaryk University, St. Anne's University Hospital Brno, Czech Republic

⁴ Department of Medical Imaging, Faculty of Medicine, Masaryk University, St. Anne's University Hospital, Czech Republic



Michal Hendrych, MD
First Department of Pathology
Faculty of Medicine
Masaryk University
St. Anne's University Hospital
Pekařská 53
656 91 Brno
Czech Republic
e-mail: michal.hendrych@fnusa.cz

Accepted for review: 22. 3. 2021

Accepted for print: 5. 5. 2021

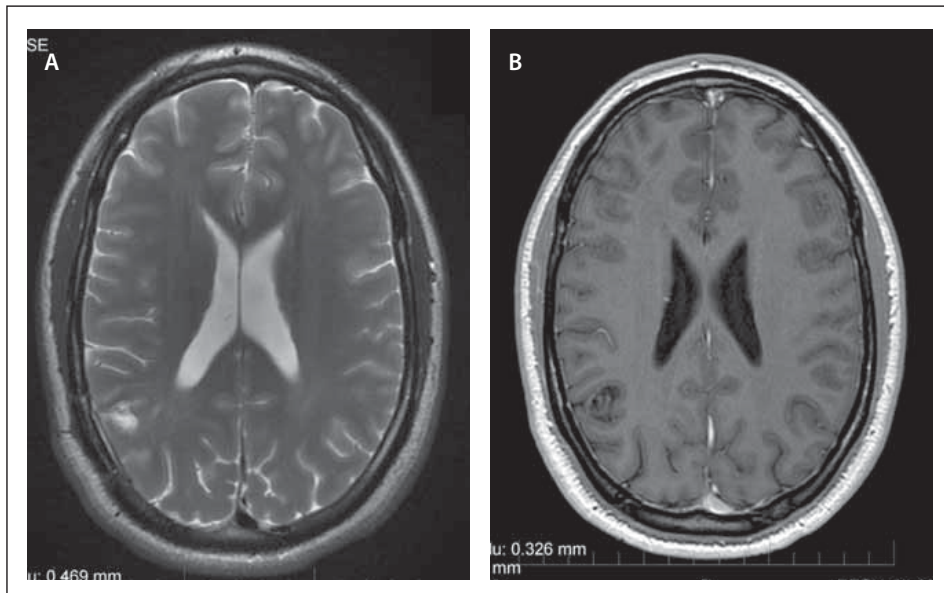


Fig. 1. MRI findings of the polymorphous low-grade neuroepithelial tumor of the young. (A) T2-weighted axial image with a hyperintensity in the right parietal lobe and no collateral edema.

(B) Postcontrast T1-weighted axial image shows a non-enhancing lesion in the right parietal lobe.

Obr. 1. Vyšetření MR s nálezem polymorfního low-grade neuroepiteliálního tumoru mladých.

(A) T2-vážený axiální snímek s hyperintenzitou v pravém parietálním laloku bez kolaterálního edému.

(B) Postkontrastní T1-vážený axiální snímek zobrazující nesytící se lézi v pravém parietálním laloku.

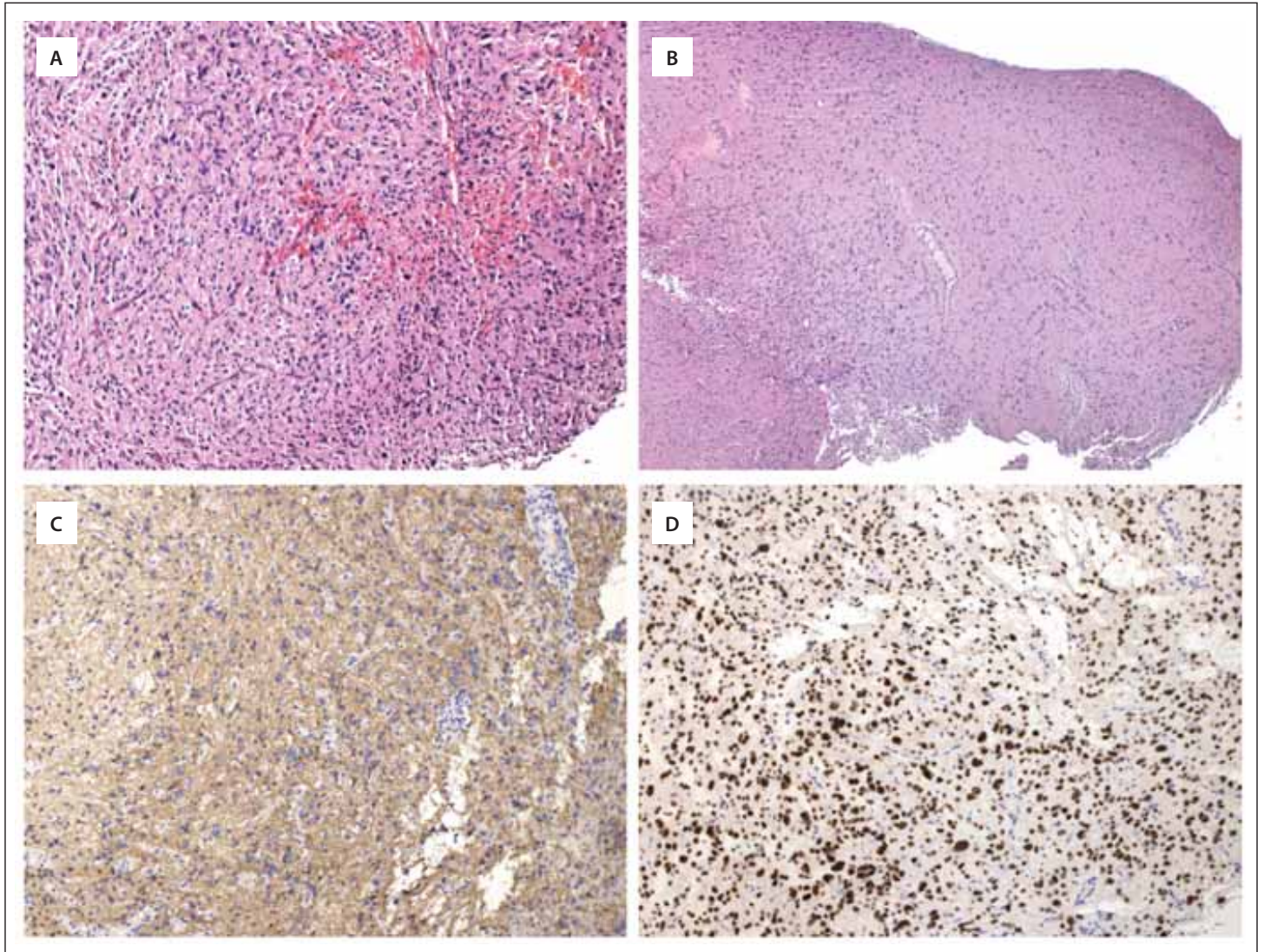


Fig. 2. Histological and immunohistochemical analysis of polymorphous low-grade neuroepithelial tumor of the young.

(A) Oligodendroglia-like tumor cells growing in a web of branching capillaries. Hematoxylin-eosin, original magnification 100x.

(B) Tumor periphery demonstrating diffuse type of growth with secondary structures – perineuronal satellitosis and perivascular accumulation. Hematoxylin-eosin, original magnification 40x.

(C) Immunohistochemical expression of GFAP in tumor cells. Original magnification 100x.

(D) Positive nuclear expression of OLIG2. IHC, original magnification 100x.

GFAP – glial fibrillary acidic protein; IHC – immunohistochemistry; OLIG2 – oligodendrocyte transcription factor 2

Obr. 2. Histologické a imunohistochemické vyšetření polymorfního low-grade neuroepiteliálního tumoru mladých.

(A) Proliferace nádorových buněk oligodendroglální morfologie rostoucí v síti větvičích se kapilár. Hematoxylin-eosin, originální zvětšení 100x.

(B) Okraj nádorové fronty se zastiženými sekundárními znaky difúzního šíření nádoru – perineuronální satelitóza a perivaskulární šíření. Hematoxylin-eosin, originální zvětšení 40x.

(C) Imunohistochemicky vyšetřená exprese GFAP v nádorových buňkách. Originální zvětšení 100x.

(D) Pozitivní jaderná exprese OLIG2. IHC, originální zvětšení 100x.

GFAP – gliální fibrilární kyselý protein; IHC – imunohistochemie; OLIG2 – transkripční faktor oligodendrocytů 2

tive pre-resection electrocortigraphy with subdural grid confirmed prominent spikes above the lesion. After gross-total resection, the electrocortigraphy around the post-resection cavity exhibited a normal brain activity. The results of the histopathology analyses described below revealed PLNTY. During a 6-month follow-up, the patient has

been seizure-free, and the MRI did not show tumor recurrence.

The standard histopathological examination of routinely processed formalin-fixed paraffin-embedded tumor tissue was performed. Microscopical evaluation presented a neoplasm formed exclusively by oligodendroglia-like cells featuring small round

nuclei with perinuclear halos set in a network of branching “chicken-wire” capillaries (Fig. 2A). The tumor cells exhibited diffuse growth with secondary structures at the tumor periphery – perineuronal satellitosis and perivascular spread (Fig. 2B). No gemistocytes, piloid astrocytes, Rosenthal fibers, or eosinophilic globular bodies were de-

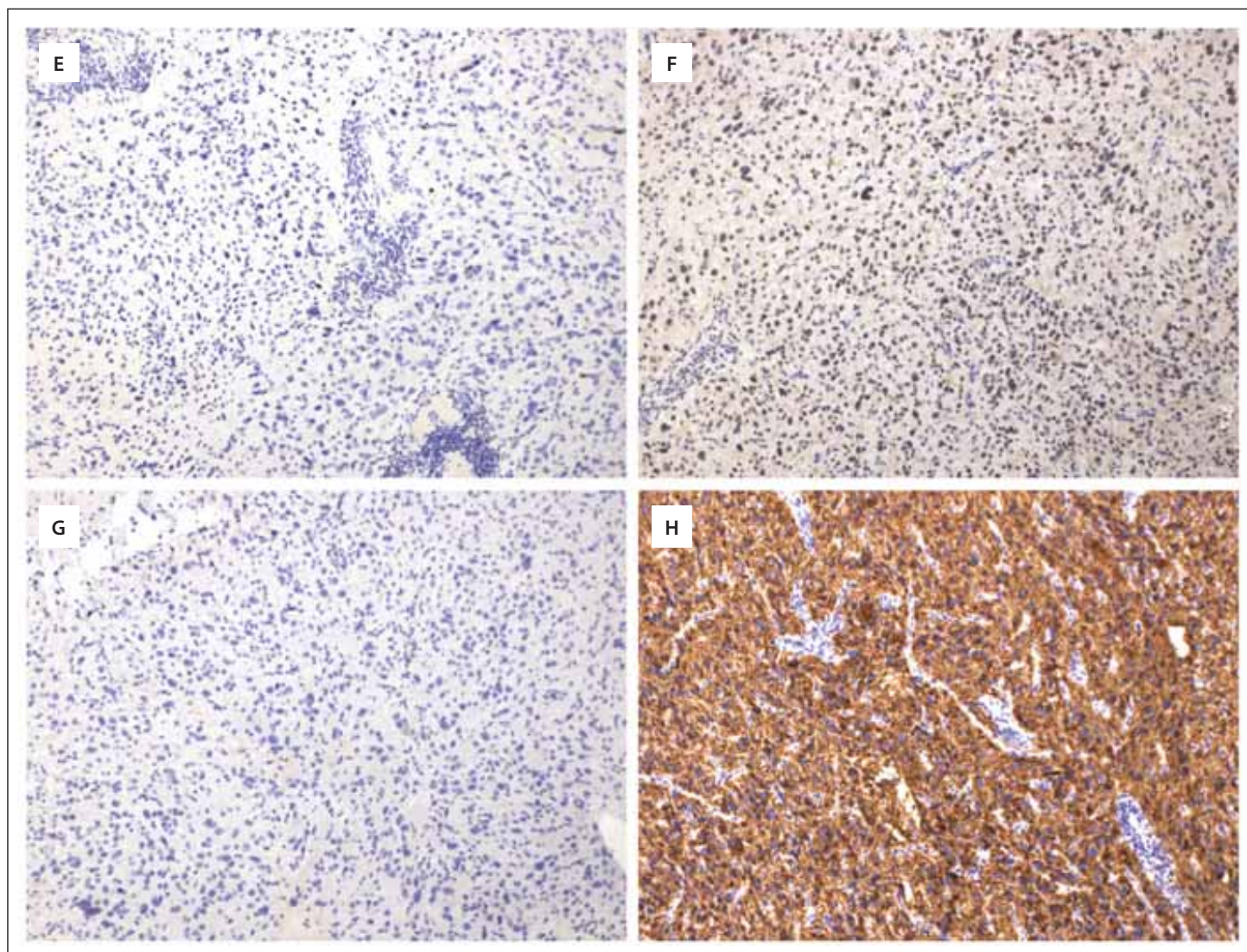


Fig. 2 – continuing. Histological and immunohistochemical analysis of polymorphous low-grade neuroepithelial tumor of the young.

(E) Proliferation index Ki-67 in hotspots reached up to 1%. IHC, original magnification 100x.

(F) Immunohistochemically wildtype nuclear expression of ATRX was detected. Original magnification 100x.

(G) Immunohistochemical examination did not confirm R132H-mutation in *IDH1* gene. Original magnification 100x.

(H) Strong diffuse positivity of CD34. IHC, original magnification 100x.

ATRX – ATP-dependent helicase ATRX, X-linked; IDH1 – isocitrate dehydrogenase 1; IHC – immunohistochemistry

Obr. 2 – pokračování. Histologické a imunohistochemické vyšetření polymorfního low-grade neuroepiteliálního tumoru mladých.

(E) Proliferační index Ki-67 dosahuje maximálně do 1 %. IHC, originální zvětšení 100x.

(F) Imunohistochemicky byla detekována wildtype jaderná exprese ATRX. Originální zvětšení 100x.

(G) Imunohistochemické vyšetření neprokázalo přítomnost mutace R132H v genu *IDH1*. Originální zvětšení 100x.

(H) Silná difúzní exprese CD34. IHC, originální zvětšení 100x.

ATRX – ATP závislá helikáza ATRX, X-vázaná; IDH1 – izocitrát dehydrogenáza 1; IHC – imunohistochemie

tected. Neither foci of necrosis nor vascular proliferation were present. Only one mitosis was identified in the entire resected tumor specimen. The histological picture was highly suggestive for a tumor from the diffuse glioma's category, especially for oligodendroglioma. According to the integrated diagnostics criteria of WHO classification, the implementation of adequate immunohistochemical analysis (IHC) and genetic testing are required. The initial IHC

examination confirmed strong diffuse positivity for both glial markers – glial fibrillary acidic protein (GFAP) (Fig. 2C) and oligodendrocyte transcription factor 2 (OLIG2) in neoplastic oligodendroglia-like cells (Fig. 2D). The proliferation activity of Ki-67 was negligible, below 1% (Fig. 2E). The nuclear expression of alpha-thalassemia/mental retardation, X-linked (ATRX), was retained (Fig. 2F) and the tumor cells presented with a wild-type expression of p53. The neoplastic cells

did not express R132H-mutant isocitrate dehydrogenase 1 (IDH1) (Fig. 2G), thus the presence of *IDH1/2* mutations was examined by polymerase chain reaction (PCR) sequencing, which did not detect any mutations in *IDH1/2* genes, and the tumor was classified as IDH wild-type. The fluorescence in situ hybridization detection of 1p/19q codeletion was negative too, which excluded the diagnosis of oligodendroglioma. Further IHC examination displayed a diffuse and strong

CD34 positivity (Fig. 2H) and complete absence of epithelial membrane antigen (EMA) expression in the tumor cells, consistent with the diagnosis of PLNTY. The following quantitative PCR analysis detected B-Raf proto-oncogene, and serine/threonine kinase (*BRAF*) *V600E* mutation supporting the final diagnosis.

The previous case series described the association of PLNTY with early-onset pharmacoresistant epilepsy in children or young adults aged 4 to 34 years [1]. Nevertheless, the typical age range has not been established yet because a case report of a 57-year-old male without seizure history was published [2]. PLNTY can be described on MRI as a well-circumscribed lesion mainly in the cortical or subcortical areas with calcifications and possible cystic components. The minority of published cases demonstrated post-gadolinium contrast enhancement, and none was associated with significant mass effect or edema [3]. As PLNTY has a non-specific MRI pattern, the radiological diagnoses ranged from diffuse glioma, pilocytic astrocytoma, dysembryoplastic neuroepithelial tumor (DNET), and pleomorphic xanthoastrocytoma to focal cortical dysplasia [1,3,4].

PLNTYs are histologically quite heterogeneous neoplasms characterized by diffuse growth pattern and are formed, at least focally, by cells with oligodendroglia-like morphology alternating with astrocytic morphology or even pseudorosettes. Calcifications are a common feature, on the contrary to necrotic foci, microvascular proliferations, Rosenthal fibers, and eosinophilic granular bodies. The tumor cells diffusely express GFAP, OLIG2, and CD34, while the expression of EMA, Neu-N or chromogranin are absent. The tumor cells also lack mutations in *IDH1* and *IDH2* genes and do not exhibit evidence for the codeletion of 1p/19q, both of which being the genetic alterations in the diagnostics of oligodendroglioma [1,5].

The described cases of PLNTYs harbored either *BRAF* alteration such as *BRAF V600E* mutation or *BRAF* fusion or other genomic events affecting *FGFR2*, *FGFR3*, or *NTRK2* including *FGFR3-TACC3* fusion, *FGFR3* amplification, *FGFR2-CTNNA3* fusion, *FGFR2-INA* fusion, *FGFR2-KIAA1598* fusion, *FGFR2* rearrangement, and *NTRK2* disruption. These genetic alterations occurred in almost all PLNTYs in a mutually exclusive fashion, supporting the notion that the dysregulated MAP kinase signaling drives their oncogenesis. Therefore, targeting the MAP kinase signaling may become a promising therapeutic strategy in unresectable cases [6]. Furthermore, the genome-wide methylation profiling revealed a distinct methylation signature suggesting that they are, in fact, distinct biologic entities closely related to other long-term epilepsy-associated tumors (LEATs), such as ganglioglioma, DNET, and pilocytic astrocytoma [1]. LEATs frequently occur during brain development and are sometimes associated with focal cortical dysplasia (FCD IIIb) [7,8]. Like for other LEATs, a case report of PLNTY associated with focal cortical dysplasia (FCD IIIb) has already been published [9].

PLNTY has been classified as a WHO grade 1 tumor, despite the infiltrative growth pattern characteristic for grade 2 tumors. The WHO grade 1 designation is justified mainly by its negligible proliferation activity, insignificant mitotic activity, and minimal recurrence rate. PLNTY also appears to be treated with gross-total resection [1–6,9]. However, a recent case report by Bale et al described the malignant transformation of PLNTY with *FGFR3-TACC3* fusion into glioblastoma [10]. Thus, a long-term follow-up as well as extensive clinical case series are warranted to precisely establish adequate grading.

Financial support

This work was supported by Masaryk University in Brno, Czech Republic, under Grant MUNI/A/1645/2020.

Conflict of interest

The authors declare they have no potential conflicts of interest concerning drugs, products, or services used in the study.

References

- Huse JT, Snuderl M, Jones DT et al. Polymorphous low-grade neuroepithelial tumor of the young (PLNTY): an epileptogenic neoplasm with oligodendroglioma-like components, aberrant CD34 expression, and genetic alterations involving the MAP kinase pathway. *Acta Neuropathologica* 2017; 133(3): 417–429. doi: 10.1007/s00401-016-1639-9.
- Riva G, Cima L, Villanova M et al. Low-grade neuroepithelial tumor: unusual presentation in an adult without history of seizures. *Neuropathology* 2018; 38(5): 557–560. doi: 10.1111/neup.12504.
- Johnson DR, Giannini C, Jenkins RB et al. Plenty of calcification: imaging characterization of polymorphous low-grade neuroepithelial tumor of the young. *Neuroradiology* 2019; 61(11): 1327–1332. doi: 10.1007/s00234-019-02269-y.
- Chen Y, Tian T, Guo X et al. Polymorphous low-grade neuroepithelial tumor of the young: Case report and review focus on the radiological features and genetic alterations. *BMC Neurology* 2020; 20(1): 123. doi: 10.1186/s12883-020-01679-3.
- Lelotte J, Duprez T, Raftopoulos C et al. Polymorphous low-grade neuroepithelial tumor of the young: case report of a newly described histopathological entity. *Acta Neurologica Belgica* 2020; 120(3): 729–732. doi: 10.1007/s13760-019-01241-0.
- Tateishi K, Ikegaya N, Udaka N et al. *BRAF V600E* mutation mediates FDG-methionine uptake mismatch in polymorphous low-grade neuroepithelial tumor of the young. *Acta Neuropathol Commun* 2020; 8(1): 139. doi: 10.1186/s40478-020-01023-3.
- Blumcke I, Aronica E, Urbach H et al. A neuropathology-based approach to epilepsy surgery in brain tumors and proposal for a new terminology use for long-term epilepsy-associated brain tumors. *Acta Neuropathologica* 2014; 128(1): 39–54. doi: 10.1007/s00401-014-1288-9.
- Blümcke I, Thom M, Aronica E et al. The clinicopathologic spectrum of focal cortical dysplasias: a consensus classification proposed by an ad hoc Task Force of the ILAE Diagnostic Methods Commission. *Epilepsia* 2011; 52(1): 158–174. doi: 10.1111/j.1528-1167.2010.02777.x.
- Gupta VR, Giller C, Kolhe R et al. Polymorphous Low-grade neuroepithelial tumor of the young: a case report with genomic findings. *World Neurosurgery* 2019; 132: 347–355. doi: 10.1016/j.wneu.2019.08.221.
- Bale TA, Sait SF, Benhamida J et al. Malignant transformation of a polymorphous low grade neuroepithelial tumor of the young (PLNTY). *Acta Neuropathologica* 2020; 141(1): 123–125. doi: 10.1007/s00401-020-02245-4.