proLékaře.cz | 28.11.2026

doi: 10.48095/cccsnn2021493

Meningeal Form of Rosai-Dorfman Disease

Meningeální forma Rosai-Dorfmanovy choroby

Dear Editors,

Let me introduce to you a case report of the meningeal form of Rosai-Dorfman disease (RDD). RDD (or sinus histiocytosis with massive lymphadenopathy), is a rare hematologic disease characterized by non-malignant proliferation and accumulation of a specific type of leukocytes (histiocytes), that primarily affects lymph nodes, but it can also affect most organ systems in the human body, including the CNS. This disease affects both males and females under the age of 20 [1]. The etiology remains unknown. Most common symptoms include painless enlargement of the lymph nodes; overall, symptoms, such as fever, paleness, weight loss or malaise, and other specific symptoms depend on the affected organ [2–4]. To confirm the diagnosis, it is always necessary to perform a biopsy of the affected tissue with a subsequent histological and immunohistochemical examination. The treatment is strictly individualized and mostly symptomatic. However, 70–80% of patients do not need specific treatment, only monitoring and the prognosis is good despite the damage of the tissues [5,6].

This case report deals with a 40-year-old man without history of chronic disease or medication. Since May 2017, he has been observing the loss of smell and taste and in addition, in mid-October, he began to observe impaired vision of the left eye (deterioration of visual acuity, the brightness and sensation of looking into the sun). According to the eye examination, both the reduction of visual acuity and the absolute scotoma in the left eye were discovered. In November, he was hospitalized at the Department of Neurology, University Hospital in Hradec Králové (UHHK) after the non-contrast brain CT, where extensive areas of vasogenic edema were described in both frontal and right temporal lobes (Fig. 1A). During the initial neurological examination, his clinical findings was normal, and he was only slightly euphoric. No significant pathological values were found in laboratory samples and on EEG. MRI confirmed multifocal opacifying lesions in the locations corresponding to the CT scan (Fig. 1B). Differential dia-

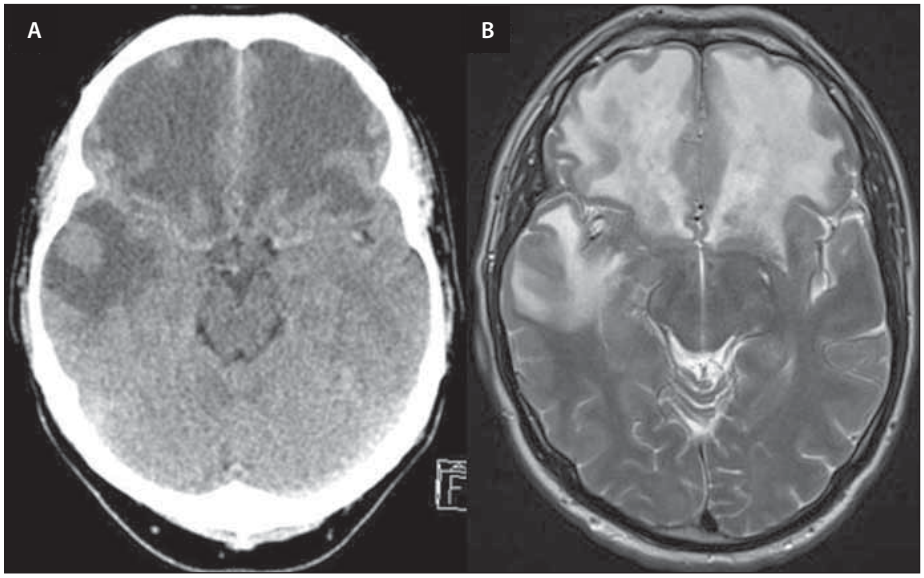

Fig. 1. (A) Non-contrast CT, (B) MRI, T2 weighted image – extensive areas of vasogenic edema in both frontal and the right temporal lobe.

Obr. 1. (A) Nativní CT, (B) MR, T2 vážený obraz – rozsáhlé oblasti vazogenního edému v obou frontálních a pravém temporálním laloku.

The Editorial Board declares that the manuscript met the ICMJE "uniform requirements" for biomedical papers.

Redakční rada potvrzuje, že rukopis práce splnil ICMJE kritéria pro publikace zasílané do biomedicínských časopisů.

O. Medek[1], P. Kašparová[2], M. Bartoš[3], B. Klímová[1], M. Vališ[1], T. Kupsa[4,5], J. M. Horáček[4,5], H. Medková[6]

[1] Department of Neurology, Faculty of Medicine of Charles University and University Hospital in Hradec Králové, Czech Republic
[2] Department of Pathology, Faculty of Medicine of Charles University and University Hospital in Hradec Králové, Czech Republic
[3] Department of Neurosurgery, Faculty of Medicine of Charles University and University Hospital in Hradec Králové, Czech Republic
[4] Department of Military Internal Medicine and Military Hygiene, University of Defense, Faculty of Military Health Sciences, Hradec Králové, Czech Republic
[5] Department of Internal Medicine IV – Hematology, University Hospital in Hradec Králové, Czech Republic
[6] 2nd Department of Internal Medicine – Gastroenterology, Faculty of Medicine in Hradec Králové, Charles University and University Hospital Hradec Králové, Czech Republic

✉ Assoc. Prof. PhDr. Blanka Klímová, M.A., PhD
Department of Neurology
Faculty of Medicine
of Charles University
University Hospital
Sokolská 581
500 05 Hradec Králové
Czech Republic
e-mail: blanka.klimova@uhk.cz

Accepted for review: 21. 4. 2021
Accepted for print: 9. 9. 2021

proLékaře.cz | 28.11.2026

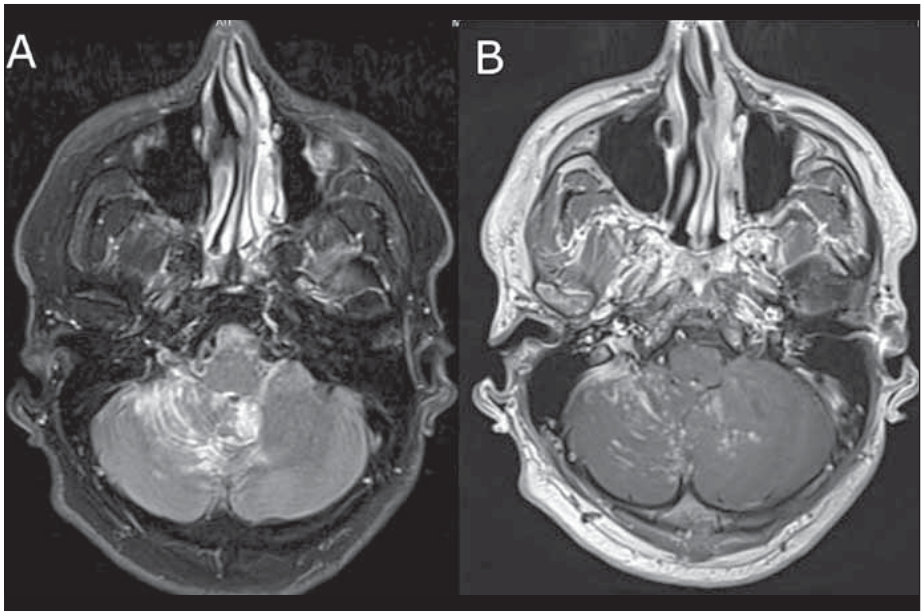

Fig. 2. MRI with contrast medium; (A) T2 FLAIR; (B) T1 weighted image – leptomeningeal opacifying infiltrations on the base of both cerebellar hemispheres, more on the right side.
FLAIR – fluid attenuated inversion recovery

Obr. 2. Kontrastní MR; (A) T2 FLAIR; (B) T1 vážený obraz – leptomeningeální opacifikující se infiltrace na bazi obou mozečkových hemisfér, více vpravo.
FLAIR – fluid attenuated inversion recovery

gnosis remained wide open, among which the possibility of multiform glioblastoma was considered.

To reduce vasogenic edema, he was treated with corticosteroids (dexamethasone 24 mg a day) and then he was transferred to the Department of Neurosurgery, UHHK to perform an open biopsy as the last diagnostic option. According to the neuronavigation examination prior to the procedure, there was a partial regression of the vasogenic edema and the postcontrast opacifying lesions. This can be attributed to the newly applied corticotherapy, which was gradually reduced to the dose of 4 mg a day. The conclusion of the histological verification of samples from open biopsy was the meningeal form of RDD with reactive gliosis in adjacent tissue without evidence of amyloid plaques. When the end of hospitalization was approaching, the patient was feeling better, and therefore he was dismissed home in a good condition with recommendation to continue corticotherapy (dexamethasone 4 mg a day). In January, March, and in May 2018, he underwent MRI of the brain with a significant regression of the pathological finding. His taste slowly returned and vision of the left eye was gradually being adjusted. Therefore, in May it was recommended to gradually discontinue the corticotherapy, and the patient was monitored in the follow-up period, which lasted to the beginning of 2020. Since January 2020, he was experiencing difficulties, mainly vomiting, then narrowing and darkening of vision, sleeplessness, neck pain, dizziness, tingling in the upper limbs and headache without effect of painkillers. During the initial neurological examination, he did not show any signs of a cerebral lesion. On the basis of a rudimentary laboratory examination, there were no significant findings. He was again acutely hospitalized in the same Department of Neurology of the UHHK and then underwent an MRI which confirmed leptomeningeal opacifying infiltrations at the base of the cerebellum and temporo-parieto-occipitally on the left side (Fig. 2). Considering the effect of corticosteroids during the first attack of the disease, he was treated with dexamethasone 24 mg a day again. This new progress of the case was discussed during the oncological seminar with neurosurgeons with conclusion that a re-biopsy from the posterior cranial fossa would be potentially dangerous with a low benefit. Afterwards, lumbar puncture was performed. The results of the basic cerebrospinal fluid examination showed only a marginal elevation of protein, lactate, and leukocytes; otherwise, there were no significant findings (including Borrelia and neurotropic viruses), immunophenotyping of cerebrospinal fluid showed 85% dominance of lymphocytes, and there were no pathologic populations of hemopoietic cells. No specific hematologic therapy was indicated. When the end of hospitalization was approaching, the patient was feeling better, and therefore he was dismissed home in a good condition. The corticotherapy with dexamethasone remained temporary, with a dose of 12 mg at the time of dismissal, and was gradually discontinued within the next 2 weeks after hospitalization. According to the last outpatient report (October 2020) of the same year, the patient was feeling better with no symptoms of the disease.

The most frequent structure affected by the intracranial form of RDD is the dura mater which can imitate a meningeal tumor [7]. The symptoms of the intracranial form of RDD vary depending on the localization, just like any intracranial lesion, but mostly are associated with headaches, seizures, or a visual disorder [1,8]. The most frequent therapeutic option of the intracranial form of RDD is surgery, which is used not only for treatment, but also as a diagnostic option. If surgery is not successful or indicated, radiotherapy is being used. Some studies used chemotherapy with a promising combination of methotrexate and 6-mercaptopurine. Corticoids are used as systemic therapy [9]. We had used them to treat vasogenic edema even before we knew the diagnosis. As presented on MRI scans, the corticoids caused regression of not only the edema but also the opacifying lesions. We used corticotherapy during the relapse of RDD, so far with a good clinical outcome (the patient has had no follow-up MRI yet).

This case describes a rare hematologic disease with primary manifestation in the CNS. The differential diagnosis is broad, from incurable glioblastoma multiforme with the prognosis of several months of survival to the rare RDD itself with a good response to treatment and a very good prognosis.

References

1. Abla O, Jacobsen E, Picarsic J et al. Consensus recommendations for the diagnosis and clinical management of Rosai-Dorman disease. Blood 2018; 131(26): 2877–2890. doi: 10.1182/blood-2018-03-839753.

2. Rosai J, Dorfman RF. Sinus histiocytosis with massive lymphadenopathy: a pseudolymphomatous be-

proLékaře.cz | 28.11.2026

nign disorder. Analysis of 34 cases. Cancer 1972; 30(5): 1174–1188. doi: 10.1002/1097-0142(197211)30:5<1174::aid-cncr2820300507>3.0.co;2-s.
3. Symss NP, Cugati G, Vasudevan MC et al. Intracranial Rosai Dorfman disease: report of three cases and literature review. Asian J Neurosurg 2010; 5(2): 19–30.
4. Amiji I, Mohammed U, Salum H et al. Rosai Dorfman disease – a rare case of cervical lymphadenopathy. ClinCaseRep2020;8(12):2712–2715.doi:10.1002/ccr3.3255. doi.10.1002/ccr3.3255.
5. Pulsoni A, Anghel G, Falcucci P et al. Treatment of sinus histiocytosis with massive lymphadenopathy (Rosai-Dorfman disease): report of a case and literature review. Am J Hematol 2002; 69: 67–71. doi: 10.1002/ajh.10008.
6. Dalia S, Sagatys E, Sokol L et al. Rosai-Dorfman disease: tumor biology, clinical features, pathology, and treatment. Cancer Control 2014; 21(4): 322–327. doi: 10.1177/107327481402100408.
7. Adeleye AO, Amir G, Fraifeld S et al. Diagnosis and management of Rosai-Dorfman disease involving the central nervous system. Neurol Res 2010; 32(6): 572–578. doi: 10.1179/016164109X12608733393836.
8. Sandoval-Sus JD, Sandoval-Leon AC, Chapman JR et al. Rosai-Dorfman disease of the central nervous system: report of 6 cases and review of the literature. Medicine (Baltimore) 2014; 93(3): 165–175. doi: 10.1097/MD.0000000000000030.
9. Deodhare SS, Ang LC, Bilbao JM. Isolated intracranial involvement in Rosai-Dorfman disease: a report of two cases and review of the literature. Arch Pathol Lab Med 1998; 122(2): 161–165.

An extended version of the article is available at csnn.eu.

