

Extensive multiple intraneural ganglion cysts of the peroneal nerve

Rozsáhlé mnohočetné intraneurální gangliony peroneálního nervu

Dear Editors,

Extensive multiple ganglion cysts are rare; they can be perineural or intraneural and may cause peripheral nerve compression. In this case report, we present patient with the compression of the common peroneal nerve in the area of the fibular head caused by multiple ganglion cysts with subsequent surgical management.

A 45-year-old male patient was healthy with only a history of varicose vein surgery. He was employed as a waiter. One morning, he began to feel paraesthesias on the instep of his right foot. Within two days, he noticed weakened elevation of his toes and had difficulty standing on his right heel. In the objective finding, there was a noticeable weakening of the dorsal flexion of the foot and toe (grade 2/5 according to the muscle test) with reduced sensation on the instep on the right-side in the innervation zone of the common peroneal nerve. Deep tendon reflexes were normal and no spine problem was detected; the patient felt only mild

and localized pain in the knee area at grade 2/10 according to Visual Analogue Scale.

He was referred for physiotherapy and an EMG was scheduled, which was performed a month after the onset of the symptoms. EMG detected a partial denervation syndrome of the common peroneal nerve on the right side in the area of the fibular head, with acute denervation changes in the peroneus longus muscle and anterior tibialis muscle. The patient continued physiotherapy and stated subjective improvement. Two weeks after the EMG examination after a long walk, he complained of substantial swelling around the knee associated with localized pain in the head of the right fibula without significant worsening of the palsy. Furthermore, a prominent solid formation appeared in this area. The patient was quickly referred for ultrasound examination. A lesion with septa, 57 × 10 × 30 mm, was found compressing the peroneal nerve, probably a ganglion cyst. MRI of the right knee was performed, detecting a cystoid septal

The Editorial Board declares that the manuscript met the ICMJE "uniform requirements" for biomedical papers.

Redakční rada potvrzuje, že rukopis práce splnil ICMJE kritéria pro publikace zasílané do biomedicínských časopisů.

I. Štětkařová¹, F. Šámal², A. Štěrbá², V. Boček¹, M. Židó¹, E. Ehler³, H. Malíková⁴

¹ Department of Neurology, Third Faculty of Medicine, Charles University and Faculty Hospital Kralovské Vinohrady, Czech Republic

² Department of Neurosurgery, Third Faculty of Medicine, Charles University and Faculty Hospital Kralovské Vinohrady, Czech Republic

³ Neurological Department, Faculty of Health Studies, Pardubice University and Pardubice Regional Hospital

⁴ Department of Radiology, Third Faculty of Medicine, Charles University and Faculty Hospital Kralovské Vinohrady, Czech Republic



Prof. Ivana Štětkařová, MD, PhD, MHA
Department of Neurology
Third Faculty of Medicine
Charles University
Ruska 87
100 00 Prague
Czech Republic
e-mail: ivana.stetkarova@fnkv.cz

Accepted for review: 21. 5. 2021

Accepted for print: 4. 11. 2021

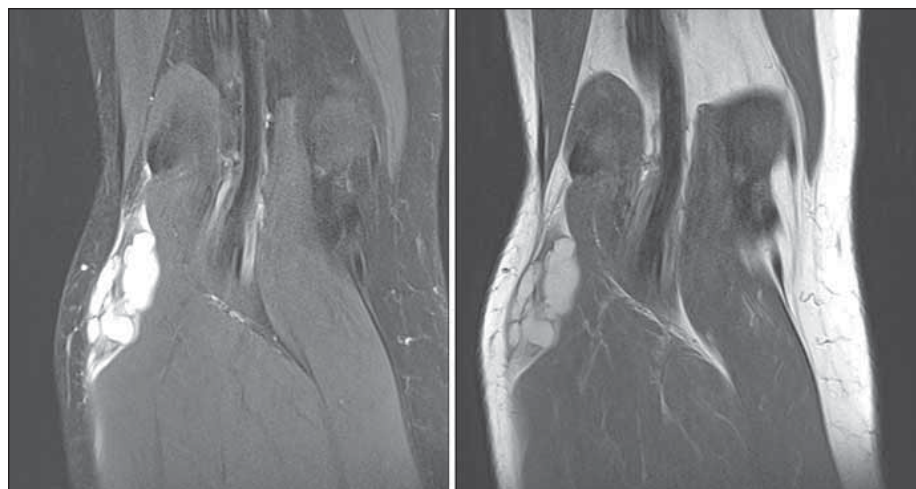


Fig. 1. MRI scan before the release of the common peroneal nerve from multiple ganglion cysts (coronary scan in proton density weighted image including fat saturation and in T2-weighted image).

Obr. 1. MR před uvolněním n. peroneus communis z mnohočetných ganglionárních cyst (koronární rovina v PD (proton density) vážení vč. saturace tuku a v T2 vážení).

T2 hypersignal formation in the soft tissues around the fibular head and under the fibular head medially with a diameter of about 32 × 20 mm; it was also located externally (the largest one was about 30 × 15 mm). The findings corresponded to multiple ganglion

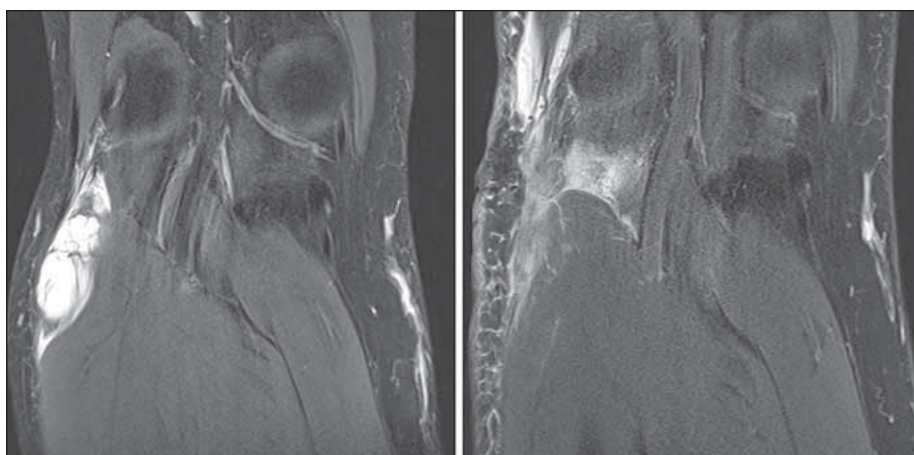


Fig. 2. Comparison of MRI findings of the popliteal area before (left) and after (right) the extirpation of multiple ganglion cysts close to the common peroneal nerve (follow-up MRI performed 7 days after the surgery) (coronary scan in PD weighted image).

PD – proton density

Obr. 2. Srovnání nálezů na MR popliteální krajiny před (vlevo) a po (vpravo) extirpaci mnohočetných ganglionárních cyst v blízkosti n. peroneus communis (kontrolní MR provedena za 7 dní od operace) (koronární rovina v PD vážení).

PD – proton density

cysts (Fig. 1). Early neurosurgical intervention with decompression in the area of the fibular head was indicated due to the size and substantial compression of the peroneal nerve. The common peroneal nerve was dissected from an incision in the area of the right fibular head. In the distal direction, the nerve was dilated and embedded in multiple ganglion cysts. The nerve was dissected at the site of its entry into the ganglion cysts; individual fascicles were gradually released from multiple cysts. Electrical stimulation of the fascicles was used for better visualisation. Cysts linked with a bridge, with another large lesion, were found beneath the peroneus longus muscle, forming multiple cysts between the fibula and the tibia. These cysts were removed after the release of individual nerve fascia. The nerve was freed after the decompression, with preserved activity checked by electrical stimulation. The diagnosis of multiple intraneural ganglion cysts was confirmed histologically. A follow-up MRI of the knee was performed one week after the surgery, with a favourable finding after the decompression (Fig. 2). The patient stopped feeling pain, and the strength of the dorsal foot flexion improved clinically. He underwent intensive physiotherapy.

Multiple intraneural ganglion cysts are a rare cause of peripheral nerve compression affecting most commonly the peroneal

nerve in the area of the fibular head [1], but they can also affect the median nerve [2], ulnar nerve [3] or sciatic nerve. Intraneural ganglia originate in the joint from where they enter the articular nerve branch into the nerve trunk and further spread below its epineuria. They can often recur after surgery [1, 4]. The diagnosis is made based on the morphological examination with key positioning of the MRI, showing the extent of the ganglion cysts and their relationship to the nerve and bone, similar to the presentation in our patient. The compression of the common peroneal nerve leads to recurrent paraesthesia; more pronounced compression causes motor dysfunction with paresis of the crural extensors, eversion of the foot and small muscles of the dorsum of the foot and toe. In our patient, the symptoms worsened after a long walk. There was no history of injury or other causal factors.

MRI reliably detects ganglion cysts and their relationship to the peroneal nerve. The connection between the cyst and the upper tibiofibular joint is usually found [5], as seen in our case. Follow-up ultrasound examination is recommended after the decompression [6]. We performed a follow-up MRI of the knee with a favourable finding after the decompression.

If the common peroneal nerve is substantially affected, it is possible to perform

a nerve transfer to the tibialis anterior and hallucis longus muscles during the decompression [7]. We did not recommend this approach to our patient due to a moderate motor deficit and a relatively favourable EMG finding of a partial denervation syndrome.

The surgical strategy distinguishes between the so-called true, intraneurally located ganglion cysts, where the removal is very difficult or impossible without damaging nerve function, and perineural cysts, which most commonly grow out of a closed joint and compress the adjacent nerve. Radical resection of all cystic formations and electrical coagulation or ligation of their stems attached to the joint cavity and cystic bridges are recommended in the latter category to minimize the risk of recurrence. We chose this procedure for our patient.

Common peroneal lesions in the area of the fibular head are usually considered to be caused by a pressure-compression ischaemic lesion. However, it is necessary to think of multiple ganglion cysts as a very rare cause, and to perform ultrasound examination and MRI of the knee. Surgical management is indicated in case of a significant morphological finding, especially of a cystic lesion.

Acknowledgments

Supported by Research projects of Charles University PROGRES Q 35, Q37, and 260533/SVV/2021.

References

1. Drábek P, Filip M, Šupšáková P et al. Recidivující intra-neurální ganglion n. peroneus comm. *Cesk Slov Neurol N* 2001; 64/97(5): 300–303.
2. Kerrigan JJ, Bertoni JM, Jaeger SH. Ganglion cysts and carpal tunnel syndrome. *J Hand Surg Am* 1988; 13(5): 763–765. doi: 10.1016/s0363-5023(88)80144-8.
3. Öztürk U, Saldüz A, Demirel M et al. Intraneural ganglion cyst of the ulnar nerve in an unusual location: a case report. *Int J Surg Case Rep* 2017; 31: 61–64. doi: 10.1016/j.ijscr.2017.01.007.
4. Adil A, Basener C, Checketts J. Intraneural synovial cyst of the common peroneal nerve: an unusual cause of foot drop with four-year follow-up. *Case Rep Orthop* 2019; 2019: 8045252. doi: 10.1155/2019/8045252.
5. Spinner RJ, Atkinson JL, Scheithauer BW et al. Peroneal intraneural ganglia: the importance of the articular branch. *Clinical series. J Neurosurg* 2003; 99(2): 319–329. doi: 10.3171/jns.2003.99.2.0319.
6. Ratanshi I, Clark TA, Giuffre JL. Immediate nerve transfer for treatment of peroneal nerve palsy secondary to an intraneural ganglion: case report and review. *Plast Surg (Oakv)* 2018; 26(2): 80–84. doi: 10.1177/2292550317747844.
7. Knoll A, Pala A, Pedro MT et al. Clinical outcome after decompression of intraneural peroneal ganglion cyst and its morphologic correlation to postoperative nerve ultrasound. *J Neurosurg* 2019; 1–7. doi: 10.3171/2019.3.JNS182699.

An extended version of this article can be found at csnn.eu.