proLékaře.cz | 23.11.2026

doi: 10.48095/cccsnn2021576

Spinal sulcal artery syndrome after stent-assisted coil embolization of unruptured vertebral artery aneurysm

Syndrom spinální sulkální arterie po stentem asistované embolizaci nepraskléhо aneuryzmatu vertebrální tepny embolizačním koilem

Dear editorial office,

Spinal cord infarction (SCI) is a much rarer disease than cerebral infarction, and accounts for only 1% of all strokes [1]. The common causes of SCI are atherosclerosis or dissection of the vertebral artery (VA), cardiac embolism, systemic hypotension, vascular malformation, vasculitis, and trauma [1]. Cervical SCI following intracranial endovascular intervention is extremely rare and mainly occurs within 24 h after the procedure [2]. Here, we present a rare case of upper cervical SCI caused by the involvement of the spinal sulcal artery (SSA), which is the penetrating branch of the anterior spinal artery (ASA), that occurred 6 days after stent-assisted coil embolization (SAC) of an unruptured VA aneurysm.

A 51-year-old woman presented at our department with an intracranial aneurysm that was found incidentally. DSA revealed a wide-necked saccular aneurysm in the left intracranial VA (Fig. 1A). After dual antiplatelet therapy (DAPT) (100 mg aspirin and 75 mg clopidogrel daily) for 2 weeks, SAC was performed.

Under general anesthesia, intravenous heparin was administered as a 2,000 IU bolus just after femoral sheath insertion, followed by the administration of 1,000 IU hourly. The left VA was catheterized using a 7 F guide catheter (Guider™, Stryker, Kalamazoo, MI, USA) and the distal tip of the guide catheter was placed at the level of the C2 transverse foramen. The 7 F guide catheter was used rather than 6 F for the advancement of a double microcatheter to insure sufficient continuous catheter irrigation, and the inner diameter of VA at V3 segment was measured to be large enough for 7 F catheter placement. The stent (Enterprise VRD® 4 × 20 mm, Codman), New Brunswick, NJ, USA and three detachable coils were successfully deployed using the jailing-technique. During the procedure, mild vasospasm was observed near the guide catheter tip (Fig. 1B), but no vasodilator was used. The ASA and posterior inferior cerebellar artery were visualized on postprocedural angiography (Fig. 1C). After the procedure, DAPT was continued and the patient was discharged 2 days after the procedure without any neurologic symptoms.

Six days after the procedure, the patient was re-admitted because of painful dysesthesias in the right arm. On neurological examination, pinprick and temperature sensation in the right arm were diminished, but vibratory sensation and proprioception were preserved. All cranial nerve functions were normal, but grasping strength in her left hand had decreased to grade 4/5. Brain and cervical MRI revealed an acute infarction in the left anterior portion at the level of C2 (Fig. 2).

Because the patient's symptoms were not severe, we added an oral steroid (60 mg of prednisolone for 5 days, then tapered by 10 mg every day) and pregabalin (75 mg twice a day) to alleviate the patient's symptoms while maintaining DAPT. The dysesthesias had improved and completely resolved at the 9-month follow-up visit. The 1-year follow-up DSA revealed complete occlusion of the aneurysm.

The most common clinical feature of cervical SCI is ASA syndrome which presents with bilateral extremity weakness and dissociated sensory deficits, because the apical ASA generally supplies the bilateral anterior two-thirds of the spinal cord, including the corticospinal and spinothalamic tracts [1]. The SSA is the penetrating branch of the ASA, which enters the spinal cord in the anterior fissure and supplies the anterior two-thirds of the spinal cord unilaterally [1,3]. We speculated that SCI occurred due to the occlusion of the SSA rather than of the ASA because the symptoms in our patient presented unilaterally, and MRI revealed an acute infarction in the left anterior cord at the C2 level. SSA syndrome is similar to Brown-Séquard syndrome, which presents with ipsilateral extremity weakness and contralateral sensory loss to pain/temperature or hyperalgesia; however, in contrast to Brown-Séquard syndrome, proprioception and vibratory

The Editorial Board declares that the manuscript met the ICMJE "uniform requirements" for biomedical papers.
Redakční rada potvrzuje, že rukopis práce splnil ICMJE kritéria pro publikace zasílané do biomedicínských časopisů.

D. H. Choi, S. Son, C. J. Yoo, M. J. Kim, C. W. Park

Department of Neurosurgery, Gil Medical Center, Gachon University College of Medicine, Incheon, Republic of Korea

✉
Seong Son
Department of Neurosurgery
Gil Medical Center
Gachon University College of Medicine
21 Namdong-daero 774beon-gil
Namdong-gu, Incheon
Republic of Korea
e-mail: sonseong@gilhospital.com

Accepted for review: 4. 5. 2021
Accepted for print: 4. 11. 2021

proLékaře.cz | 23.11.2026

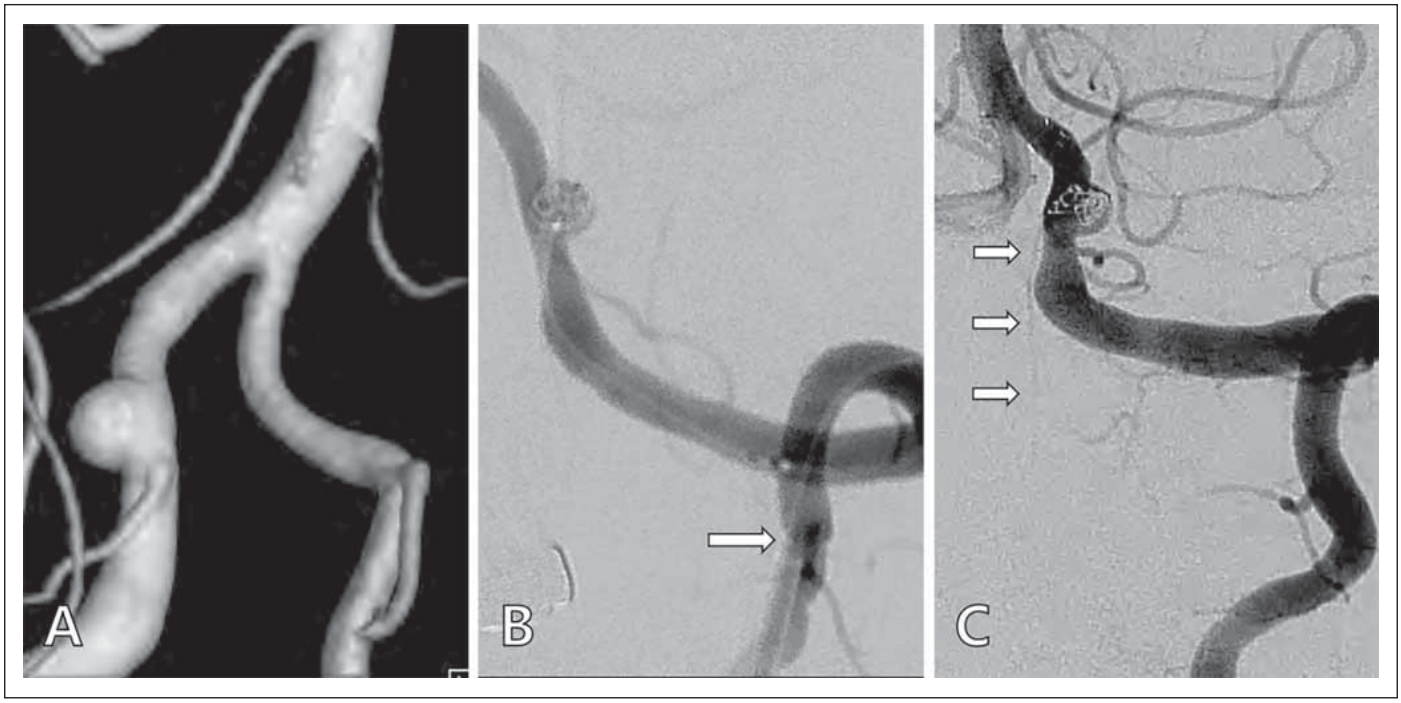

Fig. 1. (A) Preoperative angiography showing a saccular aneurysm in the left vertebral artery. (B) Mild vasospasm of the vertebral artery near the tip of guide catheter (arrow). (C) Left anterior spinal artery (arrows) visualized on postoperative angiography.

Obr. 1. (A) Předoperační angiografie, která ukazuje sakulární aneuryzma na levé vertebrální tepně. (B) Mírný vazospasmus vetrtebrální tepny v blízkosti špičky zaváděcího katetru (šipka). (C) Levá přední spinální tepna (šipky) vizualizovaná pooperační angiografií.

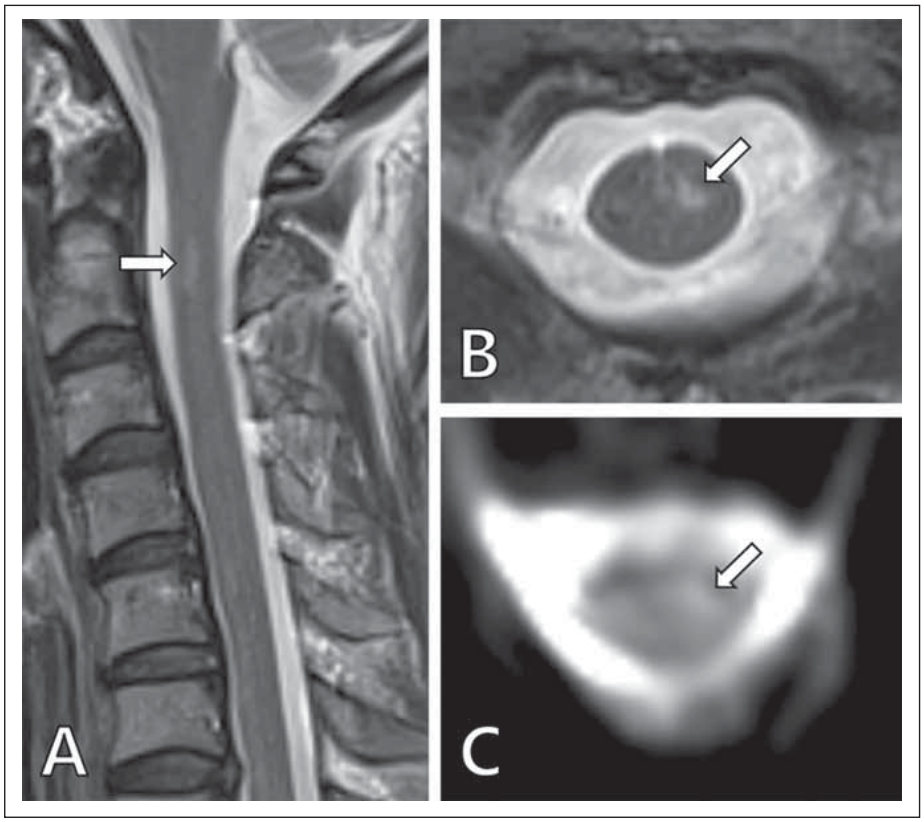

Fig. 2. Postoperative cervical MRI.

Sagittal (A) and axial (B) T2-weighted images showing focal hyperintensity lesions with diffusion restriction (C) of the left anterior portion of the spinal cord at the C2 level, suggestive of spinal cord infarction.

Obr. 2. Pooperační MR krční páteře.

Sagitální (A) a axiální (B) T2-vážený obraz, který ukazuje fokální hyperintenzní léze s restrikcí difuze (C) levé přední části míchy na úrovni C2, naznačující infarkt míchy.

sensation are preserved because posterior columns are spared [4].

The possible causes of SCI include thromboemboli and/or hemodynamic insufficiency due to periprocedural systemic hypotension [1], vasospasm or flow stagnation induced by the wedged guide catheter [5], stent-induced thromboembolism [6], or insufficient platelet suppression [7]. Systemic hypotension can cause a watershed infarction that develops in the border zone, and SCI can present bilaterally. In our patient, the blood pressure had been maintained normally during the procedure and postoperative period.

Mechanically-induced vasospasm can lead to the hypoperfusion, which causes thromboembolic complications [5]. Although the vasospasm was prolonged near the tip of the guide catheter during the procedure in this case, a vasodilator such as a calcium channel blocker was not administered because vasospasm was mild, and contrast stagnation was not observed.

Previous studies have reported an ischemic event rate of 4–22% after SAC, and

proLékaře.cz | 23.11.2026

most thromboembolic complications occur within the first 24–48 h [6]. In this case, the stent was deployed involving the origin of the left ASA. Although the ASA was visualized on the final angiography, the stent may have led to inadequate flow or caused microemboli in the SSA. The thromboembolic complications after stent placement may be related to insufficient platelet inhibition [7]. In our patient, the platelet drug response assay was not tested after the symptom occurrence because preoperative platelet inhibition using aspirin and clopidogrel was in the optimal range (397 aspirin reaction units, 187 P2Y12 reaction units), and DAPT was continued after the procedure. Many clinical studies have revealed no definite association between high aspirin platelet reactivity and clinical outcomes [8]; however, Kim et al [9] reported a thromboembolic event rate of 0.8% (one of 126 cases) in patients with < 220 P2Y12 reaction units.

Small branches of the VA may play an important role in the blood supply to the spinal cord, but the majority are not visualized during angiography [10]. Therefore, it is difficult to predict the occurrence of SCI after intracranial endovascular intervention. Neurointerventionalists should consider the possibility of SCI as a postoperative complication, especially in procedures affecting posterior circulation.

References

1. Weidauer S, Nichtweiß M, Hattingen E et al. Spinal cord ischemia: aetiology, clinical syndromes and imaging features. Neuroradiology 2015; 57(3): 241–257. doi: 10.1007/s00234-014-1464-6.
2. Matsubara N, Miyachi S, Okamaoto T et al. Spinal cord infarction is an unusual complication of intracranial neuroendovascular intervention. Interv Neuroradiol 2013; 19(4): 500–505. doi: 10.1177/159101991301900416.
3. Kashiwazaki D, Ushikoshi S, Asano T et al. Long-term clinical and radiological results of endovascular internal trapping in vertebral artery dissection. Neuroradiology 2013; 55(2): 201–206. doi: 10.1007/s00234-012-1114-9.
4. Li Y, Jenny D, Bemporad JA et al. Sulcal artery syndrome after vertebral artery dissection. J Stroke Cerebrovasc Dis 2010; 19(4): 333–335. doi: 10.1016/j.jstrokecerebrovasdis.2009.05.006.
5. Ishihara H, Ishihara S, Niimi J et al. Risk factors and prevention of guiding catheter-induced vasospasm in neuroendovascular treatment. Neurol Med Chir (Tokyo) 2015; 55(3): 261–265. doi: 10.2176/nmc.oa.2014-0268.
6. Matsumoto Y, Nakai K, Tsutsumi M et al. Onset time of ischemic events and antiplatelet therapy after intracranial stent-assisted coil embolization. J Stroke Cerebrovasc Dis 2014; 23(4): 771–777. doi: 10.1016/j.jstrokecerebrovasdis.2013.07.008.
7. Yang H, Li Y, Jiang Y. Insufficient platelet inhibition and thromboembolic complications in patients with intracranial aneurysms after stent placement. J Neurosurg 2016; 125(2): 247–253. doi: 10.3171/2015.6.JNS1511.
8. Yi HJ, Hwang G, Lee BH. Variability of platelet reactivity on antiplatelet therapy in neurointervention procedure. J Korean Neurosurg Soc 2019; 62(1): 3–9. doi: 10.3340/jkns.2018.0151.
9. Kim CH, Hwang G, Kwon O-K et al. P2Y 12 reaction units threshold for implementing modified antiplatelet preparation in coil embolization of unruptured aneurysms: a prospective validation study. Radiology 2016; 282(2): 542–551. doi: 10.1148/radiol.2016160542.
10. An JY, Song IU, Kim WJ et al. Posterior cervical spinal cord infarction following thyrocervical trunk embolization. Eur Neurol 2008; 59(3–4): 200–201. doi: 10.1159/000114046.

Vzdělávací internetové stránky o demencích

Vážené a milé kolegyně a kolegové,

v roce 2021 skončil 3letý evropský grant Innovation for Dementia in the Danube Region (INDEED), jehož účelem bylo vyvinout elektronickou platformu ke vzdělávání o demencích. Je určena pro organizátory aktivit, instituce a firmy zabývající se kognitivními poruchami a demencemi. Podařilo se vytvořit rozsáhlé internetové stránky. Je možné je používat jakkoli zdarma po registraci, takže např. pro různé výukové účely.

Existují v 5 jazycích vč. slovenštiny a angličtiny. Budeme rádi, když je budete využívat nebo poskytovat dalším nebo informovat o nich kohokoli, pro koho by mohly mít užitek.

ve slovenštině: https://sk.indeed-project.eu/login

v angličtině: https://en.indeed-project.eu/login

prof. MUDr. Aleš Bartoš, PhD
spoluřešitel evropského grantu Innovation for Dementia in the Danube Region (INDEED)
Fakultní nemocnice Královské Vinohrady, Univerzita Karlova 3. LF, Praha
Národní ústav duševního zdraví, Klecany
e-mail: ales.bartos@nudz.cz