proLékaře.cz | 25.11.2026

doi: 10.48095/cccsnn2022261

Tracheostomy in the treatment of obstructive sleep apnoea is not always the definitive solution

Tracheostomie v léčbě obstrukční spánkové apnoe není vždy definitivní řešení

The Editorial Board declares that the manuscript met the ICMJE "uniform requirements" for biomedical papers.
Redakční rada potvrzuje, že rukopis práce splnil ICMJE kritéria pro publikace zasílané do biomedicínských časopisů.

M. Masárová[1,2], M. Formánek[1,2], K. Zeleník[1,2], P. Komínek[1,2], P. Matoušek[1,2]

[1] Department of Craniofacial Disciplines, Faculty of Medicine, University of Ostrava, Czech Republic
[2] Department of Otorhinolaryngology and Head and Neck Surgery, University Hospital Ostrava, Czech Republic

✉ Petr Matoušek, MD, PhD, MBA
Department of Otorhinolaryngology and Head and Neck Surgery
University Hospital Ostrava
17. listopadu 1790
708 52 Ostrava
Czech Republic
e-mail: petr.matousek@fno.cz

Accepted for review: 12. 4. 2022
Accepted for print: 25. 5. 2022

Dear Editors,

Tracheostomy was a relatively common therapeutic method in patients with severe obstructive sleep apnoea (OSA) in the era before the introduction of positive airway pressure (PAP) [1,2]. Unfortunately, PAP could often be insufficient in patients with a body mass index (BMI) over 40. Therefore, even today, tracheostomy has its place in the treatment of mainly polymorbid and morbidly obese patients with OSA [1–3].

The authors present a unique case of a morbidly obese patient with breathing difficulties and severe OSA due to extreme hypertrophy of the base of the tongue (suspected malignant disease), so it was necessary to perform a tracheostomy. Subsequent partial laser endoscopic resection and radiofrequency reduction of the tongue base allowed gradual decannulation of the patient, and the residual OSA was subsequently solved by PAP.

A 57-year-old morbidly obese female (BMI 52) was examined at the district Ear, nose and throat (ENT) site for progressively worsening sleep apnoeic episodes lasting for 6 months and a sudden feeling of suffocation while sleeping. During the ENT examination, significant hypertrophy of the base of tongue (Friedman 4) was found.

Malignacy has been suspected. The MRI showed a homogeneous soft-tissue mass at the base area of the tongue (Fig. 1). Biopsy from the base of the tongue was performed under general anaesthesia. Due to very difficult intubation and the assumption of difficulty in ensuring breathing during the postoperative period, elective tracheostomy was performed. Histologically, the finding was evaluated as benign hypertrophy of the tongue tonsil; no malignacy has been confirmed. Patient was first consulted to live with a tracheostomy due to the expected anaesthesiologic risks, extreme obesity with suspected severe OSA and difficult

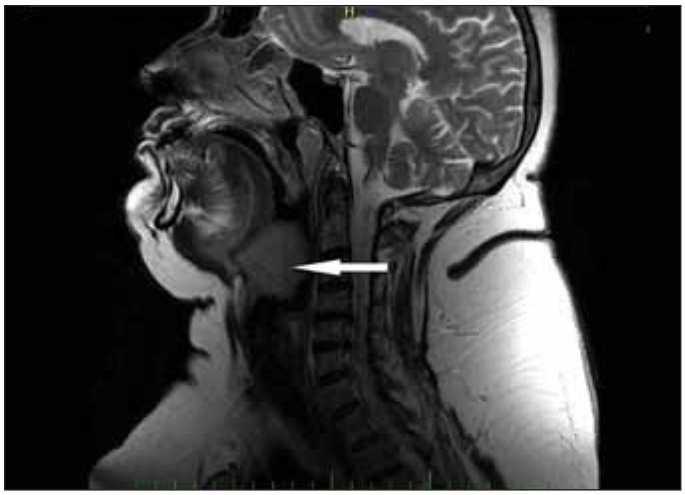

Fig. 1. MRI of the head and the neck; T2-weighted image in the sagittal plane. A homogenous soft-tissue mass in the base area of the tongue (arrow).

Obr. 1. MR hlavy a krku; T2 vážený sken, sagitální řez. Homogenní měkkotkáňová masa v oblasti kořene jazyka (šipka).



Fig. 2. Endoscopic view of the base of the tongue. Preoperative videoendoscopic finding from nasopharynx. Hypertrophic base of the tongue (Friedman 4) almost completely obstructing the pharynx.

Obr. 2. Endoskopický pohled na kořen jazyka; předoperační endoskopický nález, pohled z nosohltanu. Hypertrofie kořene jazyka (Friedman 4) téměř kompletně obstruující hltan.

proLékaře.cz | 25.11.2026

surgical treatment in very unfavourable anatomical conditions. Three months later, she was referred to the tertiary referral centre, where extreme hypertrophy of the base of the tongue completely overlapped the epiglottis, almost completely obstructing the pharynx but the entrance to the larynx was found (Fig. 2). In spite of risks, the patient was strongly motivated to undergo surgery in order to achieve the removal of tracheostomy (decannulation). An important step confirming the patient's motivation was her weight reduction due to the adherence to dietary recommendations.

Subsequent partial laser (thulium) resection and radiofrequency thermoablation of the base of the tongue using a hypopharyngoscope, directive laryngoscope and 30° endoscope were necessary to provide sufficient space for breathing. The resection was carried out at three times a week and a three-month interval. During the first surgery, orientation was very challenging due to the voluminous mass of the hypertrophic base of the tongue. The entrance to the larynx could be partially visualised only at the end of the second surgery. Three days after the third surgery, there was bleeding from the wound; a revision was performed under general anaesthesia, otherwise the postoperative adaptation of the patient was good at all times.

Two months after the surgeries, the patient was decannulated during sleep endoscopy. Limited polygraphy was performed with the finding of a moderate OSA with an apnoea-hypopnea index (AHI) of 22. The patient was indicated for treatment with PAP under the supervision of the sleep laboratory at the place of residence.

Morbidly obese patients are generally at high risk with respect to any surgical intervention in the area of swallowing and respiratory tract. In these patients, the tracheostomy represents the definitive solving the OSA with regard to the fact that it allows ventilation below the level of the upper airways, where obstructions during sleep occur [2–4].

The effectiveness of tracheostomy was confirmed by a number of studies. Camacho et al. in a meta-analysis of 18 studies report that an average decrease in AHI from 73 to 0.2 / hour was observed in patients after tracheostomy [4]. There are also data showing long term decrease of AHI, improvement in oxygen saturation of the blood, and improvement in subjective quality of life after tracheostomy in patients with OSA [3–5].

On the other hand, it should be kept in mind that permanent tracheostomy can also be associated with a number of complications, such as relapsing tracheitis and bronchitis, dislocation of the tracheostomy cannula with suffocation, and formation of granulation tissue. There is also limited function of the nasal cavity (filtration, heating, humidification of the air, sense of smell) and higher demands (e.g., care of the tracheostoma) and restrictions (e.g., swimming). In particular, the social impact is perceived in a significantly negative way [2]. Therefore, it should always be carefully considered if decannulation and elimination of tracheostomy can be achieved even in obese patients [4–6].

Decannulation is generally considered a risky process, particularly in patients with a narrowed lumen of the upper airways, i.e., in patients with OSA. It is the presence of the hypertrophic base of the tongue and pathology in the area of the epiglottis that is most critical for decannulation. Decannulation should be carefully considered particularly in patients who are expected to have high-risk intubation [6]. Decannulation after endoscopic control of the upper airways by a flexible endoscope is considered safer [2,6,7].

Our case report shows that tracheotomy still has its place in the OSA treatment and it is eventually possible with appropriate surgical techniques and safety conditions (secured airways, decannulation after sleep endoscopy, postoperative observation) in some patients to perform decannulation. However, current regimen measures, including weight reduction and patient cooperation, are necessary.

Funding

This study was supported by the project University of Ostrava grant SGS16/LF/2022.

References

1. Weaver TE, Grunstein RR. Adherence to continuous positive airway pressure therapy the challenge to effective treatment. Proc Am Thorac Soc 2008; 5(2): 173–178. doi: 10.1513/pats.200708-119MG.

2. Camacho M, Zaghi S, Chang ET et al. Mini tracheostomy for obstructive sleep apnea: an evidence based proposal. Int J Otolaryngol 2016; 2016: 7195349. doi: 10.1155/2016/7195349.

3. Haapaniemi JJ, Laurikainen EA, Halme P et al. Long-term results of tracheostomy for severe obstructive sleep apnea syndrome. ORL J Otorhinolaryngol Relat Spec 2001; 63(3): 131–136. doi: 10.1159/000055728.

4. Camacho M, Certal V, Brietzke SE et al. Tracheostomy as treatment for adult obstructive sleep apnea: a systematic review and meta-analysis. Laryngoscope 2014; 124(3): 803–811. doi: 10.1002/lary.24433.

5. Kim SH, Eisele DW, Smith PL et al. Evaluation of patients with sleep apnea after tracheostomy. Arch Otolaryngol Head Neck Surg 1998; 124(9): 996–1000. doi: 10.1001/archotol.124.9.996.

6. Montevecchi F, Cammaroto G, Meccariello G et al. Transoral robotic surgery (TORS): a new tool for high risk tracheostomy decannulation. Acta Otorhinolaryngol Ital 2017; 31(1): 46–50. doi: 10.14639/0392-100X-1134.

7. Son EL, Underbring MP, Qui S et al. The surgical plane for lingual tonsillectomy: an anatomic study. J Otolaryngol Head Neck Surg 2016; 45(22): 1161–1166. doi: 10.1186/s40463-016-0137-3.