

# Vestibular rehabilitation in patients after vestibular schwannoma surgery

## Vestibulární rehabilitace u pacientů po operaci vestibulárního schwannomu

### Abstract

This review aims to summarize the current vestibular rehabilitation options in patients after vestibular schwannoma surgery. Resection of the tumor usually leads to unilateral acute peripheral or combined vestibular loss caused by a surgical lesion to the branches of the vestibular nerve and less frequently also a lesion in the cerebellum. In patients, the vestibular lesion manifests as postural instability, vertigo, oscillopsia and vegetative symptoms. Human organisms react to this state using the process of central compensation with a significant role of the cerebellum. The goal of vestibular rehabilitation is to support this process and thus make recovery faster and more efficient since not all patients are capable of sufficient restoration of vestibular function. Currently, vestibular rehabilitation includes, apart from the specific vestibular exercise, modern techniques using virtual reality space and prehabilitation. Due to prehabilitation, i.e., preoperative chemical labyrinthectomy with intratympanically installed gentamicin, the timing of the origin of the acute vestibular loss and surgical procedure is separated. Therefore, there is a chance of achieving vestibular compensation before vestibular schwannoma removal. In the last decade, the tools for virtual reality have become less expensive and more available in medical care. Virtual reality is a technique used for generating an environment that can strengthen three-dimensional optokinetic stimulation, subsequently the process of central compensation and finally it may improve patients' quality of life.

### Souhrn

Cílem práce je podat přehled o současných možnostech vestibulární rehabilitace u pacientů po operaci vestibulárního schwannomu. Resekce nádoru vede obvykle ke vzniku jednostranné akutní periferní či kombinované vestibulární léze způsobené přerušením větví vestibulárního nervu a případně i poškozením mozečku. Léze se projevuje u pacientů poruchami stability, závratí, oscilopsií a vegetativním doprovodem. Lidský organizmus na tuto situaci reaguje zahájením mechanismu centrální kompenzace, v níž hraje zásadní úlohu mozeček. Cílem vestibulární rehabilitace je tyto mechanismy posílit a rekonvalescenci pacientů nejen zrychlit, ale zároveň dosáhnout i lepších funkčních výsledků, neboť ne všichni pacienti jsou schopni lézi dostatečně zkompenzovat. Vestibulární rehabilitace v sobě v současné době zahrnuje kromě specifických vestibulárních cvičení také možnosti využití prehabituace a virtuální reality. Díky prehabituaci, tedy předoperační chemické labyrintektomii pomocí intratympanálně podaného gentamicinu, dochází k časovému oddělení vzniku vestibulární léze od vlastního chirurgického výkonu a tím možnosti dosažení vestibulární kompenzace ještě před samotnou resekci vestibulárního schwannomu. V poslední dekádě se nástroje pro využití virtuální reality stávají cenově dostupné, a tím pádem i v širší praxi použitelné. Prostřednictvím virtuální reality mohou být pacienti vystavováni scénám, které posilují 3D optokinetickou stimulaci, čímž se rozšiřují možnosti posilování centrálních kompenzačních mechanismů a tím dochází ke zlepšení kvality života pacientů.

The Editorial Board declares that the manuscript met the ICMJE "uniform requirements" for biomedical papers.

Redakční rada potvrzuje, že rukopis práce splnil ICMJE kritéria pro publikace zasílané do biomedicínských časopisů.

**M. Bonaventurová<sup>1</sup>, Z. Čada<sup>2</sup>,  
V. Koucký<sup>1</sup>, V. Bandúrová<sup>1</sup>,  
V. Svobodová<sup>1</sup>, K. Červený<sup>1</sup>,  
P. Hermann<sup>2</sup>, O. Čákr<sup>3</sup>, Z. Fík<sup>1</sup>,  
J. Plzák<sup>1</sup>, Z. Balatková<sup>1</sup>**

<sup>1</sup> Department of Otorhinolaryngology and Head and Neck Surgery, 1<sup>st</sup> Faculty of Medicine Charles University in Prague and University Hospital Motol, Czech Republic

<sup>2</sup> Department of Otorhinolaryngology and Head and Neck Surgery, 2<sup>nd</sup> Faculty of Medicine Charles University in Prague and University Hospital Motol, Czech Republic

<sup>3</sup> Department of Rehabilitation and Sports Medicine, 2<sup>nd</sup> Medical Faculty, Charles University and University Hospital Motol, Czech Republic



**Markéta Bonaventurová, MD**  
Department of Otorhinolaryngology and Head and Neck Surgery  
1<sup>st</sup> Faculty of Medicine  
Charles University  
and University Hospital Motol  
V Úvalu 84, 150 06 Prague  
Czech Republic  
e-mail:  
marketa.bonaventurova@fnmotol.cz

Accepted for review: 15. 12. 2022

Accepted for print: 21. 3. 2023

### Key words

vestibular schwannoma – vestibular compensation – vestibular rehabilitation – prehabilitation – virtual reality

### Klíčová slova

vestibulární schwannom – vestibulární kompenzace – vestibulární rehabilitace – prehabituace – virtuální realita

## Introduction

### Vestibular schwannoma

Vestibular schwannoma (VS), also called acoustic neuroma, is a benign, slow-growing intracranial tumor arising from Schwann cells, which myelinate the vestibular portion of the eighth cranial nerve. It originates in the internal auditory canal and can extend into the cerebellopontine angle (CPA) (Fig. 1). There is belief that it arises precisely from the glial-Schwann cell junction (or so-called Obersteiner-Redlich zone); however, according to some authors, this hypothesis is questionable [1]. The incidence of these tumors is 1 per 100,000 people/year, and the rate has increased over time [2]. Patients with VS experience dysfunction of structures sharing anatomical proximity with the tumor. The most typical clinical presentations associated with VS are hearing loss, tinnitus, vertigo, dizziness, and disequilibrium. Some patients show the dysfunction of other cranial nerves, such as trigeminal (9%) and facial (6%) [3]. Patients with hearing loss usually undergo audiometric evaluation and those with vestibular disturbance have an otoneurologic examination. The finding of unilateral or asymmetric sensorineural hearing loss, tinnitus or any malfunction in other cranial nerves should lead to imaging workup. The standard method is gadolinium-enhanced MRI of the internal acoustic meatus. VS typically occurs in the 5<sup>th</sup> or 6<sup>th</sup> decade of life [2]. Current management options include observation (wait and scan by MRI, 30%), radiation treatment (stereotactic surgery with

the Leksell gamma knife, 30%), and surgical resection (40%). Management strategies vary from center to center and depend on size, growth, and patient risk factors. There is a strong shift in the management of VS away from active approaches (surgery and radiation) toward a “wait-and-scan” approach [4]. The risk to adjacent structures, in particular, hearing preservation and facial nerve function, is a critical component of patient counselling and selection of treatment modalities. The main difference between radiation and surgical intervention is that surgery seeks to remove the tumor totally or near-totally, while radiation only seeks to prevent additional growth [5,6]. The adverse events associated with surgical resection are lesions of the cranial nerves (mainly facial neuropathy), cerebrospinal fluid leakage and infection. Despite its invasiveness and adverse effects, surgery still remains the most efficacious treatment for acoustic neuromas – only about 1% of patients require additional therapy [5].

### Acute peripheral (or combined) vestibular loss

Inherently, the vestibular branch of the eighth cranial nerve is almost always dissected during the surgical procedure (Fig. 2), and thus the patient experiences partial or complete unilateral loss of vestibular function [7]. The peripheral vestibular system consists of the saccule, utricle, and semicircular canals. The neuroepithelial hair cells within the peripheral vestibular apparatus

send projections to the vestibular nuclei in the caudal pons and rostral dorsolateral medulla by the vestibular division of the eighth cranial nerve. The vestibular nucleus on each side is divided into 4 sub-nuclei: the superior vestibular nucleus and medial vestibular nucleus (both responsible for the vestibulo-ocular reflex [VOR]), lateral vestibular nucleus (responsible for the vestibulospinal reflex [VSR]) and descending vestibular nucleus (connection mainly with the cerebellum). Some nuclei receive only primary vestibular afferents, but most receive afferents from the cerebellum, reticular formation, spinal cord, and contralateral vestibular nuclei. The projections from the vestibular nuclei extend to the cerebellum, extraocular nuclei, and spinal cord [8]. Any perturbation induces static as well as dynamic vestibular imbalance, therefore causing postural (inclination of the head and body toward the affected side, incapacity to stabilize the posture while moving), perceptual (vertigo sensation with the deviation of subjective visual vertical, spatial disorientation) and oculomotor (spontaneous nystagmus, ocular tilt reaction) syndrome [9].

### Central compensation

The neurologic phenomenon of vestibular compensation is based on central nervous system reorganization leading to functional rehabilitation and recovery. Three main mechanisms are developed in humans – adaptation, substitution and habituation. Adaptation consists of regulation of neuronal activities mainly of the VOR. The VOR physiologically permits stabilization of the visual target into the fovea by displacement of the eye exactly opposite to head movement. Physiologic VOR gain (eye velocity divided by head velocity) is close to 1. After vestibular loss, the gain is reduced and oscillopsia occurs. Then, the adaptation increases the gain of the VOR to help stabilization of vision. Substitution can be described as a change in the importance of the proprioceptive and visual inputs implicated in gaze stabilization and equilibrium control. Finally, habituation implies teaching patients to avoid responding to a perturbation [9,10].

The static deficits, which include postural and oculomotor syndrome, disappear in a matter of days. The dynamic deficits combine a reduced gain and abnormal timing of VOR and vestibulospinal reflexes. They improve over a period of several weeks, and

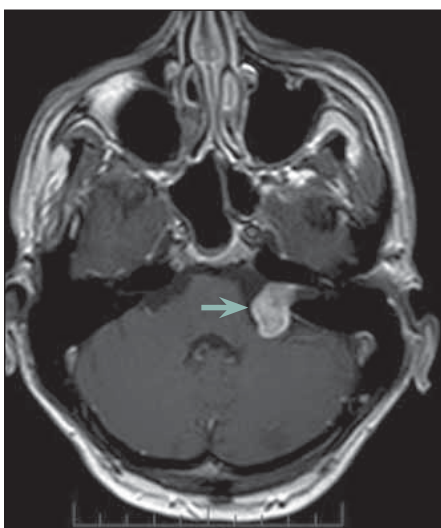


Fig. 1. MRI of the brain – vestibular schwannoma of cerebellopontine angle (arrow).  
Obr. 1. MR mozku – vestibulární schwannom v mostomožekovém koutu (šipka).

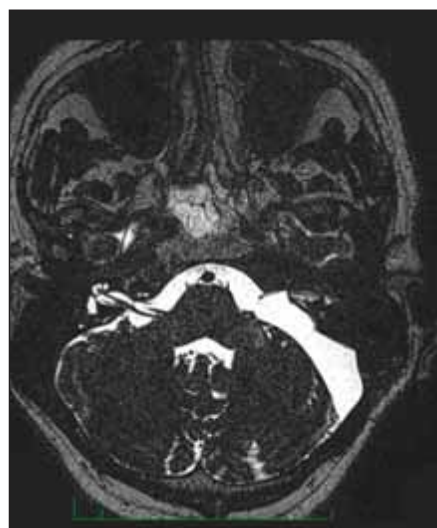

Fig. 2. MRI of the brain – 3 months after the vestibular schwannoma resection.  
Obr. 2. MR mozku – 3 měsíce po resekcii vestibulárního schwannomu.

their final compensation is more limited [10]. In the case of compensation of the dynamic component of VOR, the proper function of the cerebellum is very important [11]. On top of that, the whole process of central compensation is specific to a single patient. There are unalterable factors that can affect the final outcome, such as patient status (age, memory, general physical health, cognitive abilities, vision, neurologic or other internal comorbidities, and presence of psychological and anxiety disorders) and tumor specification (size and propagation). On the other hand, there are factors that can be the target of our intervention (vestibular rehabilitation, virtual reality [VR], prehabilitation) [9,12]. The level of compensation could be evaluated subjectively through questionnaires (e.g., Dizziness Handicap Inventory [DHI], The Penn Acoustic Neuroma Quality of Life Scale [PANQOL]) or objectively through physical examination (presence of spontaneous nystagmus, subjective visual vertical and clinical tests of stability during stance and gait) and electrophysiological examination (videonystagmography [VNG], calorization, video head impulse test [vHIT], vestibular evoked myogenic potentials [VEMP] and posturography) [12].

## Discussion

### Vestibular rehabilitation

Vestibular rehabilitation (VRHB) is a broad concept that helps accelerate the compensation process after an acute vestibular lesion and helps to correct the inappropriate equilibrium strategy in chronic vestibular disorders with its significance in the risk of falls and impact on quality of life. Since it is crucial not to systematize the programme but rather to keep a holistic approach, this justifies a careful and exhaustive evaluation of the patients before starting VRHB. There have been efforts to find some factors that can predict the result of compensation with promising outcomes, notably, the use of vHIT. It uses low-amplitude high-acceleration head jerks to elicit and test the VOR in the physiological range of the frequency response, exploring all semicircular canals and not only the horizontal ones as in the caloric test. The vHIT was shown to be able to reveal residual vestibular function, even in cases with complete loss of caloric response. In patients who underwent radical surgery and complete vestibular neurectomy, lower gain in vHIT on the operated side was presented. The hypothesis is that there is a higher gain

correlated with less extensive surgery and sparing of the inferior vestibular nerve. Low gain was correlated with a complete vestibular neurectomy, which may guide a rehabilitation strategy following surgery [13]. Rehabilitation (originating from a series of exercises invented by Cawthorne and Cooksey in the 1940's [14]) focuses on gaze stability and gait stability including both static and dynamic balance exercises. The aim of the exercises is the initial restoration of VOR and VSR (it works mainly on improving VOR gain). Secondly, it practices the correct form of posture and gait [15].

### Prehabilitation

Vestibular rehabilitation also completes the idea of prehabilitation. Intratympanic gentamicin (ITG) was initially developed by Schuknecht in 1956 in order to treat Meniere's disease [16]. Since then, we have learned that a low dose of ITG is primarily vestibulotoxic, so it can effectively control vertigo with few signs of cochlear toxicity [17]. Different instillation techniques have been used (a low dose multiple times daily or a higher dose once a day for 3–4 consecutive days), but the results do not seem to depend on how gentamicin is administered in the middle ear, as long as the procedure is performed under a microscope by a trained otologist [18,19]. Prehabilitation is done at least 6 weeks preoperatively, so the compensation process is strengthened by vestibular rehabilitation exercises which can lead to recovery before surgery. Pure tone audiometry and vHIT are obtained at baseline and after gentamicin treatment to ensure that the loss of function is sufficient [20,21]. There should be a significant VOR gain reduction and cumulative-saccadic-amplitude increase in all ipsilesional canals in vHIT. As the partial recovery of the vestibular system after three months post-instillation was observed, the timing of ITG and the surgery is essential [21].

Nevertheless, there is still a need for further research since the reason for relative sparing of anterior canal function in VS patients at baseline and after gentamicin application remains unclear. This suggests that the distinct semicircular canal (SCC) vulnerability to both local damages of nerve fibers due to tumor growth and vestibulotoxic substances is variable. Firstly, some VS patients could benefit from ITG prehabilitation such as VS patients with good peripheral vestibular function who experience sudden vestibular

loss of function after surgery. To reduce the effect of the dissection of the vestibular nerve, drug-induced ablation of ipsilateral peripheral vestibular function by using vestibulotoxic substances has been proposed as a pre-surgical treatment [22–24]. Specifically, there is a level-3 (evidence from evidence summaries developed from systematic reviews) recommendation from the Congress of Neurological Surgeons on pre-operative intratympanic gentamicin instillation to induce a controlled partial loss of SCC function and to improve postoperative mobility [25]. Secondly, patients with very small VSs (intrameatal/CPA  $\leq 15$  mm) that are recommended to wait but suffer from intractable vertigo can benefit from the procedure [26]. In addition, there are studies that emphasize the positive effect of ITG prehabilitation on patient expectations before the operation, thereby reducing postoperative anxiety and depression [27,28].

### Virtual reality

Sensory augmentation is a technique currently being explored to supplement compromised sensory information during VRHB to retrain sensorimotor function [29].

Optokinetic stimulation (OKS), or in other words an entire field moving visual scene is generated in an observer during a quiet stance, and has a sensation of self-motion which is contradictory with the perception of stationarity provided by otolithic and somatosensory receptors. Peripheral vision, rather than the central field, appears to be more sensitive to moving visual patterns and is responsible for the increased postural sway. The intact central nervous system can resolve the sensory mismatch and correct postural adjustments [28]. Optic flow is a type of three-dimensional OKS important for posture and balance perception, hence for the quality of life and space and motion awareness [27]. The sensitivity to optic flow can be decreased in a particular condition, e.g., in the elderly [30]. The optokinetic exercise is of particular value to treat visual dependence [9,31]. It increases the gain of VOR [15]. Individuals with vestibular disorders may experience visual vertigo, in which symptoms are provoked or exacerbated in visually rich environments (e.g., supermarkets, crowds, escalators). Visual vertigo can significantly improve when customized VRHB exercise is combined with repeated exposure to optokinetic stimuli [32]. In 2007, Cochrane's review deemed that evidence



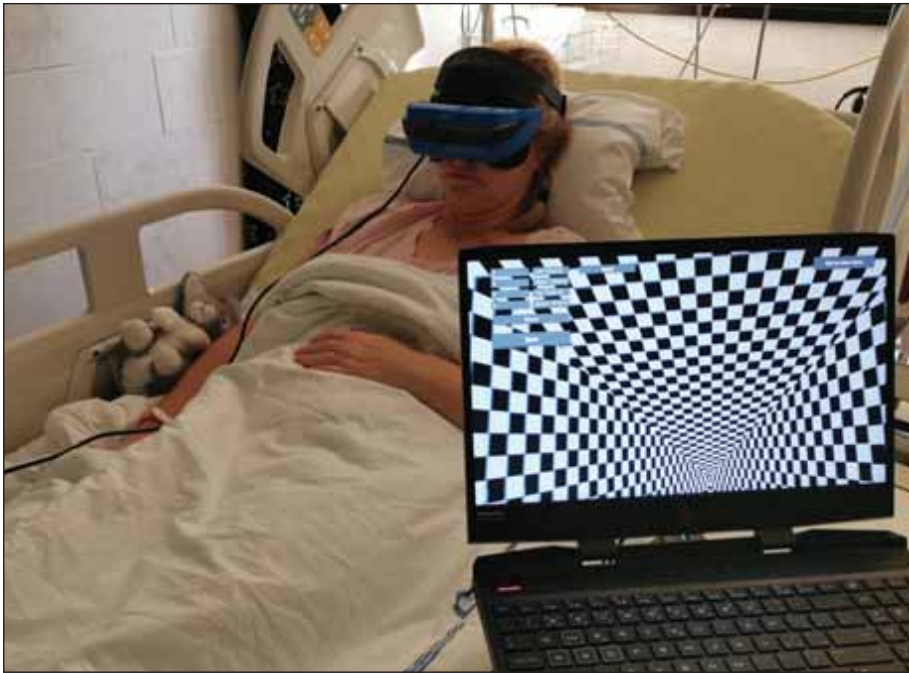


Fig. 3. Virtual reality in vestibular rehabilitation in patient after vestibular schwannoma surgery.

Obr. 3. Použití virtuální reality při vestibulární rehabilitaci u pacienta po operaci vestibulárního schwannomu.

was sufficient to support the addition of simulator-based activities to VRHB [33]. Given that motor skills can be learned in a virtual environment and applied later on in the real world, virtual settings can provide controlled and augmented feedback on motor performance; it is not surprising that medical rehabilitation began to use such settings heavily as therapeutic tools. It has been used as an aid in physical rehabilitation after stroke, in Parkinson's disease, in psychological therapies, and in children with autism [34,37]. Also, the National Aeronautics and Space Administration (NASA) has used this VR technology since 2005 and has taken it one step further. They hope to train the vestibular system to decrease motion sickness, increase function in disorienting environments, and speed up recovery when returning to gravity and solid ground [38]. VR is defined as the immersion of the user in an interactive environment that mimics reality [39]. There is a relationship between the duration of the exposure to VR environments and the magnitude of the therapeutic effects, suggesting that VR should last at least 150 min of cumulated exposure to ensure positive outcomes [40]. VR treats vestibular dysfunction by placing the subject in a simulated real-world through two different strategies. One utilizes outpatient sys-

tems that use head-mounted display VR devices (Fig. 3), and the second uses full body immersion inpatient systems [41]. VR can also be divided into either "passive" or "active". Passive rehabilitation requires only eye or head movements or staying immobile during the treatment. In contrast, active rehabilitation requests complete motions of the body or muscle groups in order to perform demanding movements (walking on a treadmill, doing steps, or yoga). Despite the fact that there has not been a significant observed difference in efficiency between active and passive protocols, technological devices allowing active mobilization of muscular groups can be acquired with little cost [40]. As for the head-mounted VR devices, it has been proved that they improve VOR gain, posturography scores, and patient self-reported measures when combined with conventional VRHB [42,43]. There have also been some efforts to use VR tools for measuring vestibular function, namely the otolithic system. The otolithic function enables us to perceive verticality and it can be assessed by a subjective visual vertical (SVV) [44]. SVV can be implemented by a special software application into a VR headset so it can be used at the bedside and collect different head and body position measurements [45].

There are also limitations of VR. The major one is the related cost. However, advances in the smartphone and gaming industry allow mass production of highly sophisticated low-cost VR systems that incorporate technology previously not accessible to most therapists and patients. Another consideration limiting the use of VR-based settings is cybersickness. Due to unnatural and sometimes conflicting multisensory stimuli, exposure to interactive virtual environments can cause discomfort (such as nausea or light-headedness) during or after the session. Anyway, the absence of reported side effects or adverse events so far supports the notion that VR is well tolerated and could be safely used in rehabilitation settings [40].

In contrast to VR, augmented reality (AR) augments the real-world environment instead of replacing it. Augmented reality eye-wear has been developed to reduce oscillopsia in patients with bilateral vestibular loss using real-time image stabilization [46].

### New trends

Apart from VR, there are various real-time biofeedback display modalities that can improve balance dysfunction. It is worth mentioning **electrotactile real-time biofeedback** (this is applied to a tongue, and it is a laboratory tool for VRHB) and mainly **vibrotactile sensory augmentation technology**. This system has the advantage of discreetly providing vibrotactile cues that lead to corrective postural responses. There has already been a cellphone-based vibrotactile feedback system developed for potential use in balance rehabilitation training in clinical and home environments. It comprises of a smartphone with an embedded tri-axial linear accelerometer, custom software to estimate body tilt, a "tactor bud" accessory that plugs into the headphone jack to provide vibrotactile cues of body tilt, and a battery [47].

**Vestibular implants** have also been developed to restore the lacking vestibular function. Current results demonstrate that electrical stimulation with implants is safe and can activate the vestibular system [48]. But since the vestibular portion of the eighth cranial nerve is dissected during the operation, it is suited only for bilateral vestibulopathy of other origin.

**Dual-tasking** is of particular interest in VRHB. The idea of competition for attention resources between a simple postural task of quietly standing and a cognitive activity

task leads to improvement of automatic postural control [9,31]. Also, current literature has mentioned the effectiveness of **tai-chi** and **aquatic physiotherapy** [49,50].

## Conclusion

The evidence is growing related to the positive effects of VRHB and the promising potential of VR in people with peripheral vestibular disorders. In patients with vestibular schwannoma, postoperative care can be extended and more precisely suited to each patient. From the current literature, the main criterion predicting treatment success and magnitude of symptom improvement so far is the total time spent in virtual time training. However, there are still some problems to fix in future studies – standardizing intervention protocols, using specific tools, documenting side effects, and defining profiles of patients susceptible to benefitting from VR-based rehabilitation.

## Funding

Supported by GAUK No. 192121, GAUK No. 874120 (Charles University in Prague), GAČR No. 19-08241S.

## Conflict of interest

The authors declare they have no potential conflicts of interest concerning drugs, products, or services used in the study.

## References

- Roosli C, Linthicum FH, Cureoglu S et al. What is the site of origin of cochleovestibular schwannomas? *Audiol Neurotol* 2012; 17(2): 121–125. doi: 10.1159/000331394.
- Propp JM, McCarthy BJ, Davis FG et al. Descriptive epidemiology of vestibular schwannomas. *Neuro Oncol* 2006; 8(1): 1–11. doi: 10.1215/S1522851704001097.
- Matthies C, Samii M. Management of 1000 vestibular schwannomas (acoustic neuromas): clinical presentation. *Neurosurgery* 1997; 40(1): 1–10. doi: 10.1097/0006123-199701000-00001.
- Torres Maldonado S, Naples JG, Fathy R et al. Recent trends in vestibular schwannoma management: an 11-year analysis of the National Cancer Database. *Otolaryngol Head Neck Surg* 2019; 161(1): 137–143. doi: 10.1177/0194599819835495.
- Arthurs BJ, Fairbanks RK, Demakas JJ et al. A review of treatment modalities for vestibular schwannoma. *Neurosurg Rev* 2011; 34(3): 265–279. doi: 10.1007/s10143-011-0307-8.
- Nellis JC, Sharon JD, Pross SE et al. Multifactor influences of shared decision-making in acoustic neuroma treatment. *Otol Neurotol* 2017; 38(3): 392–399. doi: 10.1097/MAO.0000000000001292.
- Betka J, Zverina E, Lisy J et al. Vestibular schwannoma. *Otorhinolaryngol Foniatr* 2008; 57(4): 221–225.
- Lui F, Foris LA, Willner K et al. Central vertigo. *J Int Comm Radiat Units Meas* 2022; 14(2): 1–160.
- Deveze A, Bernard-Demanze L, Xavier F et al. Vestibular compensation and vestibular rehabilitation. Current concepts and new trends. *Neurophysiol Clin* 2014; 44(1): 49–57. doi: 10.1016/j.neucli.2013.10.138.
- Vidal PP, De Waele C, Vibert N et al. Vestibular compensation revisited. *Otolaryngol Head Neck Surg* 1998; 119(1): 34–42. doi: 10.1016/S0194-5998(98)70171-8.
- Cullen KE, Minor LB, Beraneck M et al. Neural substrates underlying vestibular compensation: contribution of peripheral versus central processing. *J Vestib Res* 2009; 19(5–6): 171–182. doi: 10.3233/VES-2009-0357.
- Balatková Z. Faktory ovlivňující vestibulární kompenzaci u pacientů po operaci vestibulárního schwannomu. [online]. Available from: <https://dspace.cuni.cz/handle/20.500.11956/109342>.
- Černý R, Balatková Z, Hrubá S et al. Residual vestibular function after vestibular schwannoma surgery. *Neurochirurgie* 2020; 66(2): 80–84. doi: 10.1016/j.neu-chi.2019.10.008.
- Cooksey S. Rehabilitation in vestibular injuries. In: Brock S (ed). *Injuries of skull, brain and spinal cord*. Baltimore: The Williams & Wilkins Co. 1943.
- Čada Z, Černý R, Čákr O. Vestibulární rehabilitace. In: *Závratě*. Havlíčkův Brod: Tobiáš 2017: 168–171.
- Schuknecht HF. Ablation therapy in the management of Menière's disease. *Acta Otolaryngol Suppl* 1957; 132: 1–42.
- Salt AN, Gill RM, Plontke SK. Dependence of hearing changes on the dose of intratympanically applied gentamicin: a meta-analysis using mathematical simulations of clinical drug delivery protocols. *Laryngoscope* 2008; 118(10): 1793–1800. doi: 10.1097/MLG.0b013e31817d01cd.
- Nedzelski JM, Schessel DA, Bryce GE et al. Chemical labyrinthectomy: local application of gentamicin for the treatment of unilateral Menière's disease. *Am J Otol* 1992; 13(1): 18–22.
- Ödkvist LM, Bergenius J, Möller C et al. When and how to use gentamicin in the treatment of Menière's disease. *Acta Otolaryngol* 1997; 526: 54–57. doi: 10.3109/00016489709124023.
- Čada Z, Balatková Z, Chovanec M et al. Vertigo perception and quality of life in patients after surgical treatment of vestibular schwannoma with pre-treatment prehabilitation by chemical vestibular ablation. *Biomed Res Int* 2016; 2016: 6767216. doi: 10.1155/2016/6767216.
- Tarnutzer AA, Bockisch CJ, Buffone E et al. Pre-habilitation before vestibular schwannoma surgery – impact of intratympanic gentamicin application on the vestibulo-ocular reflex. *Front Neurol* 2021; 12: 633356. doi: 10.3389/fneur.2021.633356.
- Magnusson M, Kahlon B, Karlberg M et al. Vestibular "PREHAB." *Ann N Y Acad Sci* 2009; 1164: 257–262. doi: 10.1111/j.1749-6632.2009.03778.x.
- Tjernström F, Fransson PA, Kahlon B et al. PREHAB vs. REHAB – presurgical treatment in vestibular schwannoma surgery enhances recovery of postural control better than postoperative rehabilitation: retrospective case series. *J Vestib Res* 2018; 27(5–6): 313–325. doi: 10.3233/VES-170626.
- Tjernström F, Fransson P-A, Kahlon B et al. Vestibular PREHAB and gentamicin before schwannoma surgery may improve long-term postural function. *J Neurol Neurosurg Psychiatry* 2009; 80(11): 1254–1260. doi: 10.1136/JNPP.2008.170878.
- Van Gompel JJ, Agazzi S, Carlson ML et al. Congress of neurological surgeons systematic review and evidence-based guidelines on emerging therapies for the treatment of patients with vestibular schwannomas. *Neurosurgery* 2018; 82(2): E52–E54. doi: 10.1093/neuros/nyx516.
- Yang J, Jia H, Li G et al. Intratympanic gentamicin for small vestibular schwannomas with intractable vertigo. *Otol Neurotol* 2018; 39(8): E699–E703. doi: 10.1097/MAO.0000000000001899.
- Balatková Z, Čada Z, Hrubá S et al. Assessment of visual sensation, psychiatric profile and quality of life following vestibular schwannoma surgery in patients prehabilitated by chemical vestibular ablation. *Biomed Pap* 2020; 164(4): 444–453. doi: 10.5507/bp.2019.056.
- Monzani D, Marchioni D, Bonetti S et al. Anxiety affects vestibulospinal function of labyrinthine-defective patients during horizontal optokinetic stimulation. *Acta Otorhinolaryngol Ital* 2004; 24(3): 117–124.
- Huang H, Wolf SL, He J. Recent developments in biofeedback for neuromotor rehabilitation. *J Neuroeng Rehabil* 2006; 3(1): 1–12. doi: 10.1186/1743-0003-3-1.
- O'Connor KW, Loughlin PJ, Redfern MS et al. Postural adaptations to repeated optic flow stimulation in older adults. *Gait Posture* 2008; 28(3): 385–391. doi: 10.1016/j.gaitpost.2008.01.010.
- Dunlap PM, Holmberg JM, Whitney SL. Vestibular rehabilitation: advances in peripheral and central vestibular disorders. *Curr Opin Neurol* 2019; 32(1): 137–144. doi: 10.1097/WCO.0000000000000632.
- Pavlou M, Kanegaonkar RG, Swapp D et al. The effect of virtual reality on visual vertigo symptoms in patients with peripheral vestibular dysfunction: a pilot study. *J Vestib Res* 2012; 22(5–6): 273–281. doi: 10.3233/VES-120462.
- Hillier SL, Hollohan V. Vestibular rehabilitation for unilateral peripheral vestibular dysfunction. *Cochrane Database Syst Rev* 2007; 4: CD005397. doi: 10.1002/14651858.CD005397.pub2.
- Rose FD, Attree EA, Brooks BM et al. Training in virtual environments: transfer to real world tasks and equivalence to real task training. *Ergonomics* 2000; 43(4): 494–511. doi: 10.1080/001401300184378.
- Feng H, Li C, Liu J et al. Virtual reality rehabilitation versus conventional physical therapy for improving balance and gait in Parkinson's disease patients: a randomized controlled trial. *Med Sci Monit* 2019; 25: 4186–4192. doi: 10.12659/MSM.916455.
- Maples-Keller JL, Bunnell BE, Kim SJ et al. The use of virtual reality technology in the treatment of anxiety and other psychiatric disorders. *Harv Rev Psychiatry* 2017; 25(3): 103–113. doi: 10.1097/HRP.0000000000000138.
- Ip HHS, Wong SWL, Chan DFY et al. Enhance emotional and social adaptation skills for children with autism spectrum disorder: a virtual reality enabled approach. *Comput Educ* 2018; 117: 1–15. doi: 10.1016/j.compedu.2017.09.010.
- Stroud KJ, Harm DL, Klaus DM. Preflight virtual reality training as a countermeasure for space motion sickness and disorientation. *Aviat Space Environ Med* 2005; 76(4): 352–356.
- Maggio MG, Latella D, Maresca G et al. Virtual reality and cognitive rehabilitation in people with stroke: an overview. *J Neurosci Nurs* 2019; 51(2): 101–105. doi: 10.1097/JNN.0000000000000423.
- Bergeron M, Lortie CL, Guittion MJ. Use of virtual reality tools for vestibular disorders rehabilitation: a comprehensive analysis. *Adv Med* 2015; 2015: 1–9. doi: 10.1155/2015/916735.
- Heffernan A, Abdelmalek M, Nunez DA. Virtual and augmented reality in the vestibular rehabilitation of peripheral vestibular disorders: systematic review and meta-analysis. *Sci Rep* 2021; 11(1): 17843. doi: 10.1038/s41598-021-97370-9.
- Viziano A, Micarelli A, Augimeri I et al. Long-term effects of vestibular rehabilitation and head-mounted gaming task procedure in unilateral vestibular hypofunction: a 12-month follow-up of a randomized controlled trial. *Clin Rehabil* 2019; 33(1): 24–33. doi: 10.1177/0269215518788598.
- Stankiewicz T, Gujski M, Niedzielski A et al. Virtual reality vestibular rehabilitation in 20 patients with vertigo due to peripheral vestibular dysfunction.

Med Sci Monit 2020; 26:e930182-1. doi: 10.12659/MSM.930182.

44. Sun DQ, Zuniga MG, Davalos-Bichara M et al. Evaluation of a bedside test of utricular function – the bucket test – in older individuals. Acta Otolaryngol 2014; 134(4): 382–389. doi: 10.3109/00016489.2013.867456.

45. Chiarovano E, McGarvie LA, Szmulewicz D et al. Subjective visual vertical in virtual reality (Curator SVV): validation and normative data. Virtual Real 2018; 22(4): 315–320. doi: 10.1007/S10055-018-0336-5.

46. Pothier DD, Hughes C, Dillon W et al. The use of real-time image stabilization and augmented reality eyewear in the treatment of oscillopsia. Otolaryngol Head Neck Surg 2012; 146(6): 966–971. doi: 10.1177/0194599811434708.

47. Lee BC, Kim J, Chen S et al. Cell phone based balance trainer. J Neuroeng Rehabil 2012; 9(1): 10. doi: 10.1186/1743-0003-9-10.

48. Guinand N, van de Berg R, Cavuscens S et al. Vestibular implants: 8 years of experience with electrical stimulation of the vestibular nerve in 11 patients with bilateral

vestibular loss. ORL J Otorhinolaryngol Relat Spec 2015; 77(4): 227–240. doi: 10.1159/000433554.

49. Huang HW, Nicholson N, Thomas S. Impact of tai chi exercise on balance disorders: a systematic review. Am J Audiol 2019; 28(2): 391–400. doi: 10.1044/2018\_AJA-18-0115.

50. Gabilan YPL, Perracini MR, Munhoz MSL et al. Aquatic physiotherapy for vestibular rehabilitation in patients with unilateral vestibular hypofunction: exploratory prospective study. J Vestib Res 2008; 18(2–3):139–146. doi: 10.3233/ves-2008-182-307.

## Poděkování partnerům České neurologické společnosti

### Platinoví partneři



### Zlatý partner



### Stříbrný partner



### Partneři tematické sekce CzechNeurOnline



Extrapramidové poruchy



Bolesti hlavy



Neuromuskulárního onemocnění  
a Neuroimunologie

### Partner mobilní aplikace

