

Accuracy and technical nuances of robotically assisted lumbosacral interbody fusions – results of 100 operated patients

Přesnost a technické zákonitosti roboticky asistované lumbosakrální meziobratlové fúze – výsledky 100 operovaných pacientů

Abstract

Aim: Retrospective observation analysis of pedicle screw accuracy, complications, surgical time, and technical nuances of 100 patients operated via the ExcelsiusGPS robotic system. **Methods:** One-hundred adult patients undergoing lumbosacral interbody fusion between 2021 and 2024. Patients underwent either open interbody fusion, minimally invasive interbody fusion, or open interbody fusion combined with a non-instrumented decompression. All surgeries were assisted by the ExcelsiusGPS robot, and an intraoperative control CT scan was performed in all cases. Patients were followed at 6-week, 3-month, and 6-month intervals. **Results:** A total of 418 pedicle screws were implanted and 413 (99%) had optimal placement (Gerzbein-Robbins A) with the remaining five having minor asymptomatic cortical breaches of the pedicle wall violation (Gerzbein-Robbins B). The superior pedicle wall was breached once, and the inferior pedicle wall was breached four times. In seven cases, the CT scan had to be repeated due to transferring errors between the CT and robotic platform, and in two cases, screw trajectories had to be replanned due to dynamic reference base shift during screw implantation. The mean surgical time was 154 min for single-level procedures and 202 min for multiple-level procedures; our study did not show a significant decrease in surgical time throughout the learning curve. During early follow-up, two patients underwent surgical revisions due to the presence of seromas. **Conclusion:** Second generation robotic platforms have a high percentage of optimally implanted pedicle screws decreasing malposition-related complications. The main drawback is an increase in surgical time due to set-up of the robotic and navigation platforms.

Souhrn

Cíl: Retrospektivní observační analýza přesnosti zavedení pedikulárních šroubů, komplikací, chirurgického času a technických zákonitostí 100 pacientů operovaných pomocí robotického systému ExcelsiusGPS. **Metodika:** Sto dospělých pacientů podstupující stabilizační výkony lumbosakrální páteře v průběhu období 2021–2024. Pacienti podstoupili jednu z tří možných operací – otevřená meziobratlová fúze, minimálně invazivní meziobratlová fúze nebo kombinace otevřené meziobratlové fúze s neinstrumentovanou mikrodekompresí. Všechny operační výkony byly provedeny za asistence robotického systému ExcelsiusGPS s následnou intraoperační kontrolní CT. Pacienti byli sledováni v intervalech 6 týdnů, 3 měsíců a 6 měsíců. **Výsledky:** Celkem bylo zavedeno 418 pedikulárních šroubů, z nichž 413 (99 %) mělo optimální zavedení (Gerzbein-Robbins A) a zbylých pět vykazovalo drobné asymptomatické narušení kortikalis stěny pediklu (Gerzbein-Robbins B). Jednou byla narušena horní hrana pediklu a ve čtyřech případech došlo k narušení spodní plochy pediklu. V sedmi případech bylo nutné opakovat navigační CT sken v důsledku chyb přenosu mezi CT a robotickou platformou, ve dvou případech bylo nutné přeplánovat trajektorie pedikulárních šroubů v důsledku pohybu dynamické reference v průběhu zavádění šroubů. Průměrný chirurgický čas byl 154 min pro jednoprostorový stabilizační výkon a 202 min pro víceúrovňový stabilizační výkon. Naše práce neprokázala významný pokles chirurgického času v obrazu učební křivky. V časném pooperačním období byla nutná revize dvou pacientů pro přítomnost seromu operační rány. **Závěr:** Druhá generace robotických systémů vykazuje vysokou přesnost zavádění pedikulárních šroubů, čímž snižuje výskyt komplikací souvisejících s malpozicí. Hlavní nevýhodou je prodloužení chirurgického času v důsledku nastavení robotické a navigační platformy.

The Editorial Board declares that the manuscript met the ICMJE "uniform requirements" for biomedical papers.

Redakční rada potvrzuje, že rukopis práce splnil ICMJE kritéria pro publikace zasílané do biomedicínských časopisů.

J. Lodin^{1,2}, M. Bolcha^{1,2},
M. Sameš¹, P. Vachata^{1,2}

¹ Department of Neurosurgery,
J. E. Purkyne University, Masaryk
Hospital Krajská Zdravotní a.s.,
Ústí nad Labem, Czech Republic

² Faculty of Medicine in Plzeň, Charles
University in Prague, Czech Republic



Jan Lodin, MD
Department of Neurosurgery
J. E. Purkyne University
Masaryk Hospital
Krajská Zdravotní a.s.
Sociální Péče 3316/12A
401 11 Ústí nad Labem
Czech Republic
e-mail: jan.lodin@kzcr.eu

Accepted for review: 16. 6. 2024

Accepted for print: 2. 10. 2024

Key words

robot – spine – accuracy – pedicle screw – surgical time

Klíčová slova

robot – páteř – přesnost – pedikulární šroub – chirurgický čas

Introduction

Pedicle screws are currently the mainstay of spine instrumentation, providing good stability by connecting the anterior and posterior spine elements. Nonetheless, pedicle screw malposition can be associated with neurovascular injuries or construct failure [1]. The initial freehand implantation was gradually supplemented by fluoroscopy, 3D navigation, and currently robotics [2]. The main rationale is increased implantation accuracy and decreased exposure of the posterior spine elements. The Israeli company Mazor robotics (Caesarea) developed the first Food and Drug Administra-

tion (FDA) approved robot SpineAssist (Summit Spine and Joint Centers) in 2004 [3]. Ever since, progressively improving robotic platforms have been introduced to the medical market including other companies such as Medtronic (Minneapolis MN, USA), Zimmer Biomet (Warsaw, IN, USA), or TINAVI Medical Technologies (Beijing, China) to mention a few. Nonetheless, robotic systems are expensive and require several supplements including specific instrumentation, navigation platforms, and intraoperative imaging. It is thus necessary to understand the added benefits and technical limitations of robotic systems compared to fluoroscopy and con-

ventional navigation. The following paper represents a single center experience with the first 100 robotically assisted lumbosacral spine fusions between 2021 and 2024. Primary endpoints include data concerning pedicle screw accuracy and surgical time; the secondary endpoint is a basic selection algorithm of patients suitable for robotically assisted spine surgery.

Methods

The following paper is a retrospective observation analysis of patients undergoing interbody fusion surgery between February 2021 and January 2024.

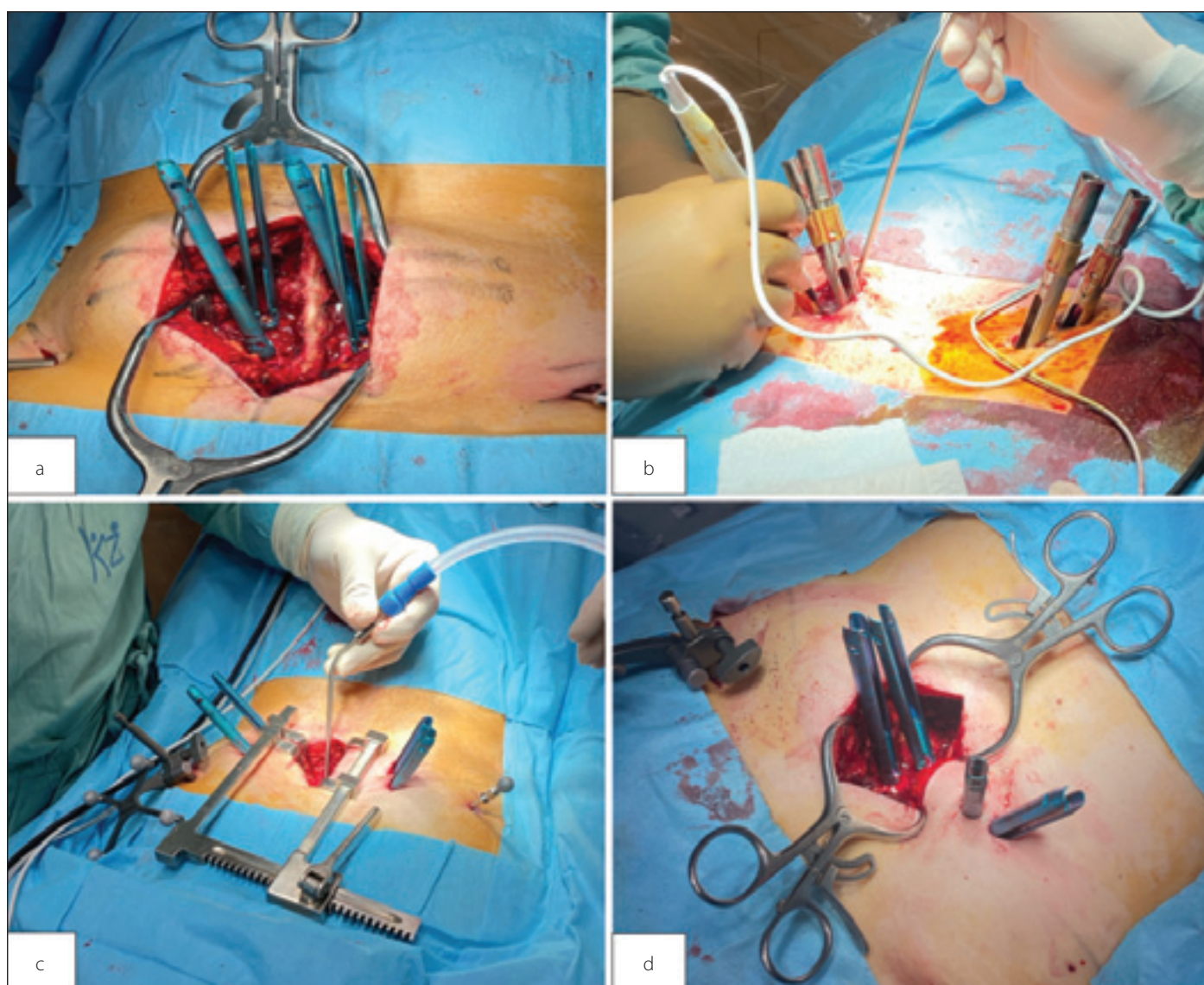


Fig. 1. Various robotically assisted surgical techniques. (a) Open surgical technique; (b) classic percutaneous transforaminal interbody fusion; (c) open posterior decompression with percutaneous pedicle screw implantation; (d) open over-the-top decompression with hybrid open/percutaneous pedicle screw implantation.

Obr. 1. Různé techniky robotické asistence. (a) Otevřená technika; (b) klasická perkutánní transforaminální meziobratlová fúze; (c) otevřená zadní dekomprese společně s perkutánně zavedenými pedikulárními šrouby; (d) otevřená „over-the-top“ dekomprese s hybridním otevřeným/zavřeným perkutánním pedikulárním šroubům.

Selection criteria

Patients selected for robotically assisted interbody fusion fulfilled general indication criteria for interbody fusion surgery at our department. All patients were required to have undergone standing and dynamic X-rays together with an MRI exam. In cases of degenerative spondylolisthesis, surgery was indicated in patients with neurological symptoms (nerve root irritation, hypesthesia, paresis, neurogenic claudication) after failure of conservative therapy (physiotherapy, periradicular intervention, and analgesics) in the presence of instability. Instability was defined as a minimal 3-mm difference between standing dynamic X-rays or standing X-rays and MRI. In borderline cases, indirect markers of instability were utilized such as edema of the facet joints, increased disc height, or the presence of synovial cysts. In cases of isthmic spondylolisthesis, surgery was indicated in patients with low-back pain or neurological symptoms refractory to conservative therapy for a minimum of 6 months. Patients with spine deformities, tumors, or infections were not included in our patient cohort. Furthermore, we did not include patients undergoing surgery of three

or more spinal segments or cases of dysplastic spondylolisthesis. Furthermore, a minimal 6-month follow-up was required in all cases.

Surgical procedures

Patients underwent three possible types of surgical interventions: open interbody fusion, minimally invasive interbody fusion, or open interbody fusion combined with a non-instrumented decompression. Open procedures involved muscle dissection of the paraspinal muscles and consequent implantation of pedicle screws via the open wound (Fig. 1a). Minimally invasive interbody fusion had several forms based on specific requirements of the patient. In cases of unilateral symptoms, it consisted of percutaneous implantation of pedicle screws and unilateral transforaminal interbody fusion between the extender sleeves on the symptomatic side (Fig. 1b). In cases of bilateral symptoms, the procedure was adapted by performing either percutaneous pedicle screw implantation with a small midline incision and hemilaminectomy (Fig. 1c), or unilateral percutaneous pedicle screw implantation on one side and open pedicle screw implantation on the other side with a hemilaminectomy (Fig. 1d). A total of three spine surgeons

performed the procedures. The specific nature of each procedure was decided by the operating surgeon based on each individual case. A small number of patients presented with stable stenosis in a segment adjacent to unstable spondylolisthesis. In these cases, open interbody fusion was performed in the unstable segment and non-instrumented microdecompression was performed in the adjacent stable stenotic segment. Surgical planning was performed intraoperatively via the O-arm™ (Medtronic, Minneapolis MN, USA) 3D imaging system. The scan was then transferred to the ExcelsiusGPS robotic system (Globus Medical, Audubon, PA, USA) and screw trajectories were planned by the operating surgeon. A control CT scan was performed intraoperatively after screw implantation to verify accurate placement of each pedicle screw using the Gertzbein-Robbins (GR) classification. Patients were followed up via the out-patient clinic by serial X-ray imaging at 6-week, 3-month, and 6-month intervals.

Results

A total of 100 patients underwent interbody fusion surgery between February 2021 and January 2024 (Tab. 1). Patients were predom-

Tab. 1. Demographic and surgical data (N = 100).

Mean age of surgery (range)		61.3 (32–79)	
Sex			
male		32%	
female		68%	
Listhesis			
degenerative		67%	
isthmic		33%	
Degree of listhesis (Meyerding)			
type I		90%	
type II		10%	
Spinal canal stenosis (Schizas)			
grade A1–A4		41%	
grade B		9%	
grade C		28%	
grade D		22%	
Invasiveness			
open surgery		66%	
minimally invasive surgery		34%	
Surgery type			
PLIF (1 level)		55%	
PLIF (2 level)		9%	
PLIF (1 level + decompression)		4%	
TLIF (1 level)		32%	
Surgical time (minutes)			
single-level surgery		154	
two-level surgery		202	
Pedicle screw accuracy (Gertzbein-Robbins)			
grade A		413 (99%)	
grade B		5 (1%)	
type C–E		0%	
Pedicle screw length			
bicortical implantation		408 (98%)	
subcortical implantation (1–5 mm below outer cortex)		10 (2%)	
Pedicle screw width			
6.5 mm width		398 (95%)	
5.5 mm width		20 (5%)	

N – number; PLIF – posterior lumbar interbody fusion; TLIF – transforaminal lumbar interbody fusion

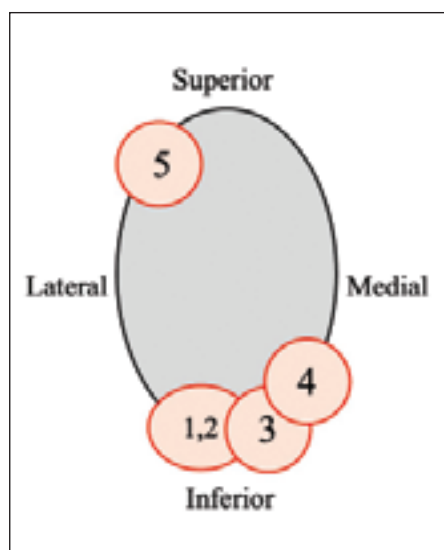


Fig. 2. Topographic representation of pedicle screw breaches.

Obr. 2. Topografická reprezentace narušení pediklů.

inantly females (68%) with a mean age of 61.3 years. The majority of cases were degenerative spondylolisthesis (67%) with the remainder being isthmic spondylolisthesis. A posterior lumbar approach (PLIF) was utilized in 68% of cases, and a transforaminal approach (TLIF) was used in 32% of cases. A minimally invasive percutaneous approach was performed in 44% of cases; the remainder were open approaches. The majority of cases (87%) were single level fusions; the remainder were combinations of multiple fusions or fusions with adjacent decompressions. In 93 cases, a single intraoperative CT scan was performed to plan surgical trajectories. In seven cases, the CT scan had to be repeated due to transferring errors, most commonly due to improper intraoperative CT marker (ICT) registration. In two cases, screw trajectories had to be replanned due to dynamic reference base (DRB) shift during screw implantation. Overall, 418 pedicle screws were implanted via the Excelsius robotic arm and 413 (99%) had optimal placement (GR A) with the remaining five having minor asymptomatic cortical breaches of the pedicle wall violation (GR B). For GR B cases, the superior pedicle wall was breached once, and the inferior pedicle wall was breached four times (Fig. 2). A PLIF approach was used for all cases of GR B screws. A total of three minor dural tears were reported, all of which were intraoperatively fixed via combinations of sutures, sponge sealants, and fibrin glue; no postop-

erative cerebrospinal fluid fistulas occurred. The mean surgical time was 154 min for single-level procedures and 202 min for multiple-level procedures. During early follow-up, three patients after PLIF procedures underwent early surgical revisions due to the presence of seromas. No other surgical revisions were performed. During long-term follow-up, there were no cases of hardware failure or other complications.

Discussion

Surgical accuracy

Increased surgical accuracy of pedicle screw insertion is a major motivation for obtaining a robotic platform. Published figures of robotic accuracy vary based on the type of surgery performed, specific robotic platform used (old vs new generation), and classification system used. Several large meta-analyses and reviews were published in the last 10 years with conflicting results. A recent analysis by Jung et al. showed that a key factor influencing screw precision was the specific robot model used [4]. Robotic systems are most commonly divided into first generation robots (Spine-Assist and Renaissance) and second generation robots (Mazor X [Medtronic, Minneapolis MN, USA], Excelsius GPS, ROSA Spine [Zimmer Biomet, Warsaw, IN, USA], and TINAVI [Beijing, China]) [5]. Whereas several authors reported similar results between fluoroscopic/freehand and robotic pedicle screw accuracy, these studies were dominantly focused on first generation robots [6–8]. One paper by Ringel et al. is renowned for being the only study reporting a lower precision of robotically assisted screws compared to freehand implantation [9]. The authors explain this result was most likely caused by the skiving phenomenon (slippage upon the superficial cortical bone) and possibly lower stability of the robotic arm, both of which are attributed to first generation robot platforms. Consequently, most studies involving second generation robots demonstrated their superiority in screw implantation [10–19]. Studies by Feng et al., Zhang et al., Cui et al., Wang et al., and Zhang et al. demonstrated robotic superiority only for GR A screws [14,16–19], whereas Le et al., Han et al., Yan et al., and Su et al. showed superiority of robotics for implanting GR A and B screws compared to fluoroscopic/freehand techniques [10–13]. When comparing robotic and conventional CT navigation techniques, the results are less clear, with Khan et al. showing no dif-

ference between both techniques, whereas Romagna et al. clearly demonstrated robotic superiority [20,21]. Literary values of optimal (GR A) pedicle screw implantation for second generation robots range from 90–99% and clinically acceptable (GR B) implantation ranges from 98–100% [10–19]. Our results support these findings as 99% of screws were GR A and 100% were GR A or GR B. The 5 cases where minor cortical breaches most likely occurred due to a minor skiving phenomenon described by Ringel et al., were all located in line with the perpendicular axis of the high-speed drill (4 inferiorly and 1 superiorly). Although all cases of GR B occurred in the PLIF group, we do not consider this to be a major risk factor, as this approach was utilized in a higher percentage of cases (68%) and the incidence of GR B screws was extremely low (1%). The high degree of accuracy meant we were able to safely implant the longest and widest possible screw into each pedicle, which is shown by the high percentage of bicortical (98%) and large diameter (95%) screws.

Surgical time

A major drawback of robotic surgery is an increase in procedure time due to the setup of components necessary for robotic surgery. These include setup and draping of the navigation system, robotic arm, robotic platform, navigated robotic instruments, image transfers between the navigation and robotic platforms, control CT scan, and the presence of a learning curve. Authors such as Yu et al. and Akazawa et al. demonstrated that 18–25 robotic spine cases were necessary for a single surgeon to pass the learning curve, after which times associated with specific robotic steps progressively decreased [22,23]. In our study, mean surgical time was 154 min for a single segment procedure and 202 min for double segment surgery. Unfortunately, we did not observe a progressive decrease in surgery time in our study (Fig. 3). Reasons for this are most likely the division of procedures between three surgeons, various surgical strategies and experimentation (open surgery, several minimally invasive techniques, etc.), and an initial selection bias of simpler cases. Finally, surgical times further increased when technical errors occurred. A total of 7 cases required additional navigation scans due to transfer errors and 2 cases required replanning of screw trajectories because of DRB shift. Although the surgical time was

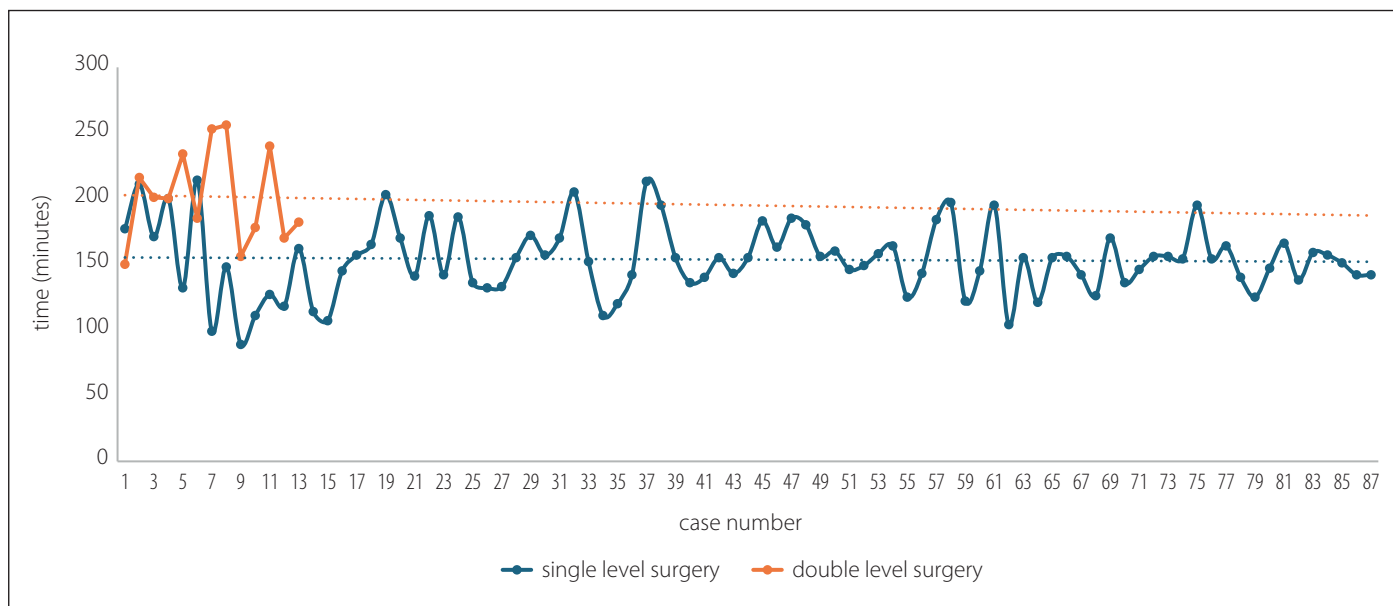


Fig. 3. Surgical time dynamics.

Obr. 3. Dynamika času operace.

longer in these cases, they represent examples of correctly functioning safety mechanisms, protecting the patient from screw malposition. The presence of these controls is most likely the reason why second-generation robot platforms have less screw malposition compared to their first-generation counterparts.

Selection algorithm

Our department performed robotically assisted fusion surgery by utilizing the ExcelsiusGPS robotic system (Globus Medical). Prior to the implementation of robotics, we standardly performed these surgeries using O-arm™ (Medtronic, Minneapolis, MN, USA) navigation for a total of 14 years. Thus, our department had sufficient experience of using navigation for spine procedures. We consider this to be a key prerequisite for the implementation of robotics, as it facilitates learning curves for the operating surgeons and supporting staff in the primary surgical set up. Initially, all patients indicated for open spinal fusion were converted to robotically assisted surgery. With further experience, we postulated a selection algorithm due to the technical limitations and advantages of robotic surgery.

Technical limitations

Robotic surgery utilizes a combination of three navigation components (Fig. 4). The DRB acts as a classical four-point navigation reference frame. The Surveillance is an

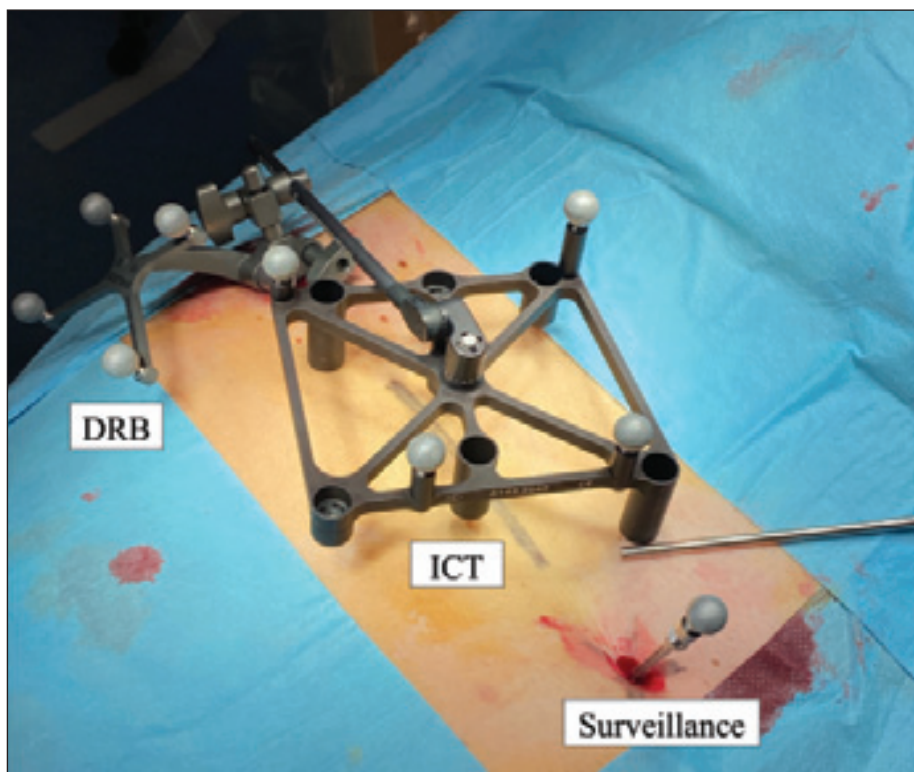


Fig. 4. Navigation components of robotic surgery the DRB, the ICT and the Surveillance.

DRB – dynamic reference base; ICT – intraoperative CT frame

Obr. 4. Navigační komponenty robotické chirurgie DRB, ICT a Surveillance.

DRB – dynamická referenční základna; ICT – intraoperační CT rám

additional reference frame, which monitors a fixed distance between itself and the DRB. The intraoperative CT frame (ICT) is a temporary reference with 7 optic markers, which allow patient registration without the need

of fiduciary anatomical landmarks, as they are absent on the patient's flat back. The DRB and Surveillance references are fixated within the iliac crests, whereas the ICT is temporarily fixed on the DRB parallel to the pa-

tient's back. In order to perform the intraoperative CT for trajectory planning, the 7 optic markers of the ICT must be visible on the scan together with all of the vertebral segments being fused. This can be problematic in extremely obese patients, as a thick layer of subcutaneous tissue doesn't allow the visualization of both the ICT and vertebrae. Furthermore, the increased amount of tissue in obese patients results in an unstable operative field leading to movement errors of the Surveillance marker. As a result, morbidly obese patients are problematic candidates for robotic surgery.

When performing open surgical procedures, the pedicle screw trajectory had to avoid edges of the surgical wound, as pressure upon wound edges would shift the surgical field, thus altering the final screw trajectory. The solution to this problem was either decreased convergence of the screw trajectory via the facet joint or expanding the surgical approach by increasing wound length. This drawback was negated if two or more spine segments were being fused, as this allowed increased dilation of the surgical wound. Thus, the invasiveness of robotic procedures decreases with an increase in construct length but can paradoxically be more invasive in mono-segmental fusion surgery.

Technical advantages

A major benefit of robotic surgery are the advanced planning options for pedicle screw implantation. These allow optimization of screw trajectories with optimal convergence, bone contact, and facet joint sparing. Furthermore, 3D visualization of the final construct allows optimal alignment of screw heads facilitating their final connection. It also allows optimal correction of pathological spine alignment due to the absence of eccentric screw placement. As such, robotic surgery is advantageous when performing longer constructs with pathological spine alignment.

A further advantage of robotic surgery is stability of the robotic arm, which prevents slippage of instrumentation during screw implantation. This is particularly helpful when implanting screws into pathological pedicles such as sclerotic pedicles or pedicles infiltrated by tumors. The controlled use of a high-speed drill allows safe penetration through abnormal bone facilitating screw implantation. Furthermore, the robotic arm is beneficial when implanting pedicle

screws via extreme trajectories, such as patients with hyperlordosis and spondylolisthesis of the L5/S1 spinal segment. In these cases, added support of the robotic arm prevents the slippage of screws into suboptimal trajectories. Therefore, patients with pathological pedicles or atypical trajectories of pedicle screws are especially suitable for robotic surgery.

Complication analysis

In our patient cohort, the sole intraoperative complications reported were intraoperative dural tears, which occurred in three cases of open PLIF surgery. The tears were the result of dural sac and nerve root manipulation during surgical decompression and were not caused by pedicle screw malposition. As such, we do not consider these complications to be associated with robotic assistance during surgery, but general complications of interbody fusion surgery. Furthermore, we reported three different cases of seromas occurring in the early postoperative period, which required surgical revision due to continuing wound secretion. Again, all cases occurred following open PLIF surgery, which has been shown to have a higher risk of durotomy and wound complications compared to minimally invasive procedures [24,25].

Conclusion

In conclusion, our study confirmed that second generation robotic platforms demonstrated a very high precision of acceptable pedicle screw implantation. This not only decreases the percentage of malposition related complications, but also allows safe implantation of biomechanically superior instrumentation. The main drawback is an increase in surgical time due to a high number of surgical components, the presence of a learning curve, and technical errors associated with novel technologies. Additionally, we provided a crude selection algorithm for robotic spine surgery, wherein patients with pathological vertebral structure, atypical pedicle trajectories, minimally invasive cases, and cases requiring longer constructs are especially suitable candidates. Conversely, the advantages of robotic surgery are less pronounced in morbidly obese patients and cases requiring open single level procedures. Overall, robotically assisted spine surgery is not suitable for every patient and further optimization of indications will surely continue.

Declarations and disclosures

The authors declare that they have no known competing financial interests or personal relationships that could have appeared to influence the work reported in this paper. The study was performed in accordance with the Helsinki declaration from 1975 and its revisions (2004 and 2008). Patients signed informed consent with all diagnostic and therapeutic procedures; ethics committee consent is not required.

Financial support

This study was supported by the internal hospital grant of Krajská Zdravotní a.s. IGA-KZ-2021-1-6.

Conflict of interest

The authors declare they have no potential conflicts of interest concerning drugs, products, or services used in the study.

References

1. Akhaddar A, Atmane el M. Pedicle screw malposition following spinal lumbar injury. *Pan Afr Med J* 2014; 17: 266. doi: 10.11604/pamj.2014.17.266.4120.
2. Huang M, Tetreault TA, Vaishnav A et al. The current state of navigation in robotic spine surgery. *Ann Transl Med* 2021; 9(1): 86. doi: 10.21037/atm-2020-101-07.
3. Alluri RK, Avrumova F, Sivaganesan A et al. Overview of robotic technology in spine surgery. *HSS J* 2021; 17(3): 308–316. doi: 10.1177/15563316211026647.
4. Jung B, Han J, Shahsavarani S et al. Robotic-assisted versus fluoroscopic-guided surgery on the accuracy of spine pedicle screw placement: a systematic review and meta-analysis. *Cureus* 2024; 16(2): e54969. doi: 10.7759/cureus.54969.
5. Ong V, Swan AR, Sheppard JP et al. A comparison of spinal robotic systems and pedicle screw accuracy rates: review of literature and meta-analysis. *Asian J Neurosurg* 2022; 17(4): 547–556. doi: 10.1055/s-0042-1757628.
6. Hyun SJ, Kim KJ, Jahng TA et al. Minimally invasive robotic versus open fluoroscopic-guided spinal instrumented fusions: a randomized controlled trial. *Spine (Phila Pa 1976)* 2017; 42(6): 353–358. doi: 10.1097/BRS.0000000000001778.
7. Lonjon N, Chan-Seng E, Costalat V et al. Robot-assisted spine surgery: feasibility study through a prospective case-matched analysis. *Eur Spine J* 2016; 25(3): 947–955. doi: 10.1007/s00586-015-3758-8.
8. Solomiichuk V, Fleischhammer J, Molliqaj G et al. Robotic versus fluoroscopy-guided pedicle screw insertion for metastatic spinal disease: a matched-cohort comparison. *Neurosurg Focus* 2017; 42(5): E13. doi: 10.3171/2017.3.FOCUS1710.
9. Ringel F, Stuer C, Reinke A et al. Accuracy of robot-assisted placement of lumbar and sacral pedicle screws: a prospective randomized comparison to conventional freehand screw implantation. *Spine (Phila Pa 1976)* 2012; 37(8): E496–E501. doi: 10.1097/BRS.0b013e31824b7767.
10. Su XJ, Lv ZD, Chen Z et al. Comparison of accuracy and clinical outcomes of robot-assisted versus fluoroscopy-guided pedicle screw placement in posterior cervical surgery. *Global Spine J* 2022; 12(4): 620–626. doi: 10.1177/2192568220960406.
11. Yan K, Zhang Q, Tian W. Comparison of accuracy and safety between second-generation TiRobot-assisted and free-hand thoracolumbar pedicle screw placement. *BMC Surg* 2022; 22(1): 275. doi: 10.1186/s12893-022-01723-8.
12. Le X, Tian W, Shi Z et al. Robot-assisted versus fluoroscopy-assisted cortical bone trajectory screw instrumentation in lumbar spinal surgery: a matched-cohort

comparison. *World Neurosurg* 2018; 120: e745–e751. doi: 10.1016/j.wneu.2018.08.157.

13. Han X, Tian W, Liu Y et al. Safety and accuracy of robot-assisted versus fluoroscopy-assisted pedicle screw insertion in thoracolumbar spinal surgery: a prospective randomized controlled trial. *J Neurosurg Spine* 2019; 30(5): 615–622. doi: 10.3171/2018.10.SPINE.18487.

14. Feng S, Tian W, Sun Y et al. Effect of robot-assisted surgery on lumbar pedicle screw internal fixation in patients with osteoporosis. *World Neurosurg* 2019; 125: e1057–e1062. doi: 10.1016/j.wneu.2019.01.243.

15. Zhang JN, Fan Y, He X et al. Comparison of robot-assisted and freehand pedicle screw placement for lumbar revision surgery. *Int Orthop* 2021; 45(6): 1531–1538. doi: 10.1007/s00264-020-04825-1.

16. Cui GY, Han XG, Wei Y et al. Robot-assisted minimally invasive transforaminal lumbar interbody fusion in the treatment of lumbar spondylolisthesis. *Orthop Surg* 2021; 13(7): 1960–1968. doi: 10.1111/os.13044.

17. Wang L, Li C, Wang Z et al. Comparison of robot-assisted versus fluoroscopy-assisted minimally invasive

transforaminal lumbar interbody fusion for degenerative lumbar spinal diseases: 2-year follow-up. *J Robot Surg* 2023; 17(2): 473–485. doi: 10.1007/s11701-022-01442-5.

18. Zhang RJ, Zhou LP, Zhang HQ et al. Rates and risk factors of intrapedicular accuracy and cranial facet joint violation among robot-assisted, fluoroscopy-guided percutaneous, and freehand techniques in pedicle screw fixation of thoracolumbar fractures: a comparative cohort study. *BMC Surg* 2022; 22(1): 52. doi: 10.1186/s12893-022-01502-5.

19. Zhang Q, Xu YF, Tian W et al. Comparison of superior-level facet joint violations between robot-assisted percutaneous pedicle screw placement and conventional open fluoroscopic-guided pedicle screw placement. *Orthop Surg* 2019; 11(5): 850–856. doi: 10.1111/os.12534.

20. Romagna A, Sperker S, Lumenta C et al. Robot-assisted versus navigated transpedicular spine fusion: a comparative study. *Int J Med Robot* 2023; 19(2): e2500. doi: 10.1002/rcs.2500.

21. Khan A, Meyers JE, Yavorek S et al. Comparing next-generation robotic technology with 3-dimensional

computed tomography navigation technology for the insertion of posterior pedicle screws. *World Neurosurg* 2019; 123: e474–e481. doi: 10.1016/j.wneu.2018.11.190.

22. Akazawa T, Torii Y, Ueno J et al. Learning curves for robotic-assisted spine surgery: an analysis of the time taken for screw insertion, robot setting, registration, and fluoroscopy. *Eur J Orthop Surg Traumatol* 2024; 34(1): 127–134. doi: 10.1007/s00590-023-03630-x.

23. Yu J, Zhang Q, Fan MX, et al. Learning curves of robot-assisted pedicle screw fixations based on the cumulative sum test. *World J Clin Cases* 2021; 9(33): 10134–10142. doi: 10.12998/wjcc.v9.i33.10134.

24. Terman SW, Yee TJ, Lau D et al. Minimally invasive versus open transforaminal lumbar interbody fusion: comparison of clinical outcomes among obese patients. *J Neurosurg Spine* 2014; 20(6): 644–652. doi: 10.3171/2014.2.SPINE13794.

25. Lau D, Khan A, Terman SW et al. Comparison of perioperative outcomes following open versus minimally invasive transforaminal lumbar interbody fusion in obese patients. *Neurosurg Focus* 2013; 35(2): E10. doi: 10.3171/2013.5.FOCUS13154.

Impakt faktor časopisu Česká a slovenská neurologie a neurochirurgie pro rok 2023 činí **0,3**.