proLékaře.cz | 18.3.2026

doi: 10.48095/cccsnn202650

Novel familial *SGCE* gene variant associated with myoclonus-dystonia and concomitant multiple sclerosis?

Nová familiární varianta genu *SGCE* spojená s myoklonickou dystonií a souběžnou roztroušenou sklerózou?

The Editorial Board declares that the manuscript met the ICMJE "uniform requirements" for biomedical papers.
Redakční rada potvrzuje, že rukopis práce splnil ICMJE kritéria pro publikace zasílané do biomedicínských časopisů.

M. Wayhelová[1], I. Šrotová[2,3], E. Minks[4,5], J. Martinková[1], A. Křepelová[1], M. Macek Jr[1], S. Flašarová[3], M. Hladíková[2,3], M. Petrášová[2,3], E. Vlčková[2,3], P. Štourač[2,3]

[1] Department of Biology and Medical Genetics, Second Faculty of Medicine, Charles University and Motol University Hospital, Prague, Czech Republic
[2] Faculty of Medicine, Masaryk University Brno, Brno, Czech Republic
[3] Department of Neurology, Faculty of Medicine, Masaryk University, University Hospital Brno, Brno, Czech Republic
[4] First Department of Neurology, St. Anne's University Hospital Brno, Brno, Czech Republic
[5] Neurology, TERAneuro s.r.o., Židlochovice, Czech Republic

Markéta Wayhelová and Iva Šrotová contributed equally and share the first authorship.

✉
Iva Šrotová, MD, PhD
Department of Neurology
Faculty of Medicine
Masaryk University
University Hospital Brno
Jihlavská 20
625 00 Brno
Czech Republic
e-mail: srotova.iva@fnbrno.cz

Accepted for review: 21. 9. 2025
Accepted for print: 28. 1. 2026

Dear Editor,
We report on a novel familial variant in the *SGCE* gene associated with myoclonus-dystonia (MD), which occurred concomitantly with multiple sclerosis (MS). MD is a movement disorder characterized by a combination of rapid, brief muscle contractions (myoclonus). The myoclonic jerks typically affect the neck, trunk, and upper limbs, with less common involvement of the legs. Approximately 50% of the affected individuals have additional focal or segmental dystonia, presenting as cervical dystonia and/or writer's cramps. Non-motor features may include an increased risk of alcohol abuse, obsessive-compulsive disorder, and anxiety disorders [1]. Symptom onset is usually in the first decade of life and almost always by the age of 20 years.

Pathogenic variants in ξ-sarcoglycan gene *SGCE* represent the most frequent genetic cause of MD with maternal imprinting. Therefore, clinical manifestation is dependent on the transmission of pathogenic variants in the paternal lineage [2]. Clinical diagnosis of MD is then confirmed by the presence of a heterozygous pathogenic variant in the *SGCE* gene.

A male proband had a history of myoclonic jerks in the left upper limb and leg, focal cervical dystonia, and writer's cramp. First symptoms appeared at the age of 12 years, did not progress over time, and did not interfere with most of his daily activities. Similar symptoms were already present (or developed later) in his father, sister and one of his daughters (Tab. 1). At the age of 33 years, the patient also developed panic attacks and anxiety disorder, probably related to MD. Therefore, the highly specific phenotype was then indicative of a molecular genetic analysis of the *SGCE* gene of which rare pathogenic variants are well recognized as the primary molecular cause of MD [3].

At the age of 48 years, new symptoms of weakness and paresthesia in the left-sided extremities developed within a week. MRI showed the presence of supratentorial (T2-hyperintense periventricular and 2 juxtacortical lesions) and infratentorial brain lesions, and one spinal cord lesion at the C3/C4 level susceptive of MS. A CSF examination revealed the presence of 10 oligoclonal bands (OCBs), while no OCBs were found in corresponding samples. The diagnosis of MS was established, and the patient was treated with high-dose steroids and ofatumumab (Tab. 1). Clinical symptoms of MS completely resolved within two weeks. Follow-up brain MRI showed no new lesions or progression of the already described ones; moreover, it showed a reduction of one lesion present in the diagnostic brain MRI. Patient has adhered to the therapy and tolerated it well (Fig. 1).

Molecular genetic analyses of the *SGCE* gene were performed in the proband and his affected relatives. Afterwards, a novel heterozygous variant NC_000007.14(NM_003919.2):c.663-3C>A in intron 5 of the *SGCE* gene confirmed the diagnosis of MD when the patient was 47 years old. Its deleterious effect on splicing was predicted using *in silico* tools SpliceAI [4] and Human Splicing Finder (HSF) [5]. The subsequent RT-PCR (Thermo Fisher Scientific, Waltham, MA, USA) confirmed the deleterious effect on splicing as the region of interest, and the control region of

proLékaře.cz | 18.3.2026

Tab. 1. Symptoms of myoclonus-dystonia and its treatment in proband and his family. All mentioned individuals carry a heterozygous variant c.663-3C>A, p.? in the intron 5 of the *SGCE* gene (NM_003919.2).

Family member	Age of the first symptoms	Clinical features	Treatment
Proband	childhood (12 years)	myoclonic jerks of the left upper limb and leg, focal cervical dystonia and writer´s cramp	MS: corticosteroid therapy (3 g of intravenous methylprednisolone over the period of three days) + long-term treatment with ofatumumab (20 mg subcutaneously once a month)
Proband's father	childhood (10 years)	myoclonic jerks of hands and cervical dystonia	neurosurgical surgery (in 1967) – coagulation of subthalamus with partial effect
Proband's sister	childhood (15 years)	myoclonic jerks of the right hand and task specific dystonia of the right hand	0
Proband's daughter	childhood (2 years)	myoclonic jerks of the upper limbs and right leg, cervical dystonia	clonazepam

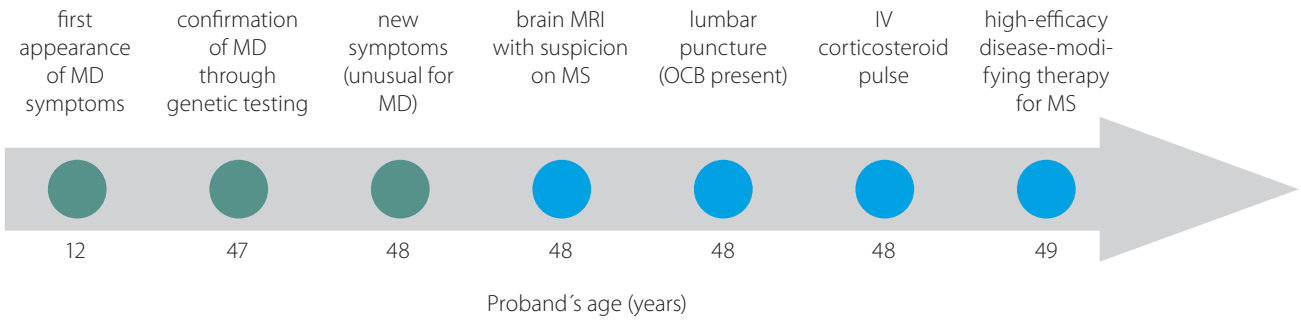

Fig. 1. Timeline of the diagnostic and therapeutic milestones during treatment.
green colour – events related to myoclonus-dystonia; blue colour – events related to multiple sclerosis
IV – intravenous; MD – myclonus-dystonia; OCB – oligoclonal bands

Obr. 1. Časová osa diagnostických a terapeutických milníků v průběhu léčby.
zelená barva – události související s myoklonem-dystonií; modrá barva – události související s roztroušenou sklerózou.
IV – intravenózní; MD – myoklonus-dystonie; OCB – oligoklonální pásy

the *SGCE* gene was amplified in an RNA sample from a healthy unrelated individual, but not from the patient. The experimental outputs are in full accordance with outputs of *in silico* prediction tools. The aberrant splicing leading to the partial or complete degradation of the altered transcripts of the paternal *SGCE* allele is a relatively common mechanism, causing the absence of a functional ξ-sarcoglycan as there are more than 25 different causative splicing variants in the ClinVar database [6] and multiple cases are published.

Therefore, the novel splicing variant NM_003919.2:c.663-3C>A on the borderline of intron 5 and exon 6 of the *SGCE* gene was confirmed as the molecular cause of MD in affected individuals in the reported family. To our best knowledge, this variant has not been identified and associated with MD so far. We concluded that the variant was likely responsible for the aberrant splicing. The aberrant transcripts expressed from the mutated paternal allele are likely completely degraded by the nonsense-mediated mRNA decay, leading to the loss of expression of the paternal allele and the absence of the functional protein ξ-sarcoglycan.

According to the authors' knowledge, this is the first published report of the coincidence of MS and MD. The main challenge in similar situations is to distinguish if new symptoms represent a complication or progression of the already known neurological condition or if there is a new neurological disease with a chance of co-incidence with the previously known disease.

The latter option was more probable since motor and sensory symptoms do not represent a common clinical manifestation of MD. For this reason, brain and cervical spinal cord MRI was performed. Patients with MD usually have a normal brain MRI [7]. Specific white matter abnormalities in MD can occur, but are mainly apparent in functional MRI of the subthalamic region of the brainstem [8]. The brain and cervical spinal cord MRI showed several supra- and infratentorial and spinal cord demyelinating lesions, which fulfilled McDonald's criteria for MS [9]. The CSF examination was performed with the finding of OCBs in the CSF (not present in serum) supportive of the MS diagnosis. The normal CSF finding with low levels of the serotonin metabolite, 5-hydroxyindoleacetic acid, is typical for MD (not tested in the proband) [10]. Based on radiological findings and negative clinical prognostic factors, highly

proLékaře.cz | 18.3.2026

effective corticosteroid therapy has been initiated. Motor and sensory symptoms of MS have completely resolved while MD remained unchanged. Patient's psychiatric symptoms are probably part of MD, although they may also be present in patients with MS [1,11].

The random co-occurrence of two independent diagnostic units, i.e., MD and MS, in our patient was thus the most probable explanation of his clinical problems. The presence of two independent clinical entities in the proband should be reflected for the initiation of appropriate therapy, if applicable, and long-term medical follow-up.

Financial support

Projekt Institucionální podpory FN Brno MZ ČR – RVO (FNBr – 65269705), projekt specifického výzkumu č. MUNI/A/1522/2024.

Conflict of interest

The authors declare they have no potential conflicts of interest concerning drugs, products, or services used in the study.

References

1. Hess CW, Raymond D, de Carvalho Aguiar P et al. Myoclonus-dystonia, obsessive-compulsive disorder, and alcohol dependence in SGCE mutation carriers. Neurology 2007; 68(7): 522–524. doi: 10.1212/01.wnl.0000253188.76092.06.

2. Grabowski M, Zimprich A, Lorenz-Depiereux B et al. The epsilon-sarcoglycan gene (SGCE), mutated in myoclonus-dystonia syndrome, is maternally imprinted. Eur J Hum Genet 2003; 11(2): 138–144. doi: 10.1038/sj.ejhg.5200938.

3. Cazurro-Gutiérrez A, Marcé-Grau A, Correa-Vela M et al. ε-Sarcoglycan: unraveling the myoclonus-dystonia gene. Mol Neurobiol 2021; 58(8): 3938–3952. doi: 10.1007/s12035-021-02391-0.

4. Jaganathan K, Kyriazopoulou Panagiotopoulou S et al. Predicting splicing from primary sequence with deep Learning. Cell 2019; 176(3): 535–548.e24. doi: 10.1016/j.cell.2018.12.015.

5. Desmet FO, Hamroun D, Lalande M et al. Human splicing finder: an online bioinformatics tool to predict splicing signals. Nucleic Acids Res 2009; 37(9): e67. doi: 10.1093/nar/gkp215.

6. Landrum MJ, Lee JM, Riley GR et al. ClinVar: public archive of relationships among sequence variation and human phenotype. Nucleic Acids Res 2014; 42(1): D980-D985. doi: 10.1093/nar/gkt1113.

7. Müller B, Hedrich K, Kock N et al. Evidence that paternal expression of the epsilon-sarcoglycan gene accounts for reduced penetrance in myoclonus-dystonia. Am J Hum Genet 2002; 71(6): 1303–1311. doi: 10.1086/344531.

8. van der Meer JN, Beukers RJ, van der Salm SM et al. White matter abnormalities in gene-positive myoclonus-dystonia. Mov Disord 2012; 27(13): 1666–1672. doi: 10.1002/mds.25128.

9. Thompson AJ, Banwell BL, Barkhof F et al. Diagnosis of multiple sclerosis: 2017 revisions of the McDonald criteria. Lancet Neurol 2018; 17(2): 162–173. doi: 10.1016/S1474-4422(17)30470-2.

10. Peall KJ, Ng J, Dy ME et al. Low CSF 5-HIAA in myoclonus dystonia. Mov Disord 2017; 32(11): 1647–1649. doi: 10.1002/mds.27117.

11. Peall KJ, Waite AJ, Blake DJ et al. Psychiatric disorders, myoclonus dystonia, and the epsilon-sarcoglycan gene: a systematic review. Mov Disord 2011; 26(10): 1939–1942. doi: 10.1002/mds.23791.