

Recurrent Ischemic Stroke in Systemic Sclerosis – a Case Report

Recidivující ischemická mozková příhoda při systémové skleróze – kazuistika

Abstract

Primary involvement of the central nervous system is rare in systemic sclerosis (SSc). We present a case of 55-year-old Chinese man with SSc suffering from persistent weakness of the upper left limb, accompanied by eyes gazing to right and dysarthria. Brain magnetic resonance imaging (MRI) confirmed ischemic lesions in right middle cerebral artery (MCA) territory. MRA reported a severe stenosis in the M1 portion of the right MCA. Despite oral prednisone and antiplatelet drugs daily, the patient suffered another ischemic stroke only one year later, presenting with gaze paralysis to the right and aphasia. Another brain MRI revealed acute ischemic lesions next to the left lateral ventricle and postischemic lesions in the right hemisphere. MRA showed severe stenosis in the M1 portion of MCA bilaterally. We believe that the progressive cerebral angiopathy and recurrent ischemic stroke were caused by an autoimmune mechanism related to SSc.

Souhrn

U systémové sklerózy (SSc) je primární postižení centrální nervové soustavy vzácné. Předkládáme případ 55letého Číňana s SSc, který trpí přetrvávající slabostí levé končetiny doprovázenou deviací bulbů doprava a dysartrií. Zobrazení mozku magnetickou rezonancí (MR) potvrdilo ischemické léze v oblasti pravé arteria cerebri media (MCA). MRA prokázala závažnou stenózu v části M1 pravé MCA. Přes každodenní užívání prednizonu a antitrombocytárních léků orálně došlo u pacienta k další ischemické mozkové příhodě o pouhý rok později doprovázené paralýzou pohledu doprava a afázií. Opakované MR mozku ukázalo akutní ischemické léze vedle levé postranní komory a postischemické léze v pravé hemisféře. MRA ukázala závažnou stenózu v části M1 pravé MCA, oboustranně. Jsme přesvědčeni, že tato progresivní cerebrální angiopatie a recidivující ischemická mozková příhoda byly způsobeny autoimunitním mechanismem souvisejícím s SSc.

P. Lu, P. Xia, X. Hu

Department of Neurology, Sir Run Run Shaw Hospital and Institute of Clinical Medicine of Zhejiang University, Hangzhou, China



Xinyue Hu, M.D.

Department of Neurology
Sir Run Run Shaw Hospital
School of Medicine, Zhejiang University
3# Qingchun Road
Hangzhou, Zhejiang 310016
China
e-mail:
xiaping01062@hotmail.com

Accepted for review: 16. 2. 2009

Accepted for publication: 21. 8. 2009

Key words

systemic sclerosis – ischemic stroke – central nervous system

Klíčová slova

systémová skleróza – ischemická mozková příhoda – centrální nervová soustava

Introduction

Systemic sclerosis (SSc) is an autoimmune disorder that may affect many organs of the body. The skin, lungs, kidneys, gastrointestinal tract and the myocardium are the most likely to be involved. The pathogenesis is still not well understood. Studies have hypothesized that vascular abnormalities, immune changes, collagen proliferation and heredity may be related factors leading to systemic manifestations [1]. The central nervous system is rarely involved in SSc unless there are abnormalities in renal or lung function, or hypertension. Primary neurological dysfunction is still much less common in SSc than in other connective tissue diseases. To date, only a few cases have been reported and in Asia it has only been reported in Japan. The exact incidence and prevalence of nervous system dysfunction in SSc is unknown. In one large series, 6 out of 727 patients with SSc had clinical involvement of the nervous system [2]. Neurological manifestations of SSc reported came mostly in the form of stroke, TIA, seizure, cognitive impairment, spinal cord disorder and peripheral nerve disease. We describe a 55-year-old man with SSc who suffered from recurrent ischemic stroke in the absence of other vascular risk factors (apart from hyperhomocysteinemia) and complications secondary to SSc such as malignant hypertension, uraemia or marked pulmonary disease.

Case report

In 2003, a 51-year-old, right-handed man developed numbness of both hands and

Raynaud's phenomenon. Over time, skin thickening, oedema and pigmentation were noted, including both hands, arms, the trunk and face. A diagnosis of SSc was made based on the above symptoms when he was 52. Skin biopsy in the back and dorsum of the right hand showed features of SSc with pigmentation, oedema of the epidermis, collagen hyperplasia and mild inflammatory cell infiltration. He was treated with 15 mg oral prednisone daily. In 2005, he suffered from mild dysphagia. In 2006, he suffered from mild weakness of the left upper limb, accompanied by eyes gazing to the right and dysarthria. The symptoms persisted. Five days later the symptoms were steadily progressing so he was admitted to a teaching hospital not far from ours. His magnetic resonance imaging (MRI) and diffusion weighted imaging (DWI) showed high signal intensity in right middle cerebral artery (MCA) territory. Intracranial magnetic resonance angiography (MRA) reported a severe stenosis in the M1 portion of the right MCA (Fig 1). He then received ozagrel for antiplatelet therapy. The weakness in the left limb was partially relieved. Home therapy comprised 100 mg aspirin and 15 mg oral prednisone daily.

In 2007, he was admitted to our hospital, presenting with a 3-day history of gaze paralysis to the right and aphasia. There was no history of chronic cough, dyspnoea, hypertension, or diabetes. He had smoked for thirty years, about 15 cigarettes a day, but had given up for nearly two years following his first stroke.

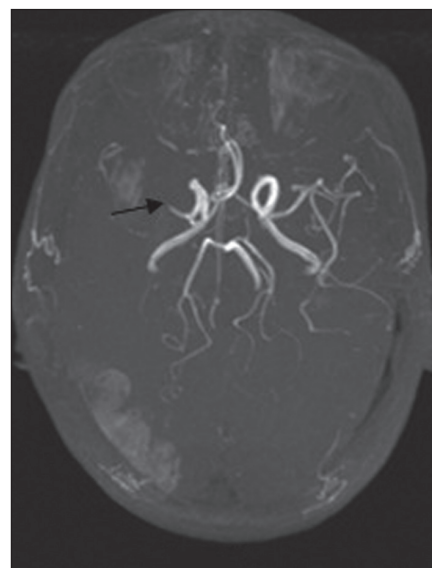


Fig 1. MRA in 2006: a severe stenosis in the M1 portion tract of right MCA was confirmed.

On admission, temperature was 38.6°C; blood pressure was 140/80 mmHg; pulse and respiration were normal. There was a marked tightening and pigmentation of the skin with sclerosis of all the fingers, the palm and the back. The patient was alert. He suffered from Broca aphasia and partial Wernicke aphasia, and could not respond appropriately to our verbal stimuli. We found that the pupils were at 3 mm and reacted to light but the eyes always gazed left. There was a mild left paresis and contracture of the left upper limb, but this was a residue of the previous stroke. Deep tendon reflexes were symmetrically

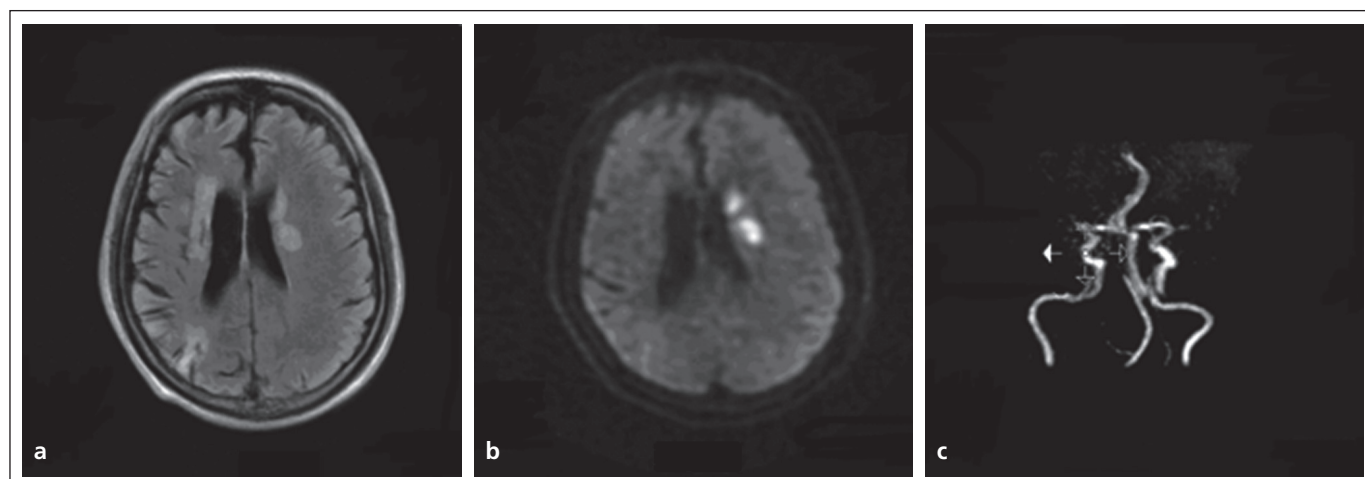


Fig 2. MRI and MRA in 2007: a) FLAIR; b) DWI; c) MRA.

Acute ischemic lesions beside left lateral ventricle were confirmed. Ischemic lesions in the right MCA territory and interterritorial infarction between the MCA and the PCA nutritional areas on the right were postischemic lesions. MRA showed stenosis of bilateral MCA.

normal. The Babinski sign on the left was doubtful and no other pathological reflexes were observed. Cerebellar and sensory functions could not be tested effectively because of aphasia. MRI of the brain on the third day showed acute ischemic lesions next to the left lateral ventricle in the FLAIR images and DWI examination. It also showed postischemic lesions in the right hemisphere in FLAIR images (Fig 2a, b). Intracranial MRA showed severe stenosis in the M1 portion of MCA bilaterally and the distal branches could not be seen clearly (Fig 2c). He immediately received 200 mg aspirin. A laboratory examination was performed later. White blood cell (WBC) was 8,800/ul with an increase in neutrophils. Erythrocyte sedimentation rate was 11 mm/h. ANA, Scl-70, RNP, anti-centromere antibody (ACA), RF, p-ANCA and c-ANCA were all negative. RPR and TPPA were normal. Mean 24-h urinary protein excretion was 153 mg and creatinine clearance rate (CCR) was normal. Serum chemistry revealed only hyperhomocysteinemia, at a level of 28.7 $\mu\text{mol/l}$. Chest X-ray showed an accentuated texture and did not provide evidence of pulmonary fibrosis. Epiaortic and carotid duplex ultrasound was normal and transthoracic echocardiography reported mild reflux of the mitral, the tricuspid valve and the aortic valve, along with a mild pericardial effusion. Considering the inefficacy of aspirin, the maintenance therapy was changed to 75 mg oral clopidogrel daily, while the 15 mg oral prednisone every day continued for the SSc. The patient could be able to say some simple words before discharge.

In February 2008, he reported progressive dizziness, and brain CT scan revealed chronic spontaneous subdural haematoma in the right hemisphere. He recovered after burr-hole craniostomy. From then on, antiplatelet therapy was stopped, but not the corticosteroids. As far as we know he remains in a similar condition as before.

Discussion

SSc has a worldwide distribution and is more frequent in women than men. Systemic sclerosis is characterized by three distinct pathological processes: fibrosis, cellular/humoral autoimmunity and specific vascular changes. Although a mild vasculitis may sometimes be present, the

vascular pathology of the scleroderma is not necessarily inflammatory and is best characterized as a vasculopathy [3]. It includes a spectrum of changes that predominantly involve the microcirculation and arterioles. The pathological changes in the blood vessels adversely influence the physiology of many organs, with a reduction in the size of microvascular beds that leads to a decreased blood flow and ultimately to chronic ischemia [4]. Macrovascular involvement was once considered rare, but an increased prevalence of macrovascular disease has also been reported [5,6]. The nervous system, the brain in particular, is rarely involved in SSc. When this does occur, it is generally a consequence of malignant hypertension and uremia. To our knowledge, only scattered case reports with primary neurological involvement have been described in the radiological literature. Some of our angiographic findings were inconsistent with those of typical cerebral vasculitis. The latter is characterized by a more diffuse elongation, tortuosity and irregularity of multiple intracranial vessels. Thus we believe our patient's angiopathy was not a consequence of a primary central nervous arteritis.

We present a rare case of a male patient suffering from SSc and complicated cerebral infarction. The patient was diagnosed with SSc, in terms of the 1980 American College of Rheumatology (ACR) preliminary criteria for the classification of SSc. His ischemic cerebral infarction could be documented by its clinical manifestation and MRI. Our patient had no history of other obvious vascular risks apart from smoking and hyperhomocysteinemia. Although he had smoked for a long time; he had given up after the first stroke. Hyperhomocysteinemia is an independent vascular risk; it leads to atherosclerosis of large arteries, such as the carotid artery. Since the epiaortic, carotid duplex ultrasound and the transthoracic echocardiography documented no abnormality, we inferred that hyperhomocysteinemia was not the main risk factor. Intracranial MRA in our hospital documented severe stenosis of MCA bilaterally, which showed his neurological deficit had deteriorated compared to MRA in 2006. Further, he experienced a recurrent stroke in 2007. On this basis, we considered the progressive MCA stenosis was caused by an SSc au-

toimmune angiopathy. Our reasoning ran: he had no other traditional risk factors, as described above; there was no obvious family history of stroke. There was no evidence of atherosclerosis. Using the TTE, we were unable to disclose embolic sources. Interestingly, we noticed that our patient's clinical manifestation was not as severe as in patients with a similar ischemic lesion. We attributed it to relatively good microvascular compensation, because the angiopathy of SSc had progressed slowly.

SSc is still considered incurable, although clinical outcomes have improved considerably, presumably due to better management of the complications. No therapy to date has been able to reverse or slow down the progression of tissue fibrosis or substantially modify the natural progression of the disease [7]. Nevertheless, studies have suggested that treatment of pulmonary fibrosis in SSc with low-dose prednisolone and intravenous cyclophosphamide stabilize lung function in a subset of patients with the disease [8,9]. Takehara K [10] reported the usefulness of low-dose oral corticosteroid treatment for early diffuse cutaneous SSc in Japanese patients. Until now, only scattered cases have shown good response to high-dose corticosteroid treatment in patients with neurological involvement within the acute stage, but there are no large sample trials. Our patient suffered from recurrent ischemic cerebral infarction and repeated intracranial MRA showed MCA stenosis deteriorating despite daily oral prednisone and antiplatelet drug therapy. Currently, targeted therapy at the cellular and molecular mechanisms underlying the fibrotic process are being highlighted in the treatment of SSc. Clinical success with medications targeted on logical profibrotic mediators, such as connective tissue growth factor and transforming growth factor- β , has been reported, but studies are ongoing [11].

Furthermore, the data have shown that SSc is much more severe and carries worse prognosis than localized scleroderma (LS), in which the cerebral vasculature is only partially involved. In conclusion, a better understanding of the pathogenesis of SSc would facilitate tailoring of the therapy and more precise evaluation of prognosis.

Literature

1. MaoSong Zhou YY. The progress of study on pathogenesis and mechanism of scleroderma. *Medical Recapitulate* 2008; 14: 88–89.
2. Tuffanelli DL, Winkelmann RK. Systemic scleroderma. A clinical study of 727 cases. *Arch Dermatol* 1961; 84: 359–371.
3. Fleming JN, Schwartz SM. The pathology of scleroderma vascular disease. *Rheum Dis Clin North Am* 2008; 34(1): 41–55.
4. Kahaleh B. Vascular disease in scleroderma: mechanisms of vascular injury. *Rheum Dis Clin North Am* 2008; 34(1): 57–71.
5. Hettema ME, Bootsma H, Kallenberg CG. Macrovascular disease and atherosclerosis in SSc. *Rheumatology (Oxford)* 2008; 47(5): 578–583.
6. Youssef P, Englert H, Bertouch J. Large vessel occlusive disease associated with CREST syndrome and scleroderma. *Ann Rheum Dis* 1993; 52(6): 464–466.
7. Varga J, Abraham D. Systemic sclerosis: a prototypic multisystem fibrotic disorder. *J Clin Invest* 2007; 117(3): 557–567.
8. Mouthon L, Berezné A, Brauner M, Kambouchner M, Guillevin L, Valeyre D. Interstitial lung disease in systemic sclerosis. *Presse Med* 2006; 35(12 Pt 2): 1943–1951.
9. Hoyles RK, Ellis RW, Wellsbury J, Lees B, Newlands P, Goh NS et al. A multicenter, prospective, randomized, double-blind, placebo-controlled trial of corticosteroids and intravenous cyclophosphamide followed by oral azathioprine for the treatment of pulmonary fibrosis in scleroderma. *Arthritis Rheum* 2006; 54(12): 3962–3970.
10. Takehara K. Treatment of early diffuse cutaneous systemic sclerosis patients in Japan by low-dose corticosteroids for skin involvement. *Clin Exp Rheumatol* 2004; 33 (Suppl 3): S87–S89.
11. Denton CP. Therapeutic targets in systemic sclerosis. *Arthritis Res Ther* 2007; 9 (Suppl 2): S6.

www.urologickelisty.cz