proLékaře.cz | 26.11.2026

Steroid-Responsive Hyperintense Lesions in a Patient with Creutzfeldt-Jakob Disease

Hyperintenzivní léze reagující na steroidy u pacienta s Creutzfeldt-Jakobovou nemocí

Abstract
Typical hyperintense changes in the striata and cerebral cortices on T2-weighted (T2W), fluid-attenuated inversion recovery (FLAIR), and diffusion-weighted imaging (DWI) have been described in patients with Creutzfeldt-Jakob disease (CJD). We report the case of a 71-year-old woman with a definite autopsy-proven diagnosis of sporadic CJD Heidenhain variant with T2W and FLAIR hyperintense lesions in parietal and occipital cortex bilaterally on MRI, regressing after steroid administration despite progression of the disease.

Souhrn
U pacientů s Creutzfeldt-Jakobovou nemocí (CJD) byly popsány typické hyperintenzní změny ve striatu a určitých částech mozkové kůry v T2 vážených (T2W), inversion recovery s potlačením signálu likvoru (FLAIR) a difuzně vážených (DWI) zobrazeních. Popisujeme kazuistiku 71leté ženy s definitivní histopatologicky potvrzenou diagnózou Heidenhainovy varianty sporadické CJD, u níž byly přítomny hyperintenzity v kůře okcipitálního a parietálního laloku v T2W a FLAIR sekvencích, které regredovaly po terapii kortikosteroidy i přes další progresi onemocnění.

K. Sheardová[1], R. Matěj[2], I. Rektorová[1]

[1] 1. neurologická klinika LF MU a FN u sv. Anny v Brně
[2] Oddělení patologie a národní referenční laboratoř TSE-CJN, Fakultní Thomayerova nemocnice s poliklinikou, Praha

✉
MUDr. Kateřina Sheardová
1. neurologická klinika LF MU
a FN u sv. Anny v Brně
Pekařská 53
656 91 Brno
e-mail: ksheard@sendme.cz

Přijato k recenzi: 18. 8. 2009
Přijato do tisku: 2. 11. 2009

Klíčová slova
Creutzfeldt-Jakob disease – magnetic resonance imaging – corticosteroids

Key words
Creutzfeldt-Jakobova nemoc – magnetická rezonance – kortikosteroidy

Acknowledgement
This study was supported by Czech Ministry of Education Research Project ref. MSM 0021622404 and IGA MZ NS10335-3.
We would like to thank Drs. Pažourková and Krupa for providing MRI figures.

proLékaře.cz | 26.11.2026

Introduction

Creutzfeldt-Jakob disease (CJD) is a transmissible, progressive, fatal spongiform encephalopathy. The cardinal manifestations of this disease are rapidly progressive dementia, generalized myoclonus, and periodic sharp wave complexes on EEG. However, cases that do not consistently exhibit such typical manifestations have been recognized. Occasionally, patients may also present with ataxia or visual disturbances, behavioural and psychiatric disabilities or with a stroke-like illness. The Heidenhain variant of CJD was first described by Heidenhain in 1929. Typical manifestations of this variant comprise worsening of vision, including blurred vision, cortical blindness or visual hallucinations and more rapid progression of the course of the disease. Clinical symptoms of the Heidenhain variant are present in about 20% of neuropathologically confirmed sporadic CJD cases [5]. Currently, there is no available causal therapy for this fatal disease.

Hyperintensities on both FLAIR imaging and DWI, confined to the grey matter in the cortex, striatum, medial and/or posterior thalamus or a combination of these areas, have been described as the most typical and specific patterns of CJD [1,2]. Based on a multi-centre international study, Zerr et al propose an amendment to the clinical diagnostic criteria of CJD to include MRI results as an additional parameter, which would increase sensitivity to 98% from the 92% sensitivity of current WHO criteria. The detection of either hyperintensity in the basal ganglia (both caudate nucleus and putamen) or in at least two cortical regions appears to be the most specific [3]. Meissner et al described a characteristic MRI lesion pattern on FLAIR and DWI scans for each molecular subtype of CJD, which presents with various early symptoms, disease duration and neuropathology [4]. However, a definite diagnosis of CJD is possible only by morphological investigation, mostly after autopsy. In the Czech Republic, all suspicious cases of transmissible spongiform encephalopathies are subject to notification and should undergo neurohistopathological examination in a specialized reference laboratory. Between 2002 and 2006, 50 definite cases of sporadic CJD were diagnosed post mortem in the Czech Republic [5].

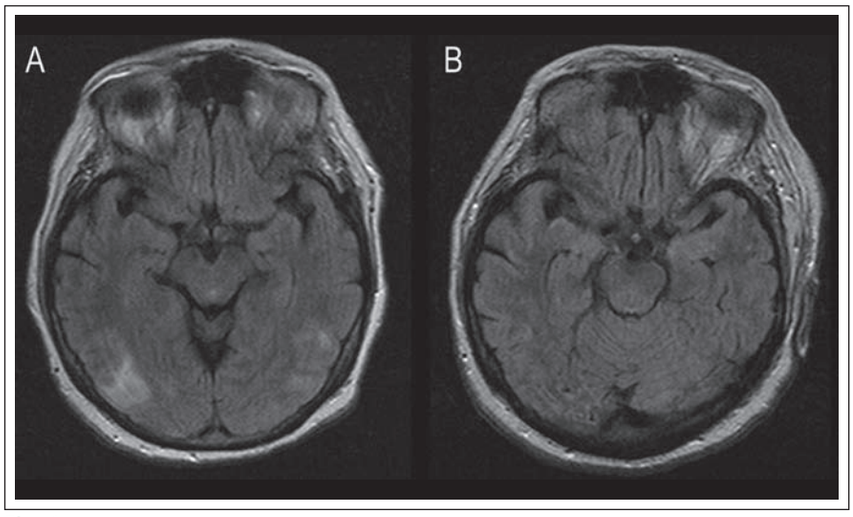

Fig. 1.

A) MRI performed on admission day (FLAIR) showed cortical hyperintensities in the parietal and occipital lobes bilaterally.

B) MRI performed one month later (FLAIR) revealed a significant regression of the MRI hyperintensities.

Case report

We report the case of a 71-year-old woman with a definite diagnosis of sporadic CJD with T2W and FLAIR hyperintense cortical lesions on MRI, regressing after steroid administration despite the clinical progression of the disease. Her initial symptoms were blurred vision and weakening of the left limbs. Three weeks after symptom onset, the patient was admitted to our neurology department. On examination, she was somnolent, bradypsychic but well oriented, with pyramidal syndrome accentuated on the left side, and with flectional posture of the upper limbs and no spontaneous movements. She also presented with cortical blindness and intermittent visual hallucinations. There were no signs of extrapyramidal or cerebellar impairment.

MRI revealed parieto-occipital cortical hyperintensities in T2W and FLAIR scans (Fig. 1A). No signal hyperintensity was observed in the basal ganglia or elsewhere. The lesions largely resembled a vasculitis-like multifocal ischaemia. All further investigations of lesion aetiology were negative, including MR angiography, heart ultrasonography, CT angiography of the aortal arc and haematological screening. Routine cerebrospinal fluid (CSF) analysis was normal (protein 14-3-3 was not examined at that time). Extensive immunology screening was carried out with negative results (except for anticardiolipin antibodies IgM, which were three times higher than normal).

Because of the unclear origin of the vasculitis-like lesions, we administred high-dose steroid therapy – a total 3.5 g of methylprednisolone intravenously over four days, together with anti-aggregation and anticoagulation therapy. An MRI performed four days later showed a regression of the hyperintense lesions while the patient deteriorated clinically with paroxysms of tonic-clonic seizures. EEG showed non-specific general slowing of basal activity. Two weeks later, the condition was complicated by retroperitoneal bleeding requiring temporary intensive unit care. At that time, the neurological status progressed into akinetic mutism, and the patient developed myoclonus on the upper limbs and opsoclonus. An EEG revealed typical periodic sharp wave complexes. A checking MRI showed further significant regression of the cortical hyperintensities (Fig. 1B). A month after admission, the patient required artificial ventilation for two weeks in response to respiratory complications arising out of sepsis and pneumonia. A positive 14-3-3-protein result was obtained from a second spinal tap. A clinical diagnosis of probable Heidenhain variant of CJD was made. The patient died after six months of the disease progression, succumb-

proLékaře.cz | 26.11.2026

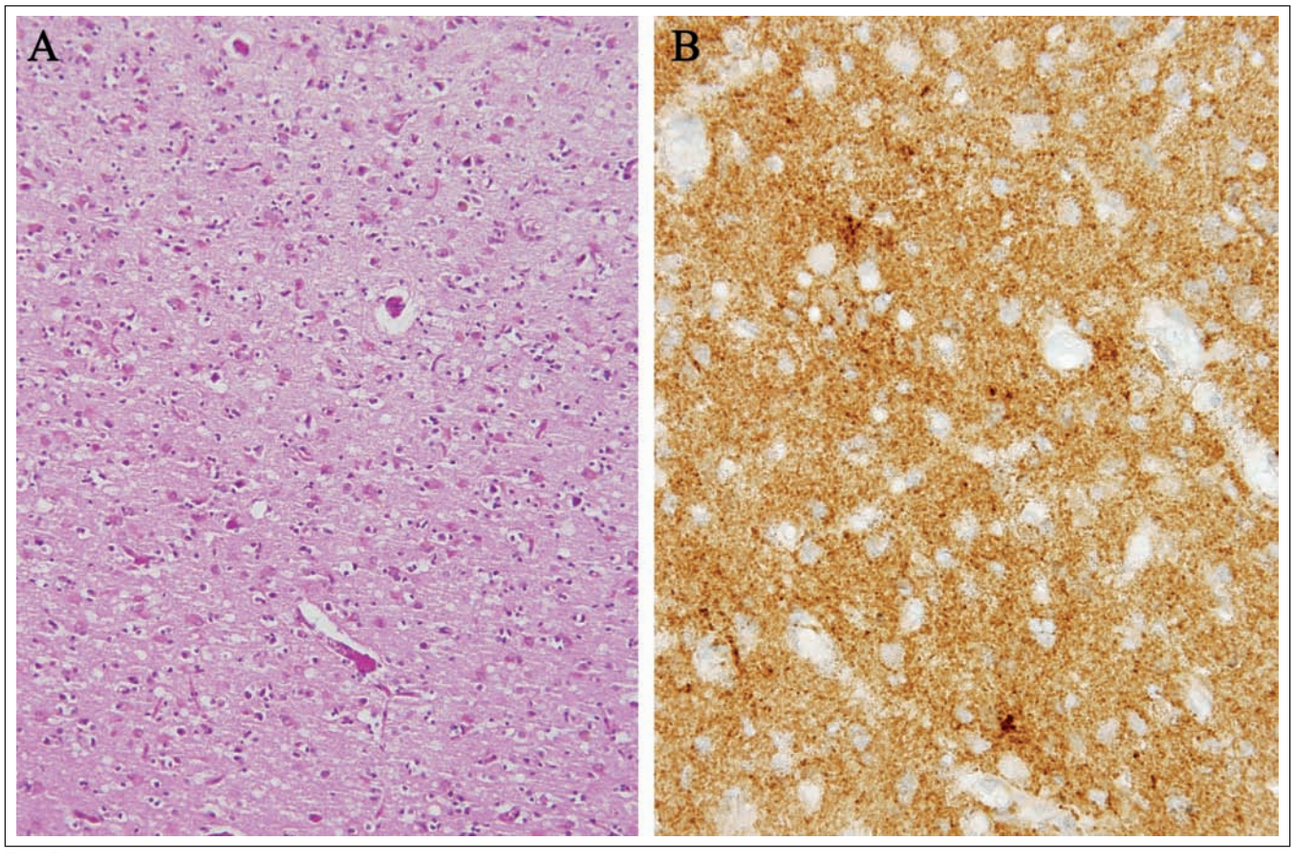

Fig. 2.

A) Prominent spongiform changes, neuronal loss, and astrocytosis in the occipital cortex. No significant hallmarks of any type of vasculitis are present. Standard H&E staining, orig. magnification 200×.

B) Diffuse synaptic and focally perivacuolar (patchy) positivity of PrP^{res} in the occipital cortex. Immunohistochemical reaction with mouse monoclonal anti-PrP antibody, clone 12F10 (orig. magnification 400×).

ing to extracerebral complications of the disease.

On neuropathological examination, typical spongiform changes, neuronal loss, astrocytosis, and diffuse cortical atrophy slightly accentuated in the frontal and temporal lobes were observed (Fig. 2A). The spongiform changes were focally clustered and more prominent in the temporal and occipital cortical areas. A more precise semiquantitative evaluation was complicated by very prominent posthypoxemic changes associated with artificial ventilation. Immunohistochemical examination by two different monoclonal anti-PrP antibodies (clones 3F4 and 12F10) confirmed the histopathological pattern and synaptic and patchy/perivacuolar positivity were seen in all the investigated areas (Fig. 2B). No significant indications of any type of vasculitis were observed.

Discussion

In the Heidenhain variant of CJD, changes in signal intensity in the basal ganglia are detected in only a limited number of cases, while hyperintensities and atrophy in the occipital cortex are more common, although the changes are not necessarily sensitive or specific [6]. Murata et al suggested that cortical signal changes on DWI can evolve over time without treatment [7]. DWI was not performed in our patient. Only a single case in the literature reported a regression of T2W MRI changes in the striatum in the course of the disease [8]. In our case, we observed a rapid regression of T2W MRI cortical hyperintensities following the steroid therapy, although CSF and neuropathological examination could detect no concomitant pathological process. There could be several explanations for this finding. A coincidence of CJD with another pathological process seems the most probable. Because of the effect of corticoid therapy, we were considering an inflammatory aetiology for these lesions. However, there were no signs of inflammation in the spinal tap. Vasculitic changes would have been detectable on autopsy. Another explanation could be a local oedema that regressed after corticosteroid administration. Indeed, despite the temporal association with treatment, these changes in the MRI image could have occurred spontaneously.

It is worth noting that there was no relationship between the rapid clinical progression of the disease and the MRI changes. On autopsy, marked spongiform changes were observed in the corresponding areas of temporal and occipital cortices in particular.

In conclusion, we demonstrated that an improvement of MRI picture after ste-

proLékaře.cz | 26.11.2026

roid therapy does not exclude a diagnosis of CJD. From a clinical point of view, caution should be exercised when dealing with such a patient in cases of diagnostic uncertainty.

References

1. Shiga Y, Miyazawa K, Sato S, Fukushima R, Shibuya S, Sato Y et al. Diffusion-weighted MRI abnormalities as an early diagnostic marker for Creutzfeldt-Jakob disease. Neurology 2004; 63(3): 443–449.

2. Young GS, Geschwind MD, Fischbein NJ, Martindale JL, Henry RG, Liu S et al. Diffusion-weighted and fluid-attenuated inversion recovery imaging in Creutzfeldt-Jakob disease: high sensitivity and specificity for diagnosis. AJNR Am J Neuroradiology 2005; 26(6): 1551–1562.

3. Zerr I, Kallenberg K, Summers DM, Romero C, Taratuto A, Heinemann U et al. Updated clinical diagnostic criteria for sporadic Creutzfeldt-Jakob disease. Brain 2009; 132(10): 2659–2668.

4. Meissner B, Kallenberg K, Sanchez-Juan P, Collie D, Summers DM, Almonti S et al. MRI lession profiles in sporadic Creutzfeldt-Jacob disease. Neurology 2009; 72(23): 1994–2001.

5. Matěj R, Rusina R, Koukolík F. 5 let činnosti Národní referenční laboratoře lidských prionových onemocnění při Oddělení patologie a molekulární medicíny FTNsP: naše zkušenosti a přehled literatury. Cesk Slov Neurol N 2007; 70/103(6): 637–642.

6. Kropp S, Schulz-Schaeffer WJ, Finkenstaedt M., Riedemann C, Windl O, Steinhoff BJ et al. The Heidenhain variant of Creutzfeldt-Jakob disease. Arch Neurol 1999; 56(1): 55–61.

7. Murata T, Shiga Y, Higano S, Takahashi S, Mugikura S. Conspicuity and evolution of lesions in Creutzfeldt-Jakob disease at diffusion-weighted imaging. AJNR Am J Neuroradiol 2002; 23(7): 1164–1172.

8. Staffen W, Trinka E, Iglseder B, Pilz P, Homann N, Ladurner G. Clinical and diagnostic findings in a patient with Creutzfeldt-Jakob disease (type Heidenhain). J Neuroimaging 1997; 7(1): 50–54.

www.geriatrickarevue.cz