

Recovery from Decreased Cerebral Blood Flow in Wernicke's Encephalopathy Following Abstinence from Alcohol – a Case Report

Úprava sníženého mozkového krevního průtoku u Wernickeovy encefalopatie po alkoholové abstinenci – kazuistika

Abstract

There have been few reports of recovery from reduced cerebral blood flow (CBF) in patients with Wernicke's encephalopathy. We report a 70-year-old patient with a 2-day history of increased irritability and minimal vocalisation. Neurological examination revealed no abnormal findings. He was diagnosed as having Wernicke's encephalopathy, because both the blood thiamine concentration and erythrocyte transketolase activity were low. SPECT revealed CBF reduction in many regions of the brain. After thiamine treatment, he reported that he had abstained from alcohol. Two weeks later, all symptoms had resolved completely. SPECT was repeated one month after onset and the CBF reductions observed in the first examination had recovered to almost normal levels. These results suggest that thiamine treatment and abstinence from alcohol can result in recovery from decreased CBF in patients with Wernicke's encephalopathy, as long as the neurological symptoms are not severe.

Souhrn

Bylo zaznamenáno několik zpráv o pacientech s Wernickeovou encefalopatií, u kterých došlo k úpravě sníženého mozkového průtoku (CBF). Uvádíme případ 70letého pacienta s anamnézou dvou dnů zvýšené podrážděnosti a nemluvnosti. Při neurologickém vyšetření nebyly zjištěny žádné abnormální nálezy. Byla u něj diagnostikována Wernickeova encefalopatie, protože koncentrace thiaminu v krvi i transketoláza v erythrocytech byly nízké. SPECT odhalila snížení CBF v mnoha oblastech mozku. Po thiaminové léčbě pacient oznámil abstinenci alkoholu. O dva týdny později již nebyly žádné příznaky patrné. Jeden měsíc po nástupu obtíží byla SPECT zopakována; CBF, který byl při prvním vyšetření nižší, se vrátil na téměř normální úroveň. Tyto výsledky naznačují, že léčba thiaminem a abstinencí alkoholu mohou vést k vyřešení sníženého CBF u pacientů s Wernickeovou encefalopatií, pokud nejsou neurologické příznaky vážné.

Y. Suzuki, K. Ogawa,
M. Oishi, T. Mizutani

Division of Neurology, Department
of Medicine, Nihon University School
of Medicine, Tokyo, Japan



Yutaka Suzuki
Division of Neurology,
Department of Medicine
Nihon University School
of Medicine
30-1 Oyaguchikami-machi,
Itabashi-ku
173-8610 Tokyo
Japan
e-mail:
yutakayu@med.nihon-u.ac.jp

Accepted for review: 22. 9. 2009
Accepted for print: 21. 1. 2010

Key words

cerebral blood flow – single photon
emission computed tomography – Wer-
nicke's encephalopathy – abstinence
from alcohol

Klíčová slova

průtok krve mozem – jednofotonová
emisní počítačová tomografie – Wer-
nickeova encefalopatie – abstinence
alkoholu

Introduction

Humans consume alcohol for various reasons. Consumption of alcohol in moderate amounts (men ~30g/day; women ~20g/day) can help alleviate psychological stress and promote smooth personal relationships, and these effects may be pronounced. However, chronic and excessive ethanol consumption (men > 50g/day; women >35g/day) can result in various neurological diseases, such as cerebellar degeneration, cerebral atrophy, Wernicke's encephalopathy, Marchiafava-Bignami disease, spontaneous intracranial haemorrhage, epilepsy, and peripheral neuropathy. Chronic excessive alcohol consumption has also been shown to decrease cerebral blood flow (CBF) in various regions of the brain [1,2]. However, there have been a few reports [3,4] of recovery from such reduced CBF in patients with Wernicke's encephalopathy. We report herein a patient with a history of excessive alcohol consumption in whom a recovery from reduced CBF was observed following thiamine therapy and abstinence from alcohol.

Case report

The patient was a 70-year-old man, by occupation the manager of a small company. He had consumed more than 2,500ml of beer (5% alcohol by volume) every day for more than 20 years. He presented at our hospital with a 2-day history of increased irritability and minimal vocalisation, as reported by his family. He had

ingested little nourishment other than alcohol during the previous three days due to excessive work-related stress. While the patient himself did not feel that anything was wrong, his family reported that he was more irritable and spoke less than usual. General physical examination revealed no abnormalities. His temperature at the time of the first examination was 35.6 °C, his pulse was 72 beats/min, and his blood pressure was 124/78 mmHg. On neurological examination, there were no abnormal findings; the disturbed consciousness, ataxia, and diplopia that usually accompany Wernicke's encephalopathy were absent. Laboratory studies revealed that his aspartate aminotransferase (AST) was 40 (normal range, 8–38) U/l, alanine aminotransferase (ALT) 45 (normal range, 4–44) U/l, blood thiamine concentration 16 (normal range, 20–50) ng/ml, and erythrocyte transketolase activity 0.61 (normal range, 0.75–1.30) IU/gHB. Magnetic resonance imaging (MRI) of the head showed no abnormalities except for slight bilateral frontal lobe atrophy. Three days after his hospital visit, single photon emission computed tomography (SPECT) was performed using the ^{99m}Tc -ECD Patlak Plot method [5]. It revealed reduced CBF in most regions of the brain (Fig. 1A). EEG revealed background activity of 9 Hz α waves, with a small number of 7 Hz θ waves (Fig. 2A). These findings appeared to indicate early-stage Wernicke's encephalopathy. The patient was therefore treated with infusions of

100mg of thiamine daily for three days, and was instructed to abstain from alcohol and eat a well-balanced diet with vitamin supplements. Within a few days, he became calmer and began to speak more. Two weeks later, all symptoms had resolved completely. SPECT was repeated one month after the first visit to our hospital and revealed that the CBF reductions noted in most brain regions on the first examination had recovered to almost normal levels (Fig. 1B). EEG taken one month after onset revealed background activity of 10 Hz α waves without slow waves (Fig. 2B).

Discussion

Cerebral glucose metabolism [6,7] and CBF [1,2] are known to be decreased in chronic alcoholic patients. Decreased regional CBF is thought to begin before the onset of the neurological and psychiatric symptoms in chronic alcoholic patients [1]. However, there are a few reports [3,4] of recovery from such reduced CBF in patients with Wernicke's encephalopathy. Meyer et al measured CBF by ^{133}Xe inhalation in nine Wernicke-Korsakoff syndrome cases (all men; mean daily alcohol consumption, 202 ± 126 g; mean duration of alcohol consumption, 25.1 ± 10.9 years) before and three months after treatment and reported resultant CBF increases of ~25% with improvement of cognitive and neurological impairments [3]. Benson et al measured CBF by SPECT before and four months

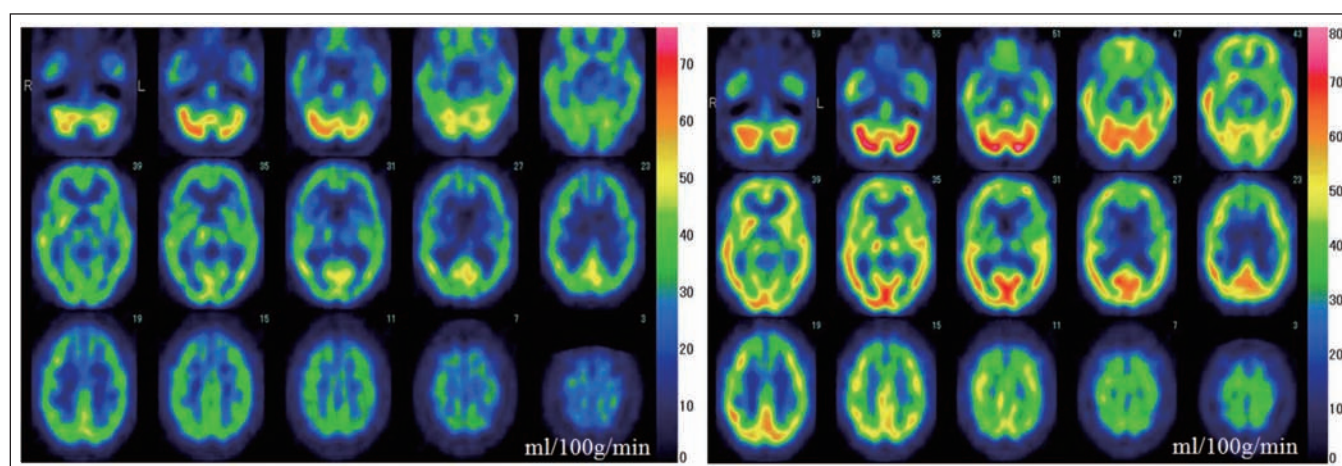


Fig. 1. SPECT images. Single photon emission computed tomography (SPECT) by the ^{99m}Tc -ECD Patlak Plot method.

A (left): SPECT images from the first examination (three days after onset). Regional cerebral blood flow is decreased in most brain regions.

B (right): SPECT images from the second examination (one month after onset). Regional cerebral blood flow is increased in most brain regions as compared to those in A.

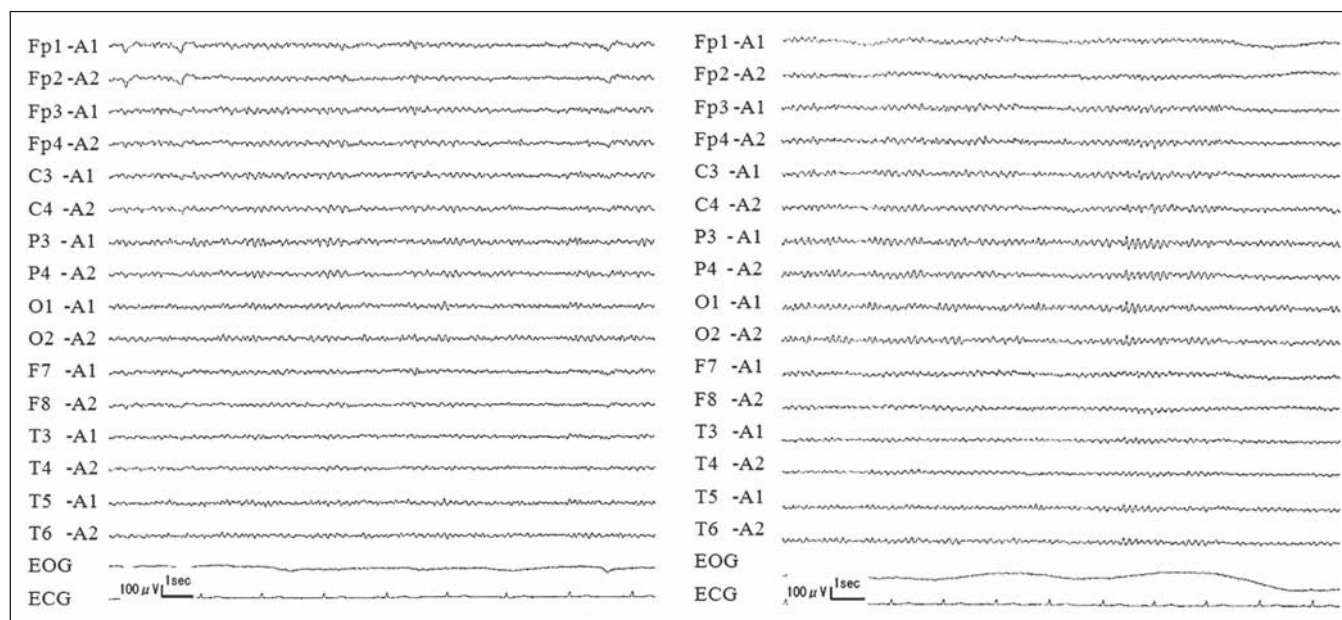


Fig. 2. Electroencephalography (EEG).

A (left): EEG performed three days after onset shows 9-Hz background activity and some 7-Hz waves.

B (right): EEG performed one month after onset shows 10-Hz background activity and no slow waves.

after treatment of a 32-year-old woman who presented with severe learning deficits plus impaired performance [4]. Her daily consumption and duration of alcohol consumption were unclear. They reported that repeat SPECT showed a return to normal perfusion in the frontal brain areas, but little improvement in the medial diencephalic region, although her amnesia remained.

In the present case, following abstinence from alcohol, the patient's symptoms disappeared within one week and the CBF reductions returned to almost normal levels in most brain regions within one month. These results suggest that abstinence from alcohol can result in recovery of the decreased CBF in Wernicke's encephalopathy, as long as the neurological symptoms are not severe. It is important to advise such patients to abstain strictly from alcohol and to eat a balanced diet.

Thus, even though the mechanism still remains unknown, abstinence from alcohol can improve cerebral metabolism [6] and vascular smooth muscle contrac-

tion [8]. Some reports have suggested that neurogenesis from neural stem/progenitor cells is a possible mechanism underlying the structural plasticity in chronic alcoholic patients [9]. Nixon et al reported that microgliosis could contribute to volume recovery in non-neurogenic regions during abstinence from alcohol in a model of alcohol abuse disorders [10]. These may be associated with recovery from decreased CBF in Wernicke's encephalopathy.

In conclusion, thiamine treatment and abstinence from alcohol can result in recovery from decreased CBF in patients with Wernicke's encephalopathy, as long as the neurological symptoms are not severe.

References

1. Suzuki Y, Oishi M, Mizutani T, Sato Y. Regional cerebral blood flow measured by the resting and vascular reserve (RVR) method in chronic alcoholics. *Alcohol Clin Exp Res* 2002; 26 (Suppl 8): 955–995.
2. Demir B, Uluğ B, Lay Ergün E, Erbaş B. Regional cerebral blood flow and neuropsychological functioning in early and late onset alcoholism. *Psychiatry Res* 2002; 115(3): 115–125.
3. Meyer JS, Tanahashi N, Ishikawa Y, Hata T, Velez M, Fann WE et al. Cerebral atrophy and hypoperfusion improve during treatment of Wernicke-Korsakoff syndrome. *J Cereb Blood Flow Metab* 1985; 5(3): 376–385.
4. Benson DF, Djenderedjian A, Miller BL, Pachana NA, Chang L, Itti L et al. Neural basis of confabulation. *Neurology* 1996; 46(5): 1239–1243.
5. Matsuda H, Yagishita A, Tsuji S, Hisada K. A quantitative approach to technetium-99m ethyl cysteinate dimer: A comparison with technetium-99m hexamethylpropylene amine oxime. *Eur J Nucl Med* 1995; 22(7): 633–637.
6. Johnson-Greene D, Adams KM, Gilman S, Kopppe RA, Junck L, Kluin KJ et al. Effects of abstinence and relapse upon neuropsychological function and cerebral glucose metabolism in severe chronic alcoholism. *J Clin Exp Neuropsychol* 1997; 19(3): 378–385.
7. Sachs H, Russell JA, Christman DR, Cook B. Alteration of regional cerebral glucose metabolic rate in non-Korsakoff chronic alcoholism. *Arch Neurol* 1987; 44(12): 1242–1251.
8. Altura BM, Altura BT, Gebrewold A. Alcohol-induced spasms of cerebral blood vessels: relation to cerebrovascular accidents and sudden death. *Science* 1983; 220(4594): 331–333.
9. Crews FT, Miller MW, Ma W, Nixon K, Zawada WM, Zakhari S. Neural stem cells and alcohol. *Alcohol Clin Exp Res* 2003; 27(2): 324–335.
10. Nixon K, Kim DH, Potts EN, He J, Crews FT. Distinct cell proliferation events during abstinence after alcohol dependence: microglia proliferation precedes neurogenesis. *Neurobiol Dis* 2008; 31(2): 218–229.