

# Complete Hearing Restoration in Vestibular Schwannoma with Repeated Sudden Hearing Loss

## Kompletní úprava sluchu u vestibulárního schwannomu s opakovanou náhlou ztrátou sluchu

### Abstract

Neither the pathophysiological features nor the treatment strategy for sudden hearing loss in vestibular schwannoma have yet been generally agreed upon. Complete restoration and preservation of hearing in these cases is extremely rare. We report a case presenting with a second episode of sudden hearing loss with tinnitus and no signs of spontaneous recovery. An acute MRI revealed an intracanalicular schwannoma on the left side with a part protruding into the cerebello-pontine angle. Hearing was completely restored following the administration of corticosteroid therapy. Radical microsurgical removal of the vestibular schwannoma with the preservation of normal hearing was performed one month after a second attack, with no complications. Hearing status remains stable and there is no evidence of the tumour on MRI scan three years after the surgery. This observation supports the fact that recurrent episodes of sudden hearing loss in vestibular schwannoma do not exclude the possibility of complete hearing restoration.

### Souhrn

Patofyziologická podstata a strategie léčby náhlé ztráty sluchu u pacientů s vestibulárním schwannomem není ještě zcela objasněna. Kompletní úprava a zachování sluchu jsou v těchto případech extrémně vzácné. Autoři prezentují případ s druhou atakou náhlé ztráty sluchu s tinitem a bez tendence ke spontánní úpravě. Akutní MR odhalilo intrakanikulární vestibulární schwannom vlevo s 6mm extenzí do mostomozečkového úhlu. Sluch se upravil po podání kortikoidů. Měsíc po druhé atace byla provedena radikální resekce vestibulárního schwannomu se zachováním normálního sluchu. Na pravidelných ročních kontrolách je tři roky po výkonu sluch normální a MR bez rezidua nádoru. Tento případ podporuje fakt, že reverzibilní ataky náhlé ztráty sluchu u vestibulárního schwannomu nevylučují možnost kompletní úpravy a zachování sluchu.

### M. Sameš, P. Vachata

Department of Neurosurgery,  
J.E. Purkinje University, Masaryk  
Hospital, Usti nad Labem, Czech  
Republic



**Petr Vachata MD, PhD**  
Department of Neurosurgery,  
J.E. Purkinje University,  
Masaryk Hospital  
Sociální péče 12A  
401 13 Usti nad Labem  
Czech Republic  
e-mail: petr.vachata@mnul.cz

Accepted for review: 3. 9. 2009

Accepted for print: 1. 2. 2010

### Klíčová slova

corticosteroids – sudden hearing loss –  
vestibular schwannoma

### Key words

kortikosteroidy – náhlá ztráta sluchu –  
vestibulární schwannom

## Introduction

Due to advances in microsurgical techniques and the routine performance of radical vestibular schwannoma resection without facial nerve dysfunction, the preservation or even restoration of hearing is of prime concern to us today. Hearing loss is the most common presenting symptom in patients with a vestibular schwannoma regardless of its size. Reduction is typically progressive over a long period. Sudden hearing loss, characterised by a rapid-onset sensorineural hearing loss evolving over a few hours or days, has been reported over a wide range of 1% to 47% of cases [1–4]. The reported incidence has risen as MRI has become increasingly used to detect small intracanalicular tumours. Since the first report of a vestibular schwannoma with sudden hearing loss as the initial symptom published in 1956 by Hallberg, neither the pathophysiological features nor a treatment strategy for these cases has yet been generally agreed upon [5].

We report a case of hearing restoration following repeated sudden hearing loss, using corticosteroid administration and subsequent preservation of normal hearing after radical removal of a small extracanalicular vestibular schwannoma.

## Case report

A 34-year-old man presented with a first attack of sudden left-sided hearing loss with tinnitus in January 2006. The patient did not undergo any further medical examination or treatment because of a subjective feeling of spontaneous hearing improvement on the first day after the episode. Hearing steadily improved and after three weeks was completely restored. Nine months after initial presentation, a second episode of sudden hearing loss with tinnitus occurred. Because the second attack showed no signs of spontaneous recovery, he consulted his doctor. There was no other neurological deficit. An audiogram revealed a profound sensorineural hearing loss at medium and high frequencies in the left ear with a pure tone average of 65 dB and a speech discrimination score of 8% (Fig. 1). Hearing was classified according to the AAO-HNS classification as class D [6]. Brainstem auditory evoked potentials (BAEP) were typical for a retrocochlear lesion with the sparing of wave 1. An acute MRI of the brain revealed a solid intracanalicular vestibular schwannoma on

the left side with an extracanalicular part protruding 6 mm into the cerebello-pontine angle (Fig. 2). The patient was immediately treated with corticosteroids (prednisone 1 mg/kg). After three days the hearing started to improve. An audiogram after two weeks of conservative treatment revealed an excellent improvement to class A according to AAO-HNS with a pure tone average of 15 dB and a speech discrimination score of 92% (Fig. 1) [6]. Brainstem auditory evoked potentials returned to standard physiological values. After evaluating all hearing preservation possibilities, including radiosurgery, the patient expressed a preference for microsurgery. One month after the second episode of sudden hearing loss, surgery via the retrosigmoidal transmeatal approach was performed by the senior author. Methylprednisolon (250 mg) was administered at the beginning of surgery. Facial nerve functions and brainstem auditory evoked potentials were monitored intra-operatively. The amplitude of BAEP decreased by 20% during cerebellar retraction and again during the tumour dissection. The schwannoma protruded 5 mm from the internal auditory canal (Fig. 3). The bone was carefully drilled out using frameless navigation to preserve the labyrinth. After complete resection monitored and directed by endoscope, BAEP improved to pre-operative values. The minimal stimulation threshold of the facial nerve was 0.05 mA during the entire procedure. The postoperative course was uneventful. His-

tological examination revealing evidence of Antoni type A and Antoni type B was consistent with the diagnosis of a schwannoma WHO grade I. An audiogram performed five days after the surgery revealed normal hearing with a pure tone average of 12.5 dB and a speech discrimination score of 98% and was classified as class A according to AAO-HNS (Fig. 1) [6]. The patient was able to use the telephone without any problems. Facial nerve function showed no deterioration after surgery (House-Brackmann grade I). Hearing status remained stable and there is no evidence of the tumour on MRI scan three years after the surgery (Fig. 2).

## Discussion

The exact mechanism underlying sudden hearing dysfunction in vestibular schwannoma is still uncertain and is most probably multifactorial. The mechanical compression theory of a conduction block of the cochlear nerve action potential is supported by the traditional tonotopical organization of the cochlear nerve [7–9]. Compression of the nerve, according to the authors who support the theory, first affects the superficial high- and mid-frequency fibres. This means that the low-frequency fibres should be located in the central core of the cochlear nerve and in the apical turn of the cochlea. On the other hand, Fayad et al [10] have shown in an anatomical study that low-frequency fibres do come into contact with vestibular

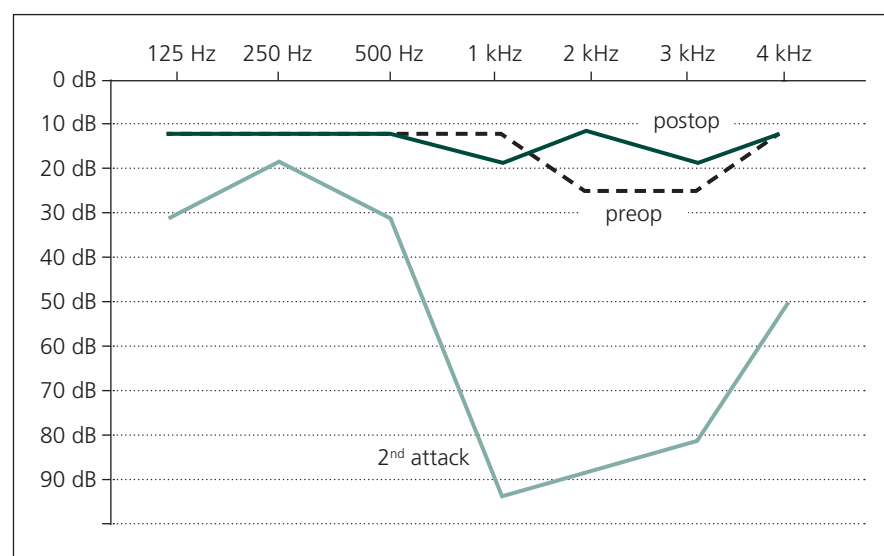
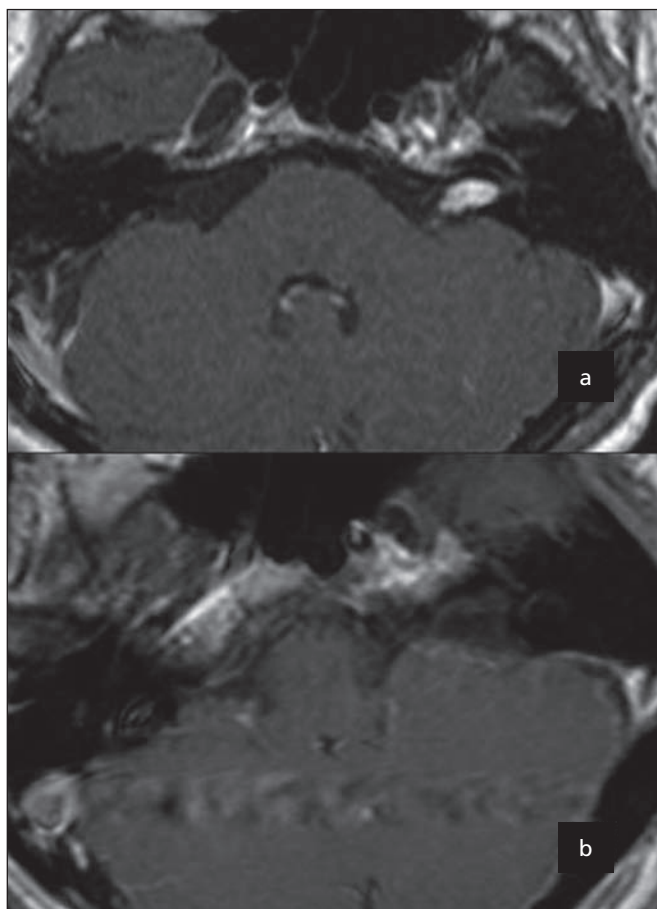
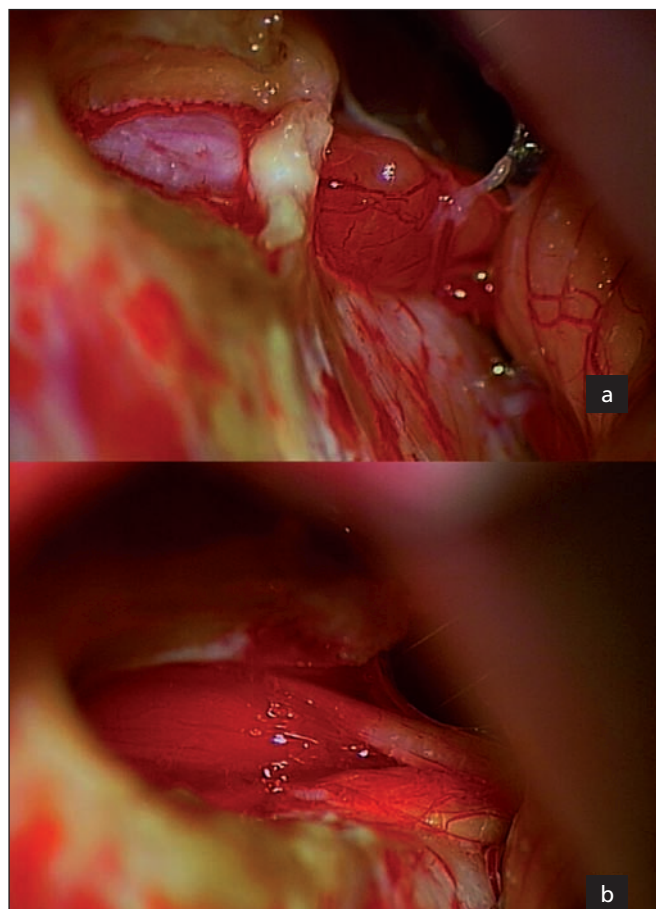


Fig. 1. Pure-tone audiogram shows the hearing status after the second attack of sudden hearing loss, after the corticosteroid treatment and after the radical surgery.



**Fig. 2.** Pre-operative (A) and post-operative (B) MRI T1-weighted images with gadolinium contrast of the vestibular schwannoma.



**Fig. 3.** Per-operative photography before (A) and after the radical surgery (B) of the vestibular schwannoma.

nerve fibres in the distal end of the internal auditory canal. This study concluded that low-frequency fibres appear to be located at the periphery of the cochlear nerve. Accelerated tumour expansion may potentially be caused by haemorrhage, necrosis or tumour oedema. Because of the distal watershed character of blood flow in this part of the cochlea, deterioration of low frequency sensitivity might be the result of a vascular event. Such a vascular theory is supported by sudden onset in a hearing disturbance [11–15]. The compression or spasm of the labyrinthine artery or its branch in the internal auditory canal causes cochlear ischemia [16]. In the setting of elevated pressure in the internal auditory canal, the vascular reserve capacity of the auditory apparatus is exhausted and a change in blood pressure may induce clinical cochlear ischemia [17]. Tumour parasitisation with a “steal” phenomenon is also discussed [18]. Some studies present a higher incidence of sudden hearing loss in small intracanalicular tu-

mours [7,15,19], but others have failed to show this correlation [11,13].

Complete recovery from hearing loss in the setting of a vestibular schwannoma is very rare and is usually limited to cases involving sudden onset and relatively short duration. Complete recovery from, or partial improvement in, sudden hearing deterioration has been described as spontaneous [3,12,13,15,19–21] or attributable to corticosteroid treatment [12,15,22,23]. Most of these tumours were located intracanalicularly, but large tumours with brainstem compression may also be associated with hearing recovery [13]. The exact mechanism is again unclear, as is the onset of deterioration, with reversible intracanalicular pressure or ischemia caused by the tumour being the most suspected culprits. A positive effect of corticosteroids on hearing restoration was also confirmed by Aronzon in a group of seven patients undergoing conservative management of acoustic neuromas [24]. The reinstatement of hearing by conservative treatment

is time-limited, since the cause is not resolved [25]. Every subsequent attack involves the risk of permanent deafness. Complete hearing recovery after recurrent attacks is extremely rare. Yanagihara et al presented a case of complete recovery after two attacks following the administration of steroids [15]. The result of any subsequent treatment was not mentioned. Berg et al recorded a case of complete spontaneous recovery after three isolated episodes of sudden hearing loss and the subsequent preservation of normal hearing after radical removal of a schwannoma [12]. Berenholz et al even presented a case of successful steroid treatment of four sudden attacks [20]. Because of pre-existing deafness in the contralateral ear, the authors performed only a middle fossa decompression of the internal auditory canal to avoid the risk of complete hearing loss. The patient had a fifth episode three months after the decompression.



The rare improvement of hearing after surgical resection or decompression of a schwannoma is not associated only with a history of sudden hearing loss [1,26–34]. The findings of Shelton et al do not support suggestions by Telian et al that sudden preoperative deterioration of hearing may be predictive of postoperative improvement [27,35]. The interval between the onset of sudden auditory deterioration and a successful surgical intervention has ranged from 24 hours [1] to several months [26], perhaps with a tendency towards better results in earlier indications. It is not clear how long we should wait before removing a vestibular schwannoma or which patients are likely to respond to corticosteroids. The presence of detectable oto-acoustic emissions determining the cochlear function may predict, but not exclude, the potential for hearing preservation or recovery [26,36]. The absence of pre-operative BAEP is not a contraindication to hearing preservation surgery [18,37]. Friedman et al showed that patients with a history of a sudden hearing loss have the same chance of hearing preservation after surgery as those with a progressive loss [9]. A history of pre-operative recovery has not proved predictive for hearing preservation. The best hearing function achieved pre-operatively with conservative management could be generally accepted as the most important pre-operative predictive factor for hearing preservation in vestibular schwannoma surgery [36,38,39]. Emergency surgery was advocated by Meiteles as there was only a 10–20 dB improvement in the pure tone response after 24 hours of corticosteroid therapy in a patient with contralateral deafness [1]. This raises the question of a possible subsequent improvement, as we have shown in our case.

## Conclusion

Sudden hearing loss is an acute condition requiring active treatment and a full evaluation, including BAEP and contrast MRI imaging. All patients with vestibular schwannomas should receive corticosteroid treatment at the first signs of sudden hearing deterioration regardless of the exact mechanism and benefit being currently unknown. Recurrent episodes of sudden hearing loss in vestibular schwannoma do not exclude the possibility of complete hearing restoration and the subsequent preservation of normal

hearing after radical surgery. Further studies are necessary to understand the mechanisms underlying sudden hearing loss and to determine which patients will respond best to corticosteroid therapy or how long it is necessary to wait before removal of the lesion tumour is warranted for hearing preservation or even hearing restoration.

## References

- Meiteles LZ, Liu JK, Couldwell WT. Hearing restoration after resection of an intracanalicular vestibular schwannoma: a role for emergency surgery? Case report and review of the literature. *J Neurosurg* 2002; 96(4): 796–800.
- Chaimoff M, Nageris BI, Sulkes J, Spitzer T, Kalmanowitz M. Sudden hearing loss as a presenting symptom of acoustic neuroma. *Am J Otolaryngol* 1999; 20(3): 157–160.
- Chow JM, Garcia J. Acoustic neuroma presenting as sudden hearing loss. *Am J Otolaryngol* 1985; 6(2): 115–119.
- Nedzelski JM, Dufour JJ. Acoustic neurinomas presenting as sudden deafness. *ORL J Otorhinolaryngol Relat Spec* 1975; 37(5): 271–279.
- Hallberg OE. Sudden deafness of obscure origin. *Laryngoscope* 1956; 66(10): 1237–1267.
- Committee on Hearing and Equilibrium guidelines for the evaluation of hearing preservation in acoustic neuroma (vestibular schwannoma). American Academy of Otolaryngology-Head and Neck Surgery Foundation, INC. *Otolaryngol Head Neck Surg* 1995; 113(3): 179–180.
- Ogawa K, Kanzaki J, Ogawa S, Tsuchihashi N, Inoue Y. Acoustic neuromas presenting as sudden hearing loss. *Acta Otolaryngol Suppl* 1991; 487: 138–143.
- Saunders JE, Luxford WM, Devgan KK, Fetterman BL. Sudden hearing loss in acoustic neuroma patients. *Otolaryngol Head Neck Surg* 1995; 113(1): 23–31.
- Friedman RA, Kesser BW, Slattery WH, 3rd, Brackmann DE, Hitselberger WE. Hearing preservation in patients with vestibular schwannomas with sudden sensorineural hearing loss. *Otolaryngol Head Neck Surg* 2001; 125(5): 544–551.
- Fayad JN, Don M, Linthicum FH jr. Distribution of low-frequency nerve fibers in the auditory nerve: Temporal bone findings and clinical implications. *Otol Neurotol* 2006; 27(8): 1074–1077.
- Aslan A, De Donato G, Balyan FR, Falcioni M, Russo A, Taibah A et al. Clinical observations on coexistence of sudden hearing loss and vestibular schwannoma. *Otolaryngol Head Neck Surg* 1997; 117(6): 580–582.
- Berg HM, Cohen NL, Hammerslag PE, Waltzman SB. Acoustic neuroma presenting as sudden hearing loss with recovery. *Otolaryngol Head Neck Surg* 1986; 94(1): 15–22.
- Pensak ML, Glasscock ME 3rd, Josey AF, Jackson CG, Gulya AJ. Sudden hearing loss and cerebellopontine angle tumors. *Laryngoscope* 1985; 95(10): 1188–1193.
- Selesnick SH, Jackler RK. Clinical manifestations and audiologic diagnosis of acoustic neuromas. *Otolaryngol Clin North Am* 1992; 25(3): 521–551.
- Yanagihara N, Asai M. Sudden hearing loss induced by acoustic neuroma: significance of small tumors. *Laryngoscope* 1993; 103(3): 308–311.
- Higgs WA. Sudden deafness as the presenting symptom of acoustic neurinoma. *Arch Otolaryngol* 1973; 98(2): 73–76.
- Lapsiwala SB, Pyle GM, Kaemmerle AW, Sasse FJ, Badie B. Correlation between auditory function and internal auditory canal pressure in patients with vestibular schwannomas. *J Neurosurg* 2002; 96(5): 872–876.
- Stidham KR, Roberson JB jr. Hearing improvement after middle fossa resection of vestibular schwannoma. *Otol Neurotol* 2001; 22(6): 917–921.

- Nageris BI, Popovtzer A. Acoustic neuroma in patients with completely resolved sudden hearing loss. *Ann Otol Rhinol Laryngol* 2003; 112(5): 395–397.
- Berenholz LP, Eriksen C, Hirsh FA. Recovery from repeated sudden hearing loss with corticosteroid use in the presence of an acoustic neuroma. *Ann Otol Rhinol Laryngol* 1992; 101(10): 827–831.
- Popovtzer A, Nageris BI, Bahar G. Resolved sudden hearing loss as a presenting symptom of retrocochlear lesion. *J Basic Clin Physiol Pharmacol* 2001; 12 (2 Suppl): 101–107.
- Suzuki M, Sakai T, Hirakawa K, Oya T, Yajin K, Harada Y et al. Acoustic neuroma presenting with sudden and fluctuating hearing loss – a case report. *Auris Nasus Larynx* 1987; 14(3): 165–170.
- Hultcrantz E. Clinical treatment of vascular inner ear diseases. *Am J Otolaryngol* 1988; 9(6): 317–322.
- Aronzon A, Ruckenstein MJ, Bigelow DC. The efficacy of corticosteroids in restoring hearing in patients undergoing conservative management of acoustic neuromas. *Otol Neurotol* 2003; 24(3): 465–468.
- Mineta H, Nozue M, Ito H, Nozawa O, Nanba T. Acoustic tumor with hearing loss of sudden onset and recovery. *Auris Nasus Larynx* 1986; 13 (Suppl 2): S123–S129.
- Inoue Y, Ogawa K, Kanzaki J. Hearing improvement after tumor removal in a vestibular schwannoma patient with severe hearing loss. *Eur Arch Otorhinolaryngol* 2003; 260(9): 487–489.
- Shelton C, House WF. Hearing improvement after acoustic tumor removal. *Otolaryngol Head Neck Surg* 1990; 103(6): 963–965.
- Yanagihara N, Murakami S, Asai M, Hatakeyama T, Zenke K. Hearing improvement following removal of acoustic neuroma with preoperative sudden deafness. *Ear Nose Throat J* 1994; 73(12): 886, 890–884.
- Cohen NL, Ransohoff J, Jacobs J. Restoration of speech discrimination following suboccipital, transmeatal excision of extracanalicular acoustic neuroma. *Otolaryngol Head Neck Surg* 1985; 93(1): 126–131.
- Fischer G, Costantini JL, Mercier P. Improvement of hearing after microsurgical removal of acoustic neuroma. *Neurosurgery* 1980; 7(2): 154–159.
- Gadre AK, Kwartler JA, Brackmann DE, House WF, Hitselberger WE. Middle fossa decompression of the internal auditory canal in acoustic neuroma surgery: a therapeutic alternative. *Laryngoscope* 1990; 100(9): 948–952.
- Colletti V, Fiorino FG, Carner M, Tonoli G. Mechanisms of auditory impairment during acoustic neuroma surgery. *Otolaryngol Head Neck Surg* 1997; 117(6): 596–605.
- Kawaguchi T, Tanaka R, Kameyama S, Yamazaki H. Full recovery from deafness after removal of a large acoustic neurinoma associated with neurofibromatosis 2: case report. *Surg Neurol* 1994; 42(4): 326–329.
- Weber PC, Gantz BJ. Results and complications from acoustic neuroma excision via middle cranial fossa approach. *Am J Otol* 1996; 17(4): 669–675.
- Telian SA, Kemink JL, Kileny P. Hearing recovery following suboccipital excision of acoustic neuroma. *Arch Otolaryngol Head Neck Surg* 1988; 114(1): 85–87.
- Ferber-Viart C, Laoust L, Boulud B, Duclaux R, Dubreuil C. Acuteness of preoperative factors to predict hearing preservation in acoustic neuroma surgery. *Laryngoscope* 2000; 110(1): 145–150.
- Roberson JB, Jr., Jackson LE, McAuley JR. Acoustic neuroma surgery: absent auditory brainstem response does not contraindicate attempted hearing preservation. *Laryngoscope* 1999; 109(6): 904–910.
- Rohit, Piccirillo E, Jain Y, Augurio A, Sanna M. Preoperative predictive factors for hearing preservation in vestibular schwannoma surgery. *Ann Otol Rhinol Laryngol* 2006; 115(1): 41–46.
- Brackmann DE, Owens RM, Friedman RA, Hitselberger WE, De la Cruz A, House JW et al. Prognostic factors for hearing preservation in vestibular schwannoma surgery. *Am J Otol* 2000; 21(3): 417–424.