proLékaře.cz | 26.11.2026

Spontaneous Intracranial Hypotension Syndrome in a Chinese Patient with Autosomal Dominant Polycystic Kidney Disease – a Case Report

Syndrom spontánní intrakraniální hypotenze u čínské pacientky s autozomálně dominantní polycystickou nemocí ledvin – kazuistika

Abstract

Intracranial hypotension is typically manifested by orthostatic headache. The most frequent underlying factor is cerebrospinal fluid leakage. It has been suggested that dural structural weakness in some connective tissue diseases may be responsible for dural tears and diverticula and consequently leakage. There is no previous report of connective tissue disease with spontaneous intracranial hypotension in Chinese people, to our knowledge. The authors describe a case of autosomal dominant polycystic kidney disease found among 23 cases of patients with spontaneous intracranial hypotension. The patient was treated successfully with an epidural autologous blood patch.

Souhrn

Intrakraniální hypotenze se typicky manifestuje ortostaticky podmíněnou cefaleou. Nejčastější příčinou je únik mozkomíšního moku. Předpokládá se, že strukturální nedostatečnost dury u některých onemocnění pojiva může být odpovědná za natržení a výchlipky dury a následný únik moku. Dosud nebylo referováno o případu intrakraniální hypotenze u čínského pacienta s onemocněním pojiva. Autoři nalezli mezi 23 nemocnými se spontánní intrakraniální hypotenzí jeden případ nemocné s autozomálně dominantní polycystickou nemocí ledvin. Pacientka byla úspěšně léčena autologní epidurální krevní záplatou.

P. Lu, J. Wang, P. Xia, X. Hu

Department of Neurology, Sir Run Run Shaw Hospital, Sir Run Run Shaw Institute of Clinical Medicine of Zhejiang University Medical School, Zhejiang University, Hangzhou, Zhejiang, China

✉ Prof. Xingyue Hu
Department of Neurology,
Sir Run Run Shaw Hospital
Sir Run Run Shaw Institute of Clinical Medicine of Zhejiang University
Medical School, Zhejiang University
Hangzhou, Zhejiang 310016
China
e-mail:
xiaping01062@hotmail.com

Accepted for review: 2. 11. 2009
Accepted for print: 12. 4. 2010

Key words

spontaneous intracranial hypotension – autosomal dominant polycystic kidney – connective tissue disease

Klíčová slova

spontánní intrakraniální hypotenze – polycystická nemoc ledvin – onemocnění pojiva

proLékaře.cz | 26.11.2026

Introduction

Spontaneous intracranial hypotension (SIH) is one cause of chronic headache in adults. Pre-existing dural weakness, probably related to an underlying disorder of the connective tissue, has been considered as a probable aetiology for some patients with spontaneous spinal cerebrospinal fluid (CSF) leaks. Autosomal dominant polycystic kidney disease (ADPKD) can be a cause of fragile meningeal diverticula or simple dural tears, leading subsequently to SIH [1]. With no report to date of ADPKD with SIH in Chinese patients, the prevalence of ADPKD in patients with SIH is uncertain. We present a case of this condition occurring in a patient with ADPKD disclosed among 23 cases with SIH referred to the Department of Neurology in the Sir Run Run Shaw Hospital between January 2007 and September 2009. In all cases, ultrasound examination of the kidneys was performed. This is, to the best of our knowledge, the first report of ADPKD with SIH in China.

Case report

A 43-year-old woman with orthostatic headache was referred to our hospital for treatment. She complained of a dramatic postural headache that was virtually eliminated by lying flat but returned on standing up. She reported a history of lifting loads of fruit weighing about 15 kg in the preceding few days. The patient's mother, two brothers and two sisters all suffered from polycystic kidney disease.

Neurological examination was normal. Kidney ultrasound reported multiple cysts bilaterally as a sign of polycystic kidney disease. In contrast-enhanced cranial magnetic resonance (MR), minimal dural thickening was present, but no subdural effusion or brain sagging was noted (Fig. 1). Intrathecal gadolinium-enhanced computerized tomography (CT) myelography was performed to detect the exact location and morphology of any possible dural tear. A spinal tap was performed at the level of L4–L5 with a 22-gauge spinal needle. The CSF pressure was 5 mm H_2O. We administered 10 ml Iohexol (Omnipaque, 300 mg/ml) intrathecally. Axial, coronal, and sagittal images were obtained at the level of lumbar, dorsal, and cervical regions 30 minutes after the injection. Contrast material extravasation into the epidural area and the paravertebral region were detected on CT myelographic scans at C7/T1 and T1/T2 levels on both sides (Fig. 2). As the symptoms did not resolve despite bed rest and hydration for two weeks, an epidural blood patch was applied with a 15-ml mixture of blood and Omnipaque. Two days later, the headache was fully relieved and the patient was able to return to her daily activities. A year and three months after this treatment there were neither symptoms nor neurological findings.

Discussion

We found one case of ADPKD among 23 Chinese cases with SIH, which may be the first example of ADPKD with SIH reported in China. In our case, the clinical findings – minimal dural thickening on cranial MR exam, evidence of CSF leakage on CT imaging myelography, low CSF opening pressure, absence of lumbar puncture or other cause of CSF fistula in history, and resolution of headache within 72 hours of epidural blood patching – fulfilled the criteria for SIH laid down by the International Classification of Headache Disorders, second edition.

Spontaneous CSF leaks are the most common cause of SIH. Despite progress in understanding the clinical and imaging spectrum of the disorder, the aetiology of spontaneous CSF leak still remains undetermined. A combination of an underlying weakness of the spinal meninges and a trivial precipitating event is generally suspected. Some patients display structural spinal dural weakness [2,3], including single or multiple meningeal diverticula or dilatation of nerve root sleeves, that allow CSF to leak into the extradural space [4–6]. Autosomal dominant polycystic kidney disease (ADPKD) is one of the disorders of the connective tissues known to be associated with meningeal abnormalities [1], such as Marfan syndrome [7–10] and Ehlers-Danlos syndrome [11]. The prevalence of ADPKD remains uncertain.

Spinal meningeal diverticula or cysts have been described recently in three adult patients with ADPKD (1.7% of 178 ADPKD patients) [1]; the cysts were multiple in two patients and solitary in one. The cysts were found at the thoracic level in two of them and at the lumbar level in the third. The first two patients had a history of postural headaches. To our knowledge, there is no other report of diagnosis of ADPKD in SIH, and to date there has been no report of ADPKD in SIH in Asians.

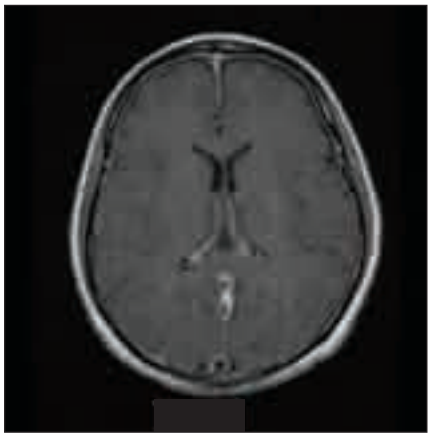

Figure 1. Enhanced magnetic resonance imaging demonstrating diffuse non-nodular, uninterrupted pachymeningeal gadolinium enhancement.

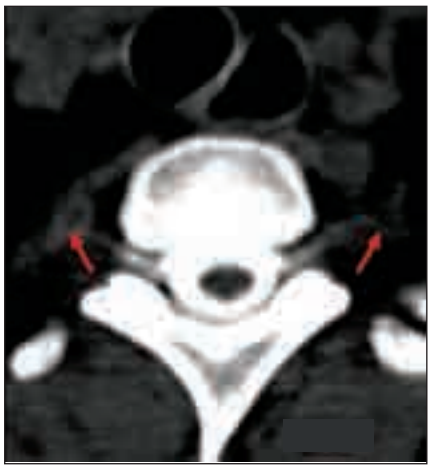

Figure 2. Computed tomography myelogram. Note extradural leakage of contrast (arrows).

ADPKD is a common heritable connective-tissue disorder associated with mitral-valve prolapse, arterial dissection, and intracranial aneurysms. It is the most frequent inherited kidney disease, with a prevalence ranging from 1 in 400 to 1 in 1,000 [12].

ADPKD is due to mutations in one of two genes, PKD1 and PKD2 [13], which code for the linked transmembrane proteins polycystin 1 and 2. Polycystins are integral membrane proteins involved in

proLékaře.cz | 26.11.2026

cell-cell/matrix interactions. The array of systemic abnormalities in polycystic kidney disease is compatible with a defect in the composition of the extracellular matrix. Aneurysms, diverticulae and various forms of hernia also clearly point to a defect in collagen matrix. We infer this may be the cause of fragile meningeal diverticula or simple dural tears.

It is highly probable that ADPKD caused severe dural weakness in our case. In our opinion, rupture of the meningeal cysts causes CSF leakage and manifestations of SIH. As a result, a new headache in patients with ADPKD should raise index of suspicion for the rupture of a meningeal cyst. Furthermore, ADPKD should be screened for in SIH patients. Further research might well be focused on the pathological mechanism and the characteristics of SIH in ADPKD.

Literature

1. Schievink WI, Torres VE. Spinal meningeal diverticula in autosomal dominant polycystic kidney disease. Lancet 1997; 349(9060): 1223–1224.

2. Donovan JS, Kerber CW, Donovan WH, Marshall LF. Development of spontaneous intracranial hypotension concurrent with grade IV mobilization of the cervical and thoracic spine: a case report. Arch Phys Med Rehabil 2007; 88(11): 1472–1473.

3. Riva-Amarante E, Simal P, San Millán JM, Masjuan J. Spontaneous intracranial hypotension due to a broken dorsal perineural cyst. Neurologia 2006; 21(4): 209–212.

4. Inamasu J, Guiot BH. Intracranial hypotension with spinal pathology. Spine J 2006; 6(5): 591–599.

5. Ishihara S, Fukui S, Otani N, Miyazawa T, Ohnuki A, Kato H et al. Evaluation of spontaneous intracranial hypotension: assessment on ICP monitoring and radiological imaging. Br J Neurosurg 2001; 15(3): 239–241.

6. Schievink WI, Morreale VM, Atkinson JL, Meyer FB, Piepgras DG, Ebersold MJ. Surgical treatment of spontaneous spinal cerebrospinal fluid leaks. J Neurosurg 1998; 88(2): 243–246.

7. Davenport RJ, Chataway SJ, Warlow CP. Spontaneous intracranial hypotension from a CSF leak in a patient with Marfan's syndrome. J Neurol Neurosurg Psychiatry 1995; 59(5): 516–519.

8. Fukutake T, Sakakibara R, Mori M, Araki M, Hattori T. Chronic intractable headache in a patient with Marfan's syndrome. Headache 1997; 37(5): 291–295.

9. Ferrante E, Citterio A, Savino A, Santalucia P. Postural headache in a patient with Marfan's syndrome. Cephalalgia 2003; 23(7): 552–555.

10. Albayram S, Bas A, Ozer H, Dikici S, Gulertan SY, Yuksel A. Spontaneous intracranial hypotension syndrome in a patient with marfan syndrome and autosomal dominant polycystic kidney disease. Headache 2008; 48(4): 632–636.

11. Schievink WI, Gordon OK, Tourje J. Connective tissue disorders with spontaneous spinal cerebrospinal fluid leaks and intracranial hypotension: a prospective study. Neurosurgery 2004; 54(1): 65–70.

12. Pirson Y CD, Grünfeld JP. Autosomal dominant polycystic kidney disease.In: Cameron JS, Davison AM,Grünfeld JP, Kerr DNS, Ritz E (eds). Oxford textbook of clinical nephrology. 2nd ed. Oxford: Oxford University Press 1998.

13. Reeders ST, Keith T, Green P, Germino GG, Barton NJ, Lehmann OJ et al. Regional localization of the autosomal dominant polycystic kidney disease locus. Genomics 1988; 3(2): 150–155.



Zlatí partneři





