

Eye Movement Examination in Neurological Practice

Vyšetření očních pohybů v neurologické praxi

Abstract

Examination of eye movements is an essential part of any comprehensive neurological examination, providing important information about the function of the central and peripheral nervous systems, the eye muscles and the orbit. A careful, systematic and precise examination may be carried out within only a few minutes. The neurologist should be able to interpret signs, to adopt a topological or syndrome-based approach and to direct diagnostic procedures. The aim of this review is to provide a basic anatomo-physiological account of eye movements, followed by an account of the examination of eye movements and a summary of the principal abnormalities that may be disclosed.

Souhrn

Vyšetření očních pohybů je důležitou součástí neurologického vyšetření, které poskytuje významné poznatky o funkci centrálního i periferního nervového systému, okohybných svalech a orbitě. Pečlivé, systematické a přesné vyšetření musí být provedeno během několika minut. Neurolog by měl být schopen interpretovat jeho nález, provést syndromologickou a topickou diagnostickou rozvahu a naplánovat další cílená vyšetření. Cílem tohoto přehledu je připomenout anatomicko-fyziologické podklady očních pohybů, ukázat postup jejich vyšetření a prezentovat hlavní patologické nálezy.

Acknowledgements

Cecilia Bonnet's work on this article was supported by Czech Ministry of Education research project MSM0021620849

We would also like to thank Sophie Rivaud-Pechoux, Dr. Claudia Brockmann and Chris Harris for their critical review of the manuscript. We also extend our thanks to Olga Kucerova for her contribution, Miriam Kovalikova for her help preparing the video, and Aaron Rulseh, MD, for preliminary English language correction.

C. Bonnet¹, J. Hanuska²,
A. Dombrowski³, E. Ruzicka¹

¹ Department of Neurology and Centre for Clinical Neurosciences, Charles University, Prague, First Faculty of Medicine and General University Hospital, Prague, Czech Republic

² Student, Charles University, Prague, First Faculty of Medicine and General University Hospital, Prague, Czech Republic

³ Freelance Artist, Bad Bramstedt, Germany



Cecilia Bonnet
Department of Neurology
Charles University, Prague,
First Faculty of Medicine
and General University Hospital
Katerinska St. 30
120 00 Prague 2
e-mail: bonnet.cecilia@gmail.com

Accepted for review: 21. 1. 2011

Accepted for print: 13. 3. 2011

Key words

eye movement examination –
oculomotor muscles – oculomotor nerve –
trochlear nerve – abducens nerve –
vestibular-optokinetic system

Klíčová slova

vyšetření očních pohybů – nervus
oculomotorius – nervus trochlearis –
n. abducens – vestibulo-optokineticý
systém

Introduction

Eye movements can be measured with extreme precision and provide a wide range of important information. The results of such eye examinations are usually rich in terms of derivable parameters, are well-documented in normal adults and in patients suffering from brain lesion, and may be used as one means of testing the functional integrity of the cortico-cortical and cortico-subcortical circuits. Examination of eye movements is an essential part of the neurological examination and places only few cognitive demands on subjects. The neurologist must be able to interpret the results that drive the diagnostic approach. The aim of this review is to provide practical information about the clinical examination of eye movements and the interpretation of potential findings.

Anatomy

Eye movements are triggered and controlled by a number of cortical and subcortical areas, apart from the vestibulo-ocular reflex and quick phases of all nystagmus, which are generated in the brain stem.

Some of the cortical areas involved in the management of eye movement are the frontal eye field, the supplementary eye field, the pre-supplementary motor area, the parietal eye field, the dorsolateral prefrontal cortex and the posterior parietal cortex. These areas project directly to the superior colliculus and indirectly through basal ganglia and the substantia nigra pars reticulata (SNpr), to the pontine nuclei (nucleus reticularis tegmenti pontis) and the cerebellum [1].

The vertical and horizontal gaze centres are situated in the brainstem. Vertical and torsional conjugate eye movements are generated in the midbrain, in the rostral interstitial nucleus of the medial longitudinal fasciculus (riMLF) [2]. The paramedian pontine reticular formation (PPRF), known in the past as the para-abducens nuclear group, is the organizing centre for horizontal gaze [2]. Vertical and horizontal gaze centres project to neurons of the oculomotor, trochlear and abducens nuclei, where the corresponding cranial nerves arise (Fig. 1).

The oculomotor nerve begins in the midbrain at the level of the superior colliculus with a cluster of somatic and visceral nerve nuclei. Somatic motor nuclei provide fascicles to the extrinsic ocular

muscles: the superior and inferior recti, the medial rectus, the inferior oblique and the levator palpebrae superioris. The visceral motor nucleus, also known as the Edinger-Westphal nucleus or the accessory oculomotor nucleus, provides parasympathetic fibres to intrinsic ocular muscles: the sphincter pupillae that regulates pupillary constriction in response to light, and the ciliary muscle that enables the lens to accommodate for near vision. The third intrinsic eye muscle, the dilator pupillae, receives sympathetic innervation via the carotid plexus. Each subunit of the oculomotor nerve is paired, apart from the caudal subunit which supplies the two levator palpebrae superioris muscles. This interesting configuration explains why it is comparatively difficult to open only one eye while the other eye remains closed [3]. The oculomotor nucleus receives inputs from the contralateral abducens nucleus via the medial longitudinal fasciculus (MLF) for the innervation of the medial rectus muscle, allowing conjugate horizontal eye movements. The fascicles of cranial nerve (CN) III exit ventrally through the brainstem into the interpeduncular cistern [4,5], pass the basilar artery, superior cerebellar artery, and travel in close proximity to the posterior communicating artery. CN III then enters the cavernous sinus, where it is in close proximity to CN IV, CN V, CN VI, and the carotid artery. In the cavernous sinus, the nerve divides into superior and inferior elements and enters the orbital apex through the superior orbital fissure together with the ophthalmic artery, CN II, CN VI, and the nasociliary branch of CN V1 [4,5].

The nucleus of the trochlear nerve (CN IV) is located in the tegmentum of the midbrain, at the level of the inferior colliculus [6]. The trochlear nerves decussate in the roof of the aqueduct before exiting from the dorsal aspect of midbrain, and run between the posterior cerebral and superior cerebellar arteries before entering the cavernous sinus. CN IV enters the orbit through the superior orbital fissure and crosses medially over the levator palpebrae superioris and superior rectus muscles before reaching the superior oblique muscle.

The nucleus of the abducens nerve (CN VI) is located in the pons, ventral to the floor of the fourth ventricle and lateral to the

MLF. The nerve contains two groups of neurons: the internuclear neurons and the motor neurons. The internuclear neurons cross the midline, ascend in the MLF to the oculomotor nerve nuclei and ensure innervation of the contralateral medial rectus muscle. The motor neurons are made up of the principal fascicle of the abducens nerve, which innervates the ipsilateral lateral rectus muscle [3]. CN VI travels between the pons and the clivus, then pierces the dura mater before continuing between the dura and the skull. At the top of the petrous temporal bone, the abducens nerve makes a sharp turn forwards to enter the cavernous sinus. In the cavernous sinus it runs alongside the internal carotid artery and enters the orbit through the superior orbital fissure.

The oculomotor, trochlear and abducens nerves control the six small extrinsic ocular muscles responsible for precise eye movement: four rectus muscles and two obliques. The medial rectus muscle adducts the eye (inwards) and the lateral rectus abducts it (outwards). The superior rectus

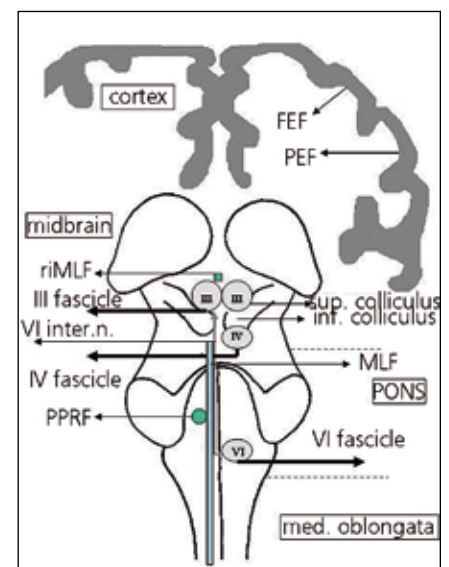


Fig. 1. Cortical and subcortical areas involved in eye movement control, coronal view.

FEF: frontal eye field; PEF: parietal eye field; MLF: medial longitudinal fasciculus; VI inter. n.: internuclear neurons of VI; PPRF: paramedian pontine reticular formation; riMLF: rostral interstitial nucleus of the medial longitudinal fasciculus; sup.: superior; inf.: inferior; med. oblongata: medulla oblongata; III: nucleus oculomotorius; IV: nucleus trochlearis; VI: nucleus abducens.

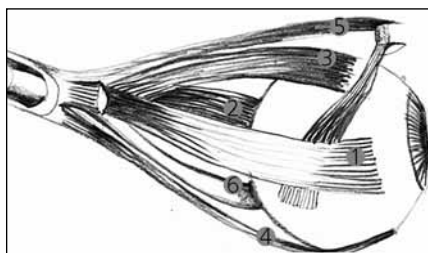


Fig. 2. Extrinsic ocular muscles, left eye viewed from centre.

1. M. medial rectus; 2. M. lateral rectus; 3. M. superior rectus; 4. M. inferior rectus; 5. M. oblique superior; 6. M. oblique inferior.

muscle elevates-adducts and slightly rotates the eye inwards, whereas the inferior rectus muscle depresses-adducts and slightly rotates the eye outwards. The oblique muscles have a predominantly rotatory pulling function. The superior oblique is the most important inward rotator, as well as depressing and slightly abducting the eye. The inferior oblique muscle rotates the eye outward, and also elevates and abducts (Fig. 2).

Neurophysiology

Clear imaging of an object requires steady fixation of its image on the central, foveal (macular) region of the retina, which contains the highest concentration of cone photoreceptors. Two main groups of eye movements facilitate this stabilization of an image on the retina and allow the line of sight to change when a new object of interest appears and needs to be directed to the fovea [2,7]. The eye movements that stabilize the image on the retina are the optokinetic reflex, the vestibulo-ocular reflex, and smooth pursuit:

- The optokinetic reflex (OKR) is induced when an entire visual scene drifts across the retina, eliciting eye rotation in the same direction at a velocity that minimizes the motion of the image on the retina. When the eyes rotate in the direction of a stimulus, their motion is periodically interrupted by rapid rotations in the opposite direction (quick phases or saccades), which reset the position of the eye for a new period of steady rotation [8].
- The vestibulo-ocular reflex (VOR) is a response analogous to head motion, with input coming from the vestibular system rather than the retina [7,8]. It

responds to rotational and translational acceleration detected by two different structures, firstly the semicircular canals, which respond to angular (rotational) acceleration, with movement in the plane of the stimulated canal, and secondly the otolith organs, which respond to linear (translational) acceleration and sustained lateral tilt of the head. The VOR implies an intact trineuronal arc composed of the vestibular ganglion, the vestibular nuclei and the ocular motor nuclei [9].

- Smooth pursuit stabilizes an image when slow movement of an object is directed to the fovea [11]. Smooth pursuit needs to suppress the VOR because in moving the head, the VOR will normally move the eyes in the opposite direction to that of movement, disturbing vision [12].

The eye movements that change the line of sight are known as the saccades and vergence:

- Saccades are rapid eye movements that move the line of sight through successive points of fixation [2,13]. They are among the most well-understood eye movements, possessing dynamic properties that are easily measured, and have become a popular means of studying motor control, cognition and several neurological diseases [1]. Saccades are the quick phases of nystagmus. They may be reflexive, triggered externally by a visual target appearing suddenly, or intentional, triggered internally by a visual target already present for a period of time, perceived a moment before (memory-guided saccade), or expected at a specific location (predictive saccade). Antisaccades, made in the direction opposite to a suddenly-appearing visual target, are also voluntary [14].
- Vergence is the movement of the two eyes in different directions to enable binocular fixation of a single object. There are two main types of vergence movements, termed fusional and accommodative. The alignment of the eyes is maintained by fusional vergence and the reflex is driven by retinal image disparity. In the normal state, retinal image disparity produces diplopia. Motor fusion then triggers a vergence response to align the images of the ob-

ject of regard on the two foveae. Accommodative vergence is stimulated by loss of image focus on the retina and occurs in association with accommodation of the lens and pupillary constriction [2,15–17].

Examination procedure

Patient history

An accurate patient history is essential to the examination of eye movements, including how long the symptoms have been present, whether pathological findings are evident in old photographs, and records of current medication.

Eye movement examination

(See also supplementary data: video on <https://el.lf1.cuni.cz/ocularmovementsexam/>)

The examiner should stand slightly to the side of the patient, since patients with cognitive impairment are accustomed to looking at the face or eyes of the examiner, and do not respond to verbal commands. The patient should be asked to sit or stand, hold the head erect and to look straight ahead. The examination starts with fixation, followed by pursuit, vergence, saccades and VOR.

1. Fixation

Examination of the eyes in primary position. The patient should view an object that requires visual discrimination on the other side of the room. Ocular alignment is determined by carefully observing the reflection of light on the cornea, which must be at the same height. This can be especially helpful in patients with ptosis or facial asymmetry. Careful inspection of the symmetry of both eyelids, pupils and head posture follows.

Each eye is then examined individually with the cover test, which may disclose heterotropia, a misalignment of the visual axes when both eyes are viewing a single target. A target that requires visual discrimination (e.g. an "E") is placed at a distance of 6 m and another at 35 cm. Firstly, with the eyes in the central position, the right eye is covered and corrective movements of the uncovered left eye are monitored. If no movement is detected, the cover is removed and the left eye covered. This test is repeated with the eyes brought to the nine cardinal positions of gaze and the whole process undertaken again with the near target [2].

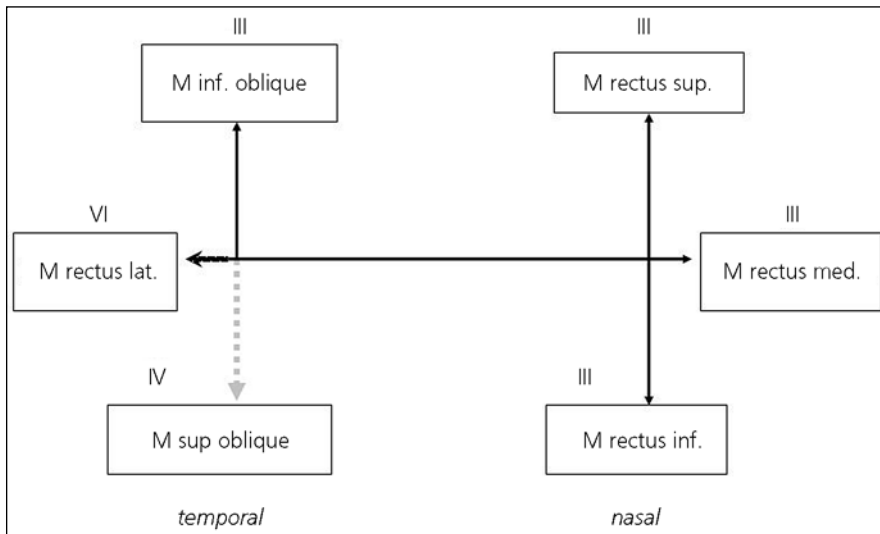


Fig. 3. Eye muscle examination.

It should be determined that each eye is able to trace a capital letter "H". In the horizontal plane, the M. medial rectus produces adduction (inward movement), and the M. lateral rectus produces abduction (outward movement). In examination of the M. superior and inferior recti, the patient is asked to look inward, then to look up and down. The M. superior rectus will elevate the eye and the M. rectus inferior will depress it. In examination of the M. superior and inferior obliqui, the patient is asked to look outwards, then to look up and down. The M. inferior oblique muscle will abduct, elevate and rotate the eye laterally and the M. superior oblique muscle will abduct, depress and internally rotate the eye.

2. Pursuit

The examiner's finger or a small target such as a pen, even a mirror, may be used for this part of the examination. The target is held approximately 60 cm in front of the patient's face and the patient asked to avoid moving the head. The target is moved horizontally then vertically, at a uniformly low speed (10–30/s), and the patient asked to follow it. Both eyes together are observed. The patient should be able to follow the target smoothly at an appropriate velocity. After this, each eye is observed separately to examine the eye muscles. Each eye should be able to trace a capital "H" (Fig. 3).

Examination of the pursuit system includes assessment of VOR suppression, which is an essential component of the smooth pursuit task during motion. The patient is asked to follow a rotating object while the head is maintained in a fixed direction (e.g. the patient stretches the hands forward, holding them together, and maintains the gaze on them while seated in a chair that is rotating). The eyes should remain stable in the

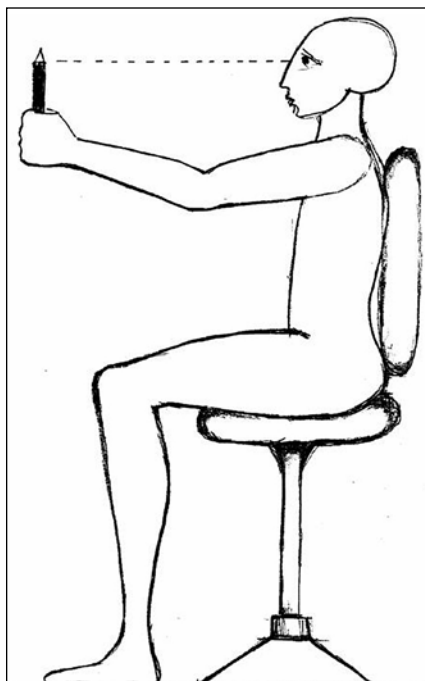


Fig. 4. VOR suppression.

The patient is asked to follow a rotating object while the head is maintained in a fixed direction (e.g. the patient stretches the hands forward, holding them together, and maintains the gaze on them while seated in a chair that is rotating).

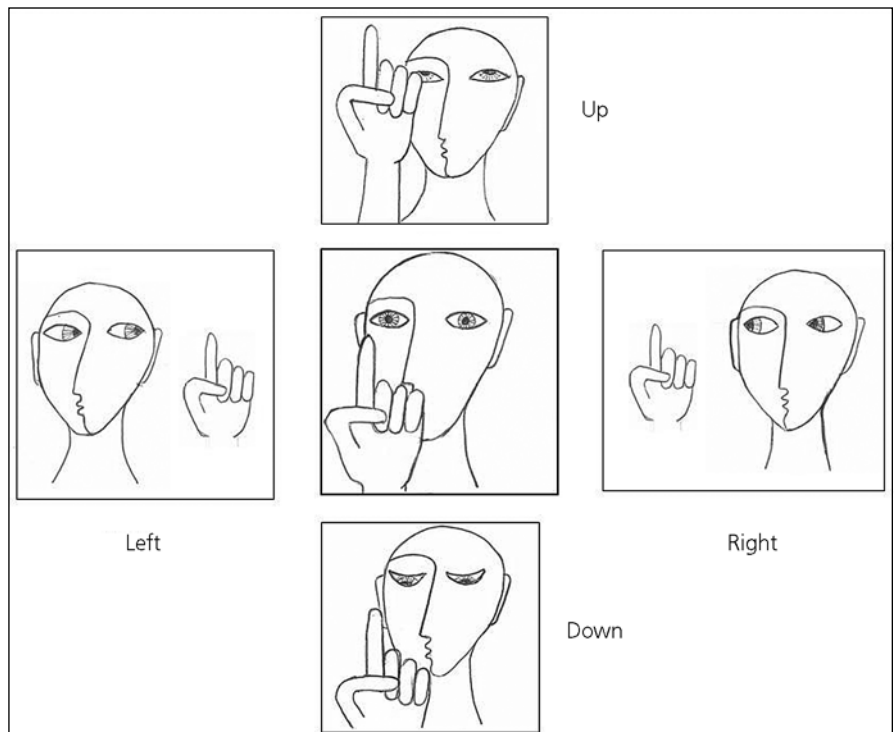


Fig. 5. Examination of saccades.

The target is placed in front of the patient and instructions given to look at it. The target is made to disappear from centre and re-appear to one side, when the patient is asked to change the line of sight and to view it. This procedure is repeated centre-right-centre-left-centre three or four times alternately. Vertical saccades are examined by alternating centre-up-centre-down-centre.

orbit, through visual fixation and suppression of VOR (Fig. 4).

3. Vergence

The patient is asked to maintain the gaze on an accommodative target that requires focus, something that is slowly brought to the bridge of the nose along the sagittal plane. The patient is also asked to shift the point of fixation alternately between a far target and a near target. Pupillary changes during convergence are noted.

4. Saccades

A target is placed approximately 60 cm in front of the patient's nose, and the patient asked to look at it. The target is moved away from centre and presented to one side, and the patient asked to change line of sight and view the target again. Avoiding large movements, this procedure is repeated centre-right-centre-left-centre, three or four times.

The vertical saccades are then examined by alternating centre-up-centre-down-centre (Fig. 5). Saccades are usually fast, accurate and conjugate. Most patients are able to initiate the saccadic eye movement (latency) as quickly as they are asked to look at the target. Latency, velocity, accuracy and conjugated movement of both eyes are noted.

5. Vestibulo-ocular reflex and optokinetic reflex

Horizontal and vertical VOR are examined by means of the head-impulse test, after Halmagyi & Curthoys (Fig. 6) [18]. The patient's head is held still in two hands and the patient asked to fix the gaze on the examiner's nose; the head is then directed rapidly and horizontally to the left and to the right. To examine vertical VOR, the patient's head is directed vertically up and down. Rotation of the head in a healthy subject should lead to rapid compensatory eye movements in the opposite di-

rection, leaving the patient still looking at the examiner's nose.

Dynamic visual acuity is the ability to resolve visual detail while the observer is moving. Motion reduces visual acuity relative to static conditions. This test provides a clinical functional measure of the vestibulo-ocular reflex (VOR) during horizontal or vertical sinusoidal head rotations at frequencies of at least 2 Hz and a rate greater than 120/s [10]. To start with, static acuity is assessed by means of the standard Snellen chart, asking the patient to read the smallest legible line on the chart. Then the patient's head is moved at about 2 Hz, at an amplitude of only 5–10 degrees in the horizontal and then the vertical, and the patient asked to read the smallest line on the chart that can be discerned. To avoid interference from the patient's memory, a different but equally difficult chart may be employed or the patient may be asked to read the line backwards during the dynamic part of the test. When the VOR system is impaired, visual acuity degrades during head movement [19].

A common method of testing the optokinetic reflex is to sit the patient inside a large, patterned optokinetic drum or to rotate the patient at a constant velocity for more than a minute with the eyes open in an illuminated room. Small-field motion induced by a drum or tape, with stripes that rotate horizontally or vertically, does not test the optokinetic system adequately, but primarily assesses the pursuit system [2].

Principal pathological findings

It is essential to record all information concerning signs and symptoms revealed by examination of eye movement. Definitions must be kept clear in order to avoid incorrect diagnosis. Definitions of the principal abnormalities and their origins appear above.

Patient history

Patients tend to seek medical advice when an eye movement disorder causes visual discomfort and/or leads to dizziness or instability.

Diplopia

Diplopia is the sensation of seeing an object at two different locations in space. The patient should be asked if it is hori-

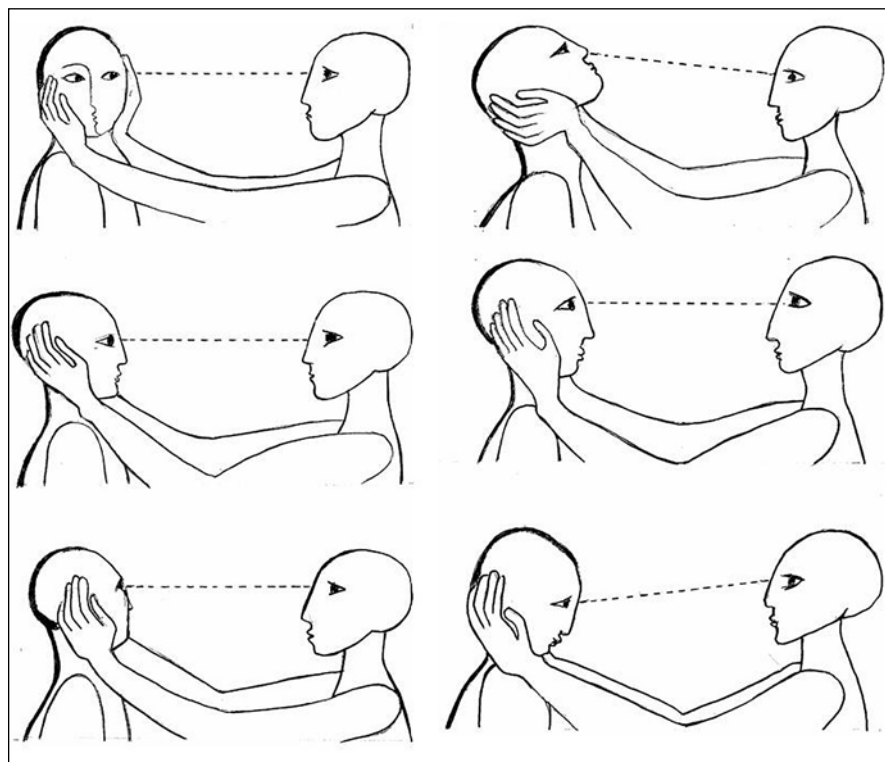


Fig. 6. VOR examination

Horizontal and vertical VOR are examined by means of the head-impulse test, after Halmagyi & Curthoys. The patient's head is held still in two hands and the patient asked to fix the gaze on the examiner's nose; the head is then directed rapidly and horizontally to the left and to the right. To examine vertical VOR, the patient's head is directed vertically up and down. Rotation of the head in a healthy subject should lead to rapid compensatory eye movements in the opposite direction, leaving the patient still looking at the examiner's nose.

zontal, vertical or torsional, and elicitation extended to the direction of gaze in which the diplopia is more marked, and if it is worse for near or distant viewing. Monocular diplopia is rare and may be caused by astigmatism, refractive errors, cataract, corneal irregularity, lens dislocation or eye trauma. Patients who complain of little or no visual disturbance despite an obvious ocular misalignment have usually had strabismus from an early age. Patients with acquired strabismus tend to close one eye to avoid diplopia [2].

Oscillopsia

Oscillopsia is an illusion of movement of the perceived world, often associated with poor visual acuity, reported by many patients with neurological disorders. This commonly occurs while the patient is walking, during head movement, driving or even when the head is still. Oscillopsia very often results from an impaired vestibulo-ocular reflex due to bilateral, peripheral or central vestibular dysfunction; from abnormal eye movements such as nystagmus; or from paresis of the extraocular muscles [2].

Vertigo

Erroneous perception of self-motion or object-motion, as well as an unpleasant distortion of static gravitational orientation.

Eye movement examination

Fixation

Several complaints may be revealed by the clinical examination, among them eyelid abnormalities, ptosis, retractions, lid nystagmus, lid opening apraxia or synkinesis.

Strabismus

Horizontal misalignment of the visual axes causing the two images of an object to fall on non-corresponding areas of the two retinas, usually giving rise to diplopia.

Skew deviation

Vertical misalignment of the eyes caused by damage to the prenuclear vestibular input to the oculomotor nuclei. Skew deviation may arise out of a lesion in the utricle, the MLF, the midbrain, the cerebellum, the vestibular cortex or the thalamus. It may also be a transient finding associated with raised intracranial pressure associated with supratentorial tumours or pseudotumours.

Ocular tilt reaction

Head deviation, ear to shoulder, appears in some patients with skew deviation. This reaction is usually attributed to peripheral or central lesions disrupting otolithic inputs [2,20].

Nystagmus

Repetitive, rhythmic, involuntary oscillation of the eyes initiated by slow phases. Although the direction of nystagmus is defined by the direction of the fast corrective phase, it is the slow phase that reflects the underlying disorder [2].

Description of nystagmus needs to include the direction of beat, the degree, the effect of visual fixation and other provocation manoeuvres. The direction of eye motion should be described from the patient's perspective. For example, clockwise torsional rotations should correspond to rotation of the top poles of the patient's eyes to the patient's right. The planes in which the nystagmus occurs (horizontal, vertical, torsional, mixed) should be noted for each eye. Horizontal nystagmus is most often congenital or peripheral-vestibular in origin, commonly associated with a torsional component. Torsional nystagmus is usually associated with medulla oblongata lesions, such as syringobulbia and Wallenberg's syndrome. Downbeat nystagmus commonly occurs with degeneration affecting the vestibulocerebellum, lesions near the craniocervical junction, vertebral ectasia and with drug intoxications, especially lithium. Upbeat nystagmus is less well localized than downbeat nystagmus, reported largely with paramedian lesions of the medulla oblongata, but also with pontine and midbrain abnormalities [2].

Nystagmus may be also of a pendular or jerk type: (1) pendular nystagmus: sinusoidal oscillations of approximately equal amplitude and velocity; (2) jerk nystagmus: slow initiating phase with a fast corrective phase [20].

The oscillations of each eye should be compared (synchrony or asynchrony). When the direction of the oscillations differ in each eye, the condition is known as disjunctive nystagmus.

The degree of nystagmus is defined as:

- 1st grade, nystagmus only in the direction of gaze;
- 2nd grade, nystagmus also present in primary position;

- 3rd grade, nystagmus also present in the opposite direction of gaze.

Further examination involves the effect of removing fixation with Frenzel goggles. This is a sensitive method for detecting spontaneous nystagmus, in fact nystagmus due to peripheral vestibular imbalance may only be apparent under these circumstances. Fixation can also be eliminated by examining one eye with an ophthalmoscope (while the other eye is covered) and simultaneously checking for movements of the optic papilla or retinal vessels. Since the retina is behind the axis of rotation of the eyeball, the direction of any observed vertical or horizontal movement is opposite to that of the nystagmus detected with this method, i.e. a downbeat nystagmus causes a rapid upward movement of the optic papilla or retinal vessels [21]. Other clinical tests, depending on the clinical question, are positional testing, hyperventilation, the Valsalva manoeuvre and head shaking. The neuro-otologist usually induces nystagmus by caloric, galvanic or vibratory stimuli [2].

Gaze-evoked nystagmus

A drift of the eye that is only present in certain directions of gaze, gaze-evoked nystagmus is often a side-effect of medication (anticonvulsants, benzodiazepines) or toxins (alcohol). A horizontal gaze-evoked nystagmus may indicate a structural lesion in the brain stem or cerebellum. A dissociated horizontal gaze-evoked nystagmus may be present in internuclear ophthalmoplegia [22], whereas vertical gaze-evoked nystagmus is observed in midbrain lesions involving the interstitial nucleus of Cajal.

Square-wave jerks

Square-wave jerks are small saccades, from 0.5° to 5°, that cause the eyes to oscillate around the primary position. They can increasingly occur in progressive supranuclear palsy and certain cerebellar syndromes.

Ocular flutter

Intermittent rapid bursts of oscillations without intersaccadic interval, occurring in only one direction, usually horizontal.

Opsoclonus

Bursts of oscillations without intersaccadic interval, occurring in combined hori-

zontal, vertical, and torsional directions; ocular flutter and opsoclonus occur in various settings, such as encephalitis, paraneoplasia (neuroblastoma in children or other tumours in adults), meningitis, intracranial tumours, hydrocephalus, thalamic haemorrhage, multiple sclerosis, systemic disease, and drug intoxication [22].

Pursuit

Smooth pursuit is a very brisk function that varies with subject age and the ability to direct visual attention, and is influenced by medication [23–28]. Even healthy persons exhibit a slightly saccadic smooth pursuit during vertical downward gaze. For these reasons, a saccadic smooth pursuit does not always allow either an exact topographical or etiological classification [21]. Pursuit movements that do not match the target velocity necessitate corrective saccades, making the pursuit saccadic. Impaired smooth pursuit is observed in intoxication (anticonvulsants, benzodiazepines, alcohol), cerebellar or extrapyramidal neurodegenerative disorders, hereditary cerebellar diseases, cerebral lesions, and even in extraocular muscle palsy [21,29–31]. Abnormalities of smooth pursuit may also be encountered in some individuals with congenital forms of nystagmus [2]. Failure of VOR suppression, investigated as a part of the examination of smooth pursuit, results in an incompletely cancelled VOR that appears as a jerk nystagmus beating in the direction of rotation.

CN III palsy

Palsy of CN III may be complete or partial. A complete CN III lesion causes ptosis, a fixed, dilated pupil with paralysis of accommodation, resting eye position (“down and out”), and the inability to elevate, depress or adduct the eye. The opposite eyelid may droop slightly, reflecting the bilateral innervation of the lids by CN III. Incomplete CN III palsy is more common and may result from lesion at various sites along the course of the nerve from the nucleus to the muscle [2,32].

CN IV palsy

Patients with CN IV palsy usually report vertical and torsional diplopia aggravated by looking downwards and inwards, especially when reading or climbing stairs [33]. The head may be tilted away

from affected side to reduce blurred vision (the Bielschowsky sign). Accordingly, double vision increases markedly when the head is upright or tilted to the affected side (Bielschowsky test).

CN VI nerve palsy

Abducens nerve palsy is the most common of all ocular motor palsies. Patients usually present binocular, uncrossed, horizontal diplopia at its greatest when viewing distant objects and looking ipsilaterally. Abduction is restricted or slowed, and there is an esotropia (the eyes are “crossed” – while one eye looks straight ahead, the other eye is turned in toward the nose). Patients often turn the head to the affected side to minimize diplopia.

Internuclear ophthalmoplegia (INO)

This specific gaze abnormality, resulting from a lesion in the MLF, is characterized by impaired horizontal eye movement with weak adduction of one eye and abduction ataxic nystagmus of the contralateral eye. The adduction deficit identifies the INO as being either left or right, and is ipsilateral to the MLF lesion. Vertical saccades and convergence are normal.

One-and-a-half syndrome

This uncommon syndrome occurs if a lesion affects the paramedian pontine reticular formation (PPRF) and the medial longitudinal fasciculus on the same side. The eyes cannot move horizontally, except the eye contralateral to the lesion side, which can abduct. Convergence is unaffected.

Vergence

The most common vergence disorder is convergence insufficiency associated with diplopia, eye strain, fatigue, loss of concentration while reading, motion sickness, and headaches. Other vergence and accommodative anomalies are convergence excess, divergence insufficiency or excess, and vergence or accommodative insufficiency.

Convergence insufficiency may be present in some forms of childhood strabismus. Acquired disorders of vergence include the effect of some sedative drugs and alcohol, Parkinson’s disease, progressive supranuclear palsy, midbrain lesions and parietal lesions [2]. One rare condition is spasm of convergence, in which

the eyes intermittently converge or turn towards each other. This phenomenon causes diplopia, blurred vision, miosis and episodic adduction of one or both eyes. It may be a sign of an organic lesion or of a functional disorder. Organic forms include thalamic esotropia, brainstem and cerebellar disorders, Wernicke-Korsakoff syndrome, vertebrobasilar ischemia, Chiari malformations, posterior fossa tumours, multiple sclerosis, and metabolic disturbances [2].

Saccades

Disorders of saccadic velocity

- Saccades of small amplitude, appearing too fast (increased peak velocity-amplitude relationship), may be seen in myasthenia gravis, tumours of the globe, flutter and opsoclonus.
- Slow saccades are present in abnormalities of the extraocular muscles, oculomotor nerve palsy, internuclear ophthalmoplegia, in central neurological disorders and in pharmaceutical intoxication, especially that of anticonvulsants or benzodiazepines.
- Slowing of horizontal saccades is generally observed in pontine lesions after dysfunction of the ipsilateral PPRF.
- Slowing of vertical saccades indicates a midbrain lesion in which the rostral interstitial nucleus of the MLF is involved, such as in ischemic, inflammatory and neurodegenerative diseases, especially progressive supranuclear palsy.

Disorders of saccadic accuracy

- Hypermetric saccades are saccades of high amplitude; the patient will look over and past the target (overshoot), and will need a corrective back saccade to re-attempt to find the target. These indicate lesions of the cerebellum (especially the vermis) or the cerebellar pathways. Patients with Wallenberg syndrome make hypermetric saccades in the direction of the side of the lesion.
- Hypometric saccades are saccades of low amplitude; the subject will need to make more than one saccade to attempt to find the target. These occur in a variety of cerebellar, cerebral hemisphere and brain stem disorders.

Disorders of saccadic initiation

Saccadic latencies increase in patients with amblyopia and hemispheric lesions,

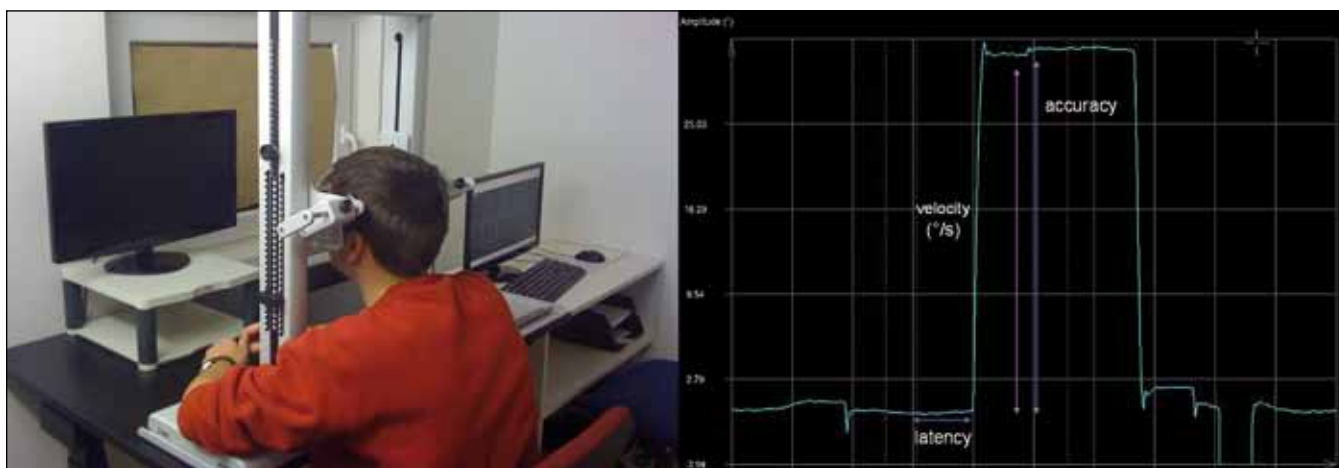


Fig. 7, 8. Eye movement recording with video-based infrared oculography (infra-red eye tracking).
 The investigation takes place in an optically and acoustically shielded room. The patient sits, with the head stabilised by a chin rest, in a comfortable chair. The screen carried a horizontal and vertical array of red light-emitting diodes. Visually guided saccades are presented for horizontal and vertical directions. Movements of both eyes are recorded at a sampling rate of 300 Hz. The following parameters are extracted separately for left, right, up, and down: (1) gain or accuracy, (2) saccade peak velocity, (3) saccade latency.

especially those affecting the cortical eye fields. Bilateral frontoparietal lesions produce a severe defect of saccade initiation known as ocular motor apraxia. Other disorders causing increased latencies are Huntington’s disease and corticobasal degeneration [2,21].

Vestibulo-ocular reflex (VOR)

Pathology involving the neuronal substrate of the VOR gives rise to changes in gain, direction of VOR and postural imbalance [2]. During the examination the patient will be not able to maintain target fixation. The patient will perform a corrective (catch-up) saccade to fix the target again, or will not move the eyes at all. Frequent causes of abnormalities of the VOR are:

- unilateral peripheral vestibular disorder, lesion of the labyrinth or of the vestibular nerve;
- bilateral peripheral vestibular disorders, due to bilateral eighth nerve section, aminoglycoside intoxication, or toxic, infectious, neoplastic, autoimmune, traumatic or inflammatory processes;
- central vestibular disorders due to infarct, haemorrhage, tumour, trauma or infection.

Eye movement recording

There are three main ways in which to record eye movements to a high degree of accuracy:

- electro-oculography: a large range of horizontal movements may be recorded

by quantifying the corneo-retinal potential using skin surface electrodes. This method is applicable for children and poorly cooperative patients. Disadvantages are common lid artefacts, the requirement for repeat calibration, adaptation to level of ambient lighting and its inability to measure vertical eye movements;

- magnetic search coil technique: allows the measurement of eye movements in all directions using the scleral annulus, but is expensive and invasive;

- video-based infrared oculography (infra-red eye tracking) is the most frequently used method. A light source is used to produce reflections on the surface of the eye. Tracking the relative movements of these images gives an eye position signal. A video image is digitized and analyzed with computer software to calculate the position of the pupil and its centre. This method allows rapid and reliable recording of horizontal and vertical eye movements.

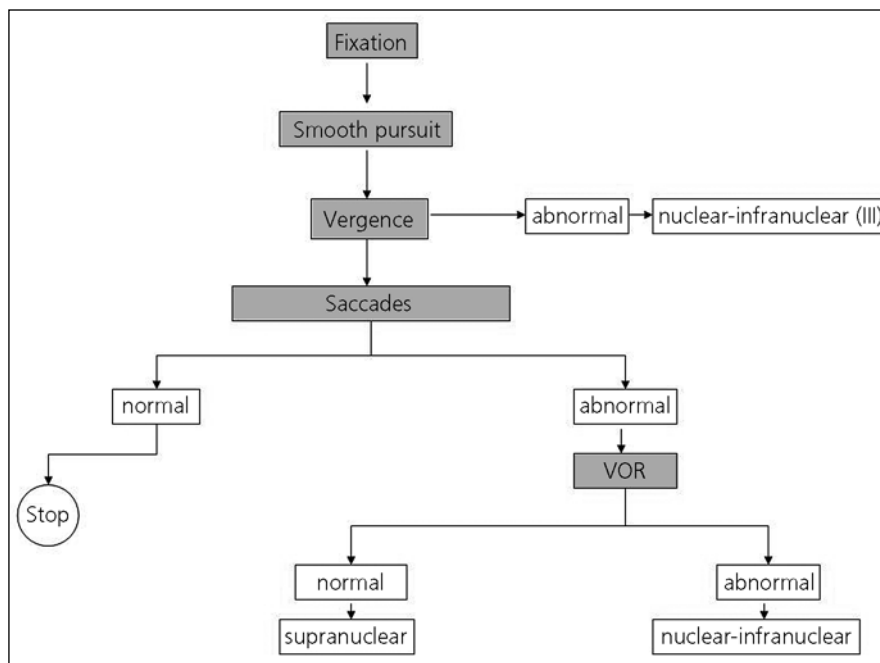


Fig. 9. Eye movement examination in clinical practice.

Different oculomotor paradigms are used in the laboratory to measure eye movements. We measure smooth pursuit and saccades (velocity, latency and accuracy). Saccades may be tested using visually stationary or moving targets, combined with head movements, both reflexive and memory-guided. The control of voluntary saccades may be tested with an antisaccade paradigm. In this task, the subject is required to suppress a saccade towards a stimulus that appears at the periphery of vision, and instead to generate a voluntary saccade of equal size towards the opposite side [2]. (Fig. 7, 8)

Conclusion

Examination of eye movement must be systematic, accurate, easy to perform, and place few demands on patients. The examination should begin by exploring fixation and smooth pursuit, and go on to investigate vergence. If vergence is abnormal the lesion will be probably be nuclear (CN III) or infranuclear. Finally, the saccades should be explored: if these are normal, the examination may cease. If they are abnormal, VOR is next. Should VOR be normal, the origin of the eye movement disorder will be probably be supranuclear, whereas if VOR is abnormal, the problem should be nuclear or infranuclear. (Fig. 9, adapted from Vignal et al [33])

Note: Supplementary data (video) associated with this article is available on the website of Charles University, Prague, First Faculty of Medicine and General University Hospital, Prague,

Czech Republic: <https://el.lf1.cuni.cz/ocularmovementsexam/>.

References

1. Leigh RJ, Kennard C. Using saccades as a research tool in the clinical neurosciences. *Brain* 2004; 127(3): 460–477.
2. Leigh Z, Zee DS. *The Neurology of Eye Movements*. 4th ed. New York: Oxford University Press 2006.
3. Trepel M. *Neuroanatomie*. 2nd ed. München, Stuttgart, Jena, Lübeck, Ulm: Von Urban & Fischer Verlag 1999.
4. Miller MJ, Mark LP, Ho KC, Houghton VM. Anatomic relationship of the oculomotor nuclear complex and medial longitudinal fasciculus in the midbrain. *AJNR Am J Neuroradiol* 1997; 18(1): 111–113.
5. Porter JD, Guthrie BL, Sparks DL. Innervation of monkey extraocular muscles: localization of sensory and motor neurons by retrograde transport of horseradish peroxidase. *J Comp Neurol* 1983; 218(2): 208–219.
6. Brazis PW. Palsies of the trochlear nerve: diagnosis and localization – recent concepts. *Mayo Clin Proc* 1993; 68(5): 501–509.
7. Robinson DA. The purpose of eye movements. *Invest Ophthalmol Vis Sci* 1978; 17(9): 835–837.
8. Cahill H, Nathans J. The optokinetic reflex as a tool for quantitative analyses of nervous system function in mice: application to genetic and drug-induced variation. *PLoS One* 2008; 3(4): e2055.
9. Szentagothai J. The elementary vestibulo-ocular reflex arc. *J Neurophysiol* 1950; 13(6): 395–407.
10. Rine RM, Braswell J. A clinical test of dynamic visual acuity for children. *Int J Pediatr Otorhinolaryngol* 2003; 67(11): 1195–1201.
11. Miles FA. The sensing of rotational and translational optic flow by the primate optokinetic system. *Rev Oculomot Res* 1993; 5: 393–403.
12. Barnes GR. Visual-vestibular interaction in the control of head and eye movement: the role of visual feedback and predictive mechanisms. *Prog Neurobiol* 1993; 41(4): 435–472.
13. Becker W. The neurobiology of saccadic eye movements. *Metrics. Rev Oculomot Res* 1989; 3: 13–67.
14. Pierrot-Deseilligny C, Gaymard B, Müri R, Rivaud S. Cerebral ocular motor signs. *J Neurol* 1997; 244(2): 65–70.
15. Gamlin PD, Gnadt JW, Mays LE. Abducens internuclear neurons carry an inappropriate signal for ocular convergence. *J Neurophysiol* 1989; 62(1): 70–81.
16. Judge SJ, Cumming BG. Neurons in the monkey midbrain with activity related to vergence eye movement and accommodation. *J Neurophysiol* 1986; 55(5): 915–930.
17. Mays LE, Porter JD, Gamlin PD, Tello CA. Neural control of vergence eye movements: neurons encoding vergence velocity. *J Neurophysiol* 1986; 56(4): 1007–1021.
18. Halmagyi GM, Curthoys IS. A clinical sign of canal paresis. *Arch Neurol* 1988; 45(7): 737–739.
19. Schubert MC, Minor LB. Vestibulo-ocular physiology underlying vestibular hypofunction. *Phys Ther* 2004; 84(4): 373–385.
20. Brodsky MC, Donahue SP, Vaphiades M, Brandt T. Skew deviation revisited. *Surv Ophthalmol* 2006; 51(2): 105–128.
21. Brandt T, Strupp M. General vestibular testing. *Clin Neurophysiol* 2005; 116(2): 406–426.
22. Rucker JC. An update on acquired nystagmus. *Semin Ophthalmol* 2008; 23(2): 91–97.
23. Kremenitzer JP, Vaughan HG jr, Kurtzberg D, Dowling K. Smooth-pursuit eye movements in the newborn infant. *Child Dev* 1979; 50(2): 442–448.
24. Phillips JO, Finocchio DV, Ong L, Fuchs AF. Smooth pursuit in 1- to 4-month-old human infants. *Vision Res* 1997; 37(21): 3009–3020.
25. von Hofsten C, Rosander K. Development of smooth pursuit tracking in young infants. *Vision Res* 1997; 37(13): 1799–1810.
26. Leigh RJ. The cortical control of ocular pursuit movements. *Rev Neurol (Paris)* 1989; 145(8–9): 605–612.
27. Knox PC, Bekkour T. Spatial mapping of the remote distractor effect on smooth pursuit initiation. *Exp Brain Res* 2004; 154(4): 494–503.
28. Paige GD. Senescence of human visual-vestibular interactions: smooth pursuit, optokinetic, and vestibular control of eye movements with aging. *Exp Brain Res* 1994; 98(2): 355–372.
29. Gaymard B, Ploner CJ, Rivaud-Pechoux S, Pierrot-Deseilligny C. The frontal eye field is involved in spatial short-term memory but not in reflexive saccade inhibition. *Exp Brain Res* 1999; 129(2): 288–301.
30. Pierrot-Deseilligny C, Gaymard B. Smooth pursuit disorders. *Baillieres Clin Neurol* 1992; 1(2): 435–454.
31. Optican LM, Zee DS, Chu FC. Adaptive response to ocular muscle weakness in human pursuit and saccadic eye movements. *J Neurophysiol* 1985; 54(1): 110–122.
32. Wray SH. *Neuro-Ophthalmologic diseases*. New York: Raven Press 1991: 659–697.
33. Vignal C, Miléa D. *Neuro-ophthalmologie*. Paris: Elsevier 2002.