

# A Dorsal Neurenteric Cyst of the Craniocervical Junction – a Case Report

## Neurenterická cysta kraniocervikální junkce – kazuistika

### Abstract

A neurenteric cyst (NEC) is a very rare diagnosis. These congenital lesions are defined as cysts lined by mucin-secreting epithelium, resembling that of the gastrointestinal tract. A neurenteric cyst can develop anywhere along the neuraxis, although it is predominantly found at the lower cervical and upper thoracic spinal level. The goal of surgical treatment is complete excision of the cyst, including its capsule. The authors present a case report and a review of all published similar cases.

### Souhrn

Neurenterická cysta (NEC) je velmi vzácná diagnóza. Tato vrozená vada je definována jako cysta, která je vystlána mucin secernujícím epitelem, obdobný tomu, který se vyskytuje v gastrointestinálním traktu. Neurenterická cysta se může vytvořit kdekoli podél neurální osy, ale predominantně ve spodních segmentech krční a horních segmentech hrudní páteře. Cílem léčby je chirurgická radikální resekce cysty včetně jejího pouzdra. Autoři prezentují vzácnou kazuistiku a přehled dosud publikovaných obdobných případů.

**M. Bolcha<sup>1</sup>, R. Bartoš<sup>1</sup>,  
L. Mrázková<sup>2</sup>, M. Sameš<sup>1</sup>**

Masaryk Hospital, Ústí nad Labem,  
Czech Republic:

<sup>1</sup> Department of Neurosurgery,  
JE Purkyně University

<sup>2</sup> Department of Radiology



**Martin Bolcha, M.D.**

**Masaryk Hospital, Department  
of Neurosurgery  
Sociální péče 3316/12A  
401 13 Ústí nad Labem  
e-mail: martin.bolcha@mnul.cz**

Accepted for review: 17. 6. 2010

Accepted for publication: 3. 10. 2011

### Key words

neurenteric cyst – craniocervical junction –  
medullary compression – enterogenous  
cyst – spinal dysraphism

### Klíčová slova

neurenterická cysta – kraniocervikální  
junkce – komprese míchy – enterogenní  
cysta – spinální dysrafismus

Acknowledgments: Ivana Julišová, MD,  
PhD, Biolab Praha s.r.o, bioptic, histoche-  
mical and cytological laboratory, Prague,  
Czech Republic, for histology and histo-  
logical figures.

### Introduction

English-written publications report no more than 26 histologically verified neurenteric cysts in the high cervical region, including the craniocervical junction (CCJ). Only five of these were located dorsally to the spinal cord. The authors report an ex-

ceptional case of a neurenteric cyst posterior to the medulla oblongata of the craniocervical junction, the first case published in the Czech literature. An overview of all published cases of a dorsally located neurenteric cyst of the craniocervical junction is also presented (Tab. 1) [1–5].

### Case report

#### Presentation and examination

A 27-year-old woman presented with a three months history of vertigo, cervicgia, cephalgia, dyspnoe, dysphagia and nausea with intermittent vomiting. Later paresthesia of the lower limbs ap-

Tab. 1. Review of published dorsally intradurally-extramedullary located neurenteric cysts in craniocervical junction.

	Author	Age, sex	MRI finding, cyst location	Symptoms, signs	Operative approach	Resection	Follow-up (years)	Clinical course
1	Weiss MA et al (1996) [4]	32, M	P, CCJ–C1	fever, headache, nausea, vomiting photophobia, recurrent Mollaret meningitis	suboccipital craniectomy, C1 laminectomy	radical	2	complete recovery, no meningitis recurrence
2	Zahos PA et al (1996) [5]	17, M	P, C1–C2	intermittent nonradiating neckpain	C1–C2 laminectomy	radical	x	complete recovery
3	Wagner HJ et al (1998) [3]	4,5, M	PL, MO–C2	stiffness of the neck and diffuse headache	suboccipital craniectomy, C1 laminectomy	radical	0.5	complete recovery
4	Filho FL et al (2001) [2]	30, M	P, CCJ	ataxia, numbness of the right hand, dysarthria	suboccipital craniectomy, C1 laminectomy	radical	3	complete recovery, no MRI recurrence
5	Clare I et al (2006) [1]	57, F	PL, CCJ	severe neck pain, with occipital radiation	suboccipital craniectomy, C1 laminectomy	x	x	x
6	presented case	27, F	P, CCJ–C1	vertigo, dyspnoea, swelling disturbance, dysphagia, nausea, paresthesia of lower extremities	suboccipital craniectomy, C1 laminectomy	subtotal	3	complete recovery, no MRI recurrence

P – posterior, PL – posterolateral, CCJ – craniocervical junction, MO – medulla oblongata, x – no mention

peared without weakness. She was hospitalized several times because of these symptoms, all of which increased in severity over time.

Computer tomography (CT) showed a spherical cystic lesion of a density similar to that of the cerebrospinal fluid (CSF) dorsal to the medulla oblongata with no associated spinal abnormalities. Magnetic resonance imaging (MRI) of the cervical spine revealed an unusual intradural extramedullary expansive lesion at the level of the craniocervical junction. The lesion was situated dorsolaterally, paramedially right from the medulla oblongata with mild pressure on the medulla. The size of the lesion was craniocaudal 24 mm, laterolateral 20 mm, sagittal 13 mm. MRI showed a very well bound lesion, slightly hyperintense compared to the CSF on T1-weighted as well as T2-weighted imaging, iso-intensive with the CSF in flair mode. Postcontrast images showed no enhancement, and the spinal cord was without a myelopathic signal (Fig. 1a, b).

Upon admission to our department, the patient was conscious, well oriented, with cervicalgia and cephalgia. The patient had no cranial nerve lesion, speech distur-

bance or bulbar dysfunction. She also had no motor weakness or sensory deficit.

### Surgery and histology

The patient underwent small posterior fossa craniectomy as far as the foramen magnum and C1 laminectomy in a semi-sitting position. During the operation, neuromonitoring of the XI cranial nerve, MEP and SSEP was performed. Durotomy up to C2 and opening of the cisterna magna disclosed a quite large, grayish, spherical cystic formation overlaid by a layer of the arachnoid. The cyst was released from both PICA, caudally from the CN XI that was stimulated and intact. The cyst adhered to the medulla oblongata and the vertebral arteries. Finally, a successful near radical resection from the medulla was made, although a thin layer remained on the vertebral arteries. A milky fluid was aspirated from the cyst.

Histopathological examination showed a cystic lesion lined with intestine-like epithelium, suddenly replaced with ciliated respiratory epithelium with goblet cells. Slightly squamous epithelium was also identified. Subepithelially, there was a thin layer of fibrous tissue and more pro-

nounced meningotheelial reactive hyperplasia with psammomatous-type calcifications. The histological diagnosis was an endodermal (neurenteric) cyst (Fig. 2, 3).

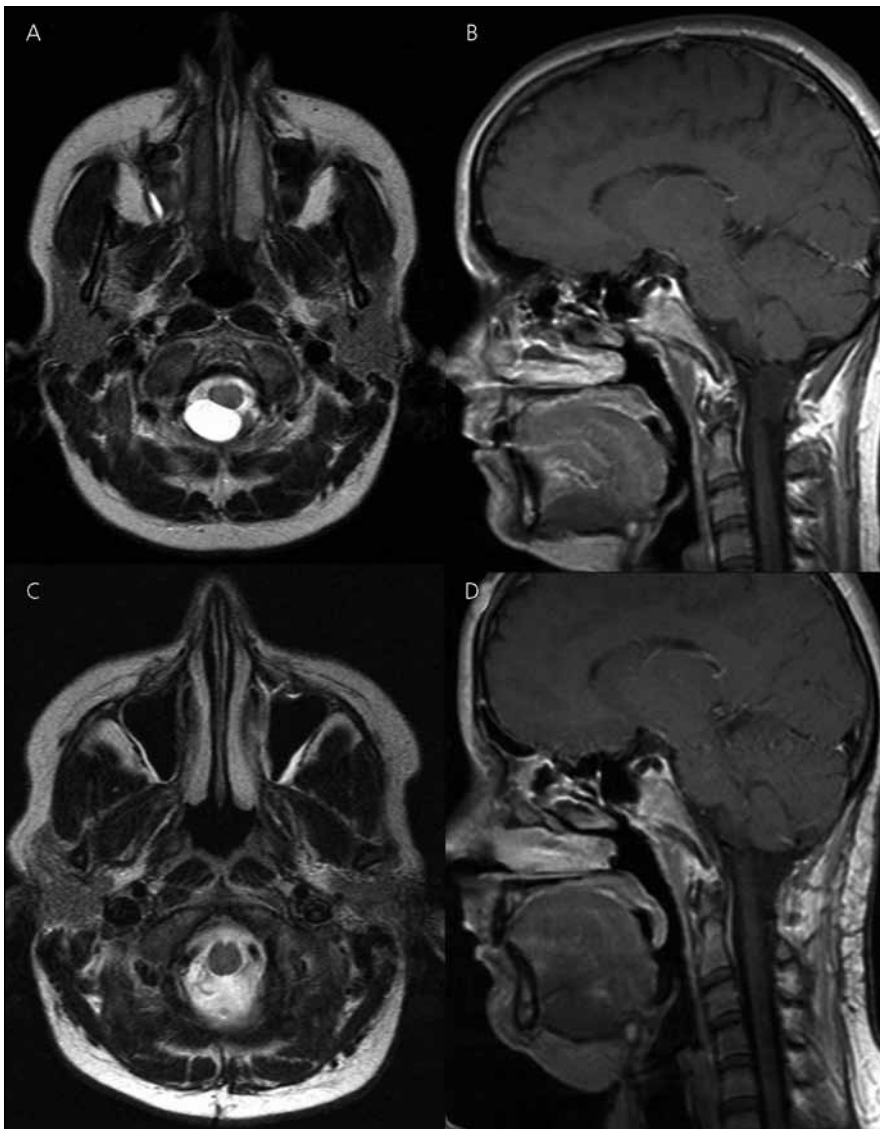
### Postoperative course

The postoperative course was uneventful. At the time of discharge, the patient was without any symptoms. Two months after the surgery, the patient reported a return of moderate limb paresthesia and vertigo related to changes in the weather. Three years after surgery, MRI examination indicated a radical resection without any recurrence (Fig. 1c, d). The patient was asymptomatic.

### Discussion

#### Definition, pathogenesis, epidemiology

A neurenteric cyst is defined as „a congenital malformation of the central nervous system and adjacent structures related to defective neural tube closure during the first trimester of pregnancy generally occurring between days 18–29 of gestation. Ectodermal and mesodermal malformations (mainly involving the skull and vertebrae) may occur as a result of defects of the neural tube closure“ [6]. An older



**Fig. 1. Preoperative MR images. Transversal projection in T2-weighted imaging also slightly hyperintense compared to the CSF (a), Sagittal projection MR showing a very well bound lesion, slightly hyperintense compared to the CSF in T1-weighted imaging (b) Postoperative MR images.**

Transversal projection in T2-weighted image three days after the surgery shows radical resection of the neurenteric cyst (c), Sagittal projection in T1-weighted imaging three years after the cyst resection without any recurrence (d).

WHO definition of the NEC is “a cyst lined by mucin-secreting epithelium, resembling that of the gastrointestinal tract” [7]. The first histologically verified neurenteric cyst was reported and termed “intestinoma” by Puusepp in 1934 [8]. Neurenteric cysts have been described using a variety of terms, such as an enterogenous or an enterogenic cyst [9,10]. At present, the term neurenteric cyst is most commonly used [6,10].

Many theories have been proposed to explain the origins of neurenteric cysts, ei-

ther isolated or associated with complex malformations. All the theories are variations on a common theme of anomalous endodermal-ectodermal adhesion in the early embryonic life – known as the split notochord syndrome [11,12]. The mesoderm, lying along the midline of the embryo, forms the notochord. During the third gestational week, the notochord transiently intercalates itself into the endoderm, bringing it into contact with the yolk sac. Simultaneously, the neurenteric canal is also formed as a passage from the

primary node in the ectoderm through the notochord to the endoderm, thus temporarily connecting the amniotic cavity with the yolk sac [10–12]. Persistence of this canal may interfere with the notochord development and result in the formation of a neurenteric cyst. Adhesions between the notochord and the endoderm may be associated with spina bifida and, extremely rarely, with the development of dorsal enteric fistula [11,12].

A neurenteric cyst may develop anywhere along the neuraxis. It is found predominantly at the lower cervical and upper thoracic spinal level, with a lower incidence at the lumbar and sacral levels [13]. In very rare cases, a neurenteric cyst may occur at the craniocervical junction, the cerebellopontine angle, the brainstem or in a brain hemisphere [10,14,15]. In the majority of cases, a spinal canal neurenteric cyst develops intradurally-extramedullary and ventrally to the spinal cord. NEC can be also associated with spinal anomalies [9,10,12,16].

Occurrence of NEC is more frequent in men than in women in a ratio of 2 : 1 [9].

### Histology

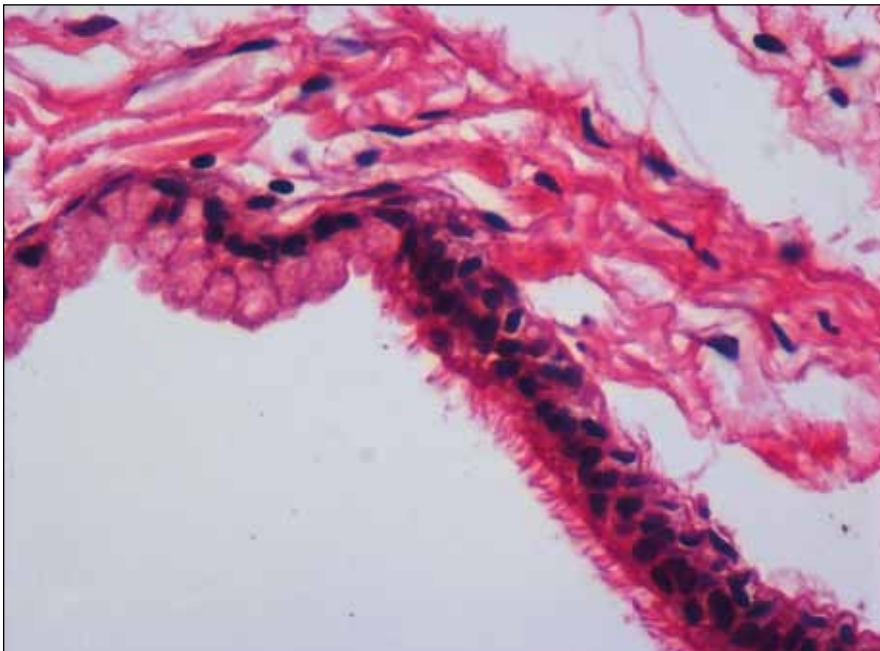Histologically, a thin-walled cyst is the most common type of a neurenteric cyst, lined by a layer of pseudostratified, stratified cuboidal or columnar epithelium lying on a basement membrane. The cyst is supported by a connective tissue wall with variable vascularity. The epithelial cells may or may not be ciliated. Frequently found are mucin-secreting, PAS reaction-positive goblet cells that are thought to be responsible for the growth of the cyst [16]. Immunohistochemical staining shows cytokeratin CAM 5.2, EMA (epithelial membrane antigen) and CEA (carcinoembryonic antigen) positivity. Conversely, neurenteric cysts are mostly GFAP (glial fibrillary acidic protein), vimentin and S-100 negative [16,17].

Ependymal cysts should be mentioned as part of histological differential diagnosis of intradural epithelial cysts; they are distinguished by GFAP positivity, no cytokeratin and little or no glycoprotein in the cytoplasm of their epithelial cells [18].

### Symptoms, imaging and differential diagnosis

Symptoms usually occur during childhood or in early adult life, most often

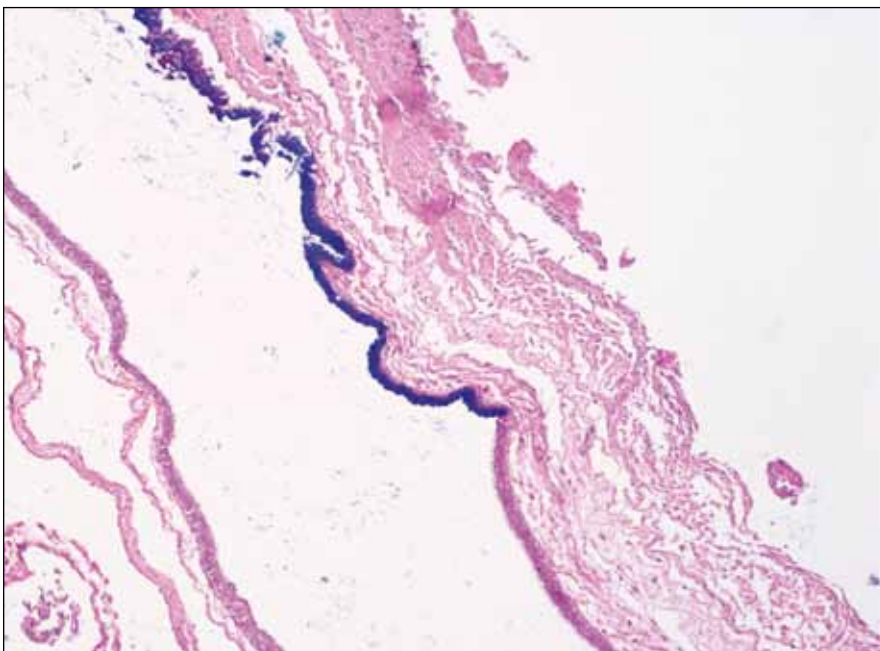




**Fig. 2. Epithelial lining of the cyst wall: intestinal-enterogenous epithelium with goblet cells suddenly replaced with columnar ciliated respiratory epithelium. Hematoxylin-eosin staining, original magnification 60x.**

during the second or third decade of life. Review of cases shows an average patient age of approximately 28 years (Tab. 1) [1–5]. The characteristic symptoms of a NEC in the CCJ include headache, mainly occipital, nuchal spasms

and, frequently, severe neck pain. Cerebellar signs, palsy of the cranial nerves and paresis of extremities may also be seen (Tab. 1) [1–5]. In one patient, neurenteric cyst was caused by recurrent Mollaret meningitis [4].



**Fig. 3. Local mucin production of the enterogenous epithelium, view of the border between the two epithelia, mucin-stained using the AB PAS method, original magnification 10x.**

MRI is the imaging modality of choice [10,12]. It provides valuable information about the nature of the cyst, including its location and signal relative to the CSF as well as its relationship with other structures, thus assisting the surgeon in planning the best surgical approach [14,15]. MRI shows NECs to be isointense to hyperintense relative to the CSF in T1-weighted images and isointense or slightly hyperintense compared to the CSF in T2-weighted images. This MRI signal characteristic results from the high protein content of the NEC, described as milky or mucinous by surgeons [10,14]. Absence of contrast enhancement and mural nodule differentiates a NEC from neoplastic lesions. CT scanning can be helpful in finding associated bone abnormalities but it may fail in visualizing the craniocervical junction.

Differential diagnosis of intraspinal cystic mass structures includes an arachnoid cyst, a dermoid cyst, an epidermoid cyst, a teratoma, a parasitic cyst, an ependymal cyst, cystic cord tumors, a cystic meningioma, and postinflammatory or posttraumatic arachnoid cysts [19].

### Therapy

Treatment of neurenteric cysts involves surgical excision of the cyst, including its capsule. An approach is selected depending on the location of the cyst. Dorsally located NECs are commonly resected using the posterior approach, as was the case in our patient [1–5].

Whenever possible, total removal of the cyst is recommended. However, it may be identified during the surgery that the cyst wall strongly adheres to surrounding neurovascular structures, in which case only subtotal extirpation is possible [1,2]. It is generally agreed in the literature that partial removal is efficacious [20].

There is no correlation between recurrence of the cyst and other factors such as age, location, sex, or size. The only factor that leads to recurrence of the cyst is partial resection [18]. Results of radical surgical treatment are excellent and recurrence is very rare [1–5, 20]. Careful radiological follow-up should be performed.

### Conclusions

A neurenteric cyst is a very rare lesion with a very good prognosis, given timely diagnosis. MRI is a gold standard imaging

method for neurenteric cysts. The characteristic symptoms of a NEC in the CCJ are headache, mainly occipital, nuchal spasms and, frequently, severe neck pain. Cerebellar signs, palsy of the cranial nerves and paresis of extremities can also be seen. The first choice approach to a posteriorly located NEC in a craniocervical junction is suboccipital craniotomy and C1 laminectomy. Clinical course in the majority of patients showed complete recovery without recurrence, even following subtotal resection.

## References

1. Clare I, Kavar B, Dobie P. Neurenteric cyst of the craniocervical junction. *Australas Radiol* 2006; 50(1): 59–62.
2. Filho FL, Tatagiba M, Carvalho GA, Weichhold W, Klekamp J, Samii M. Neurenteric cyst of the craniocervical junction. Report of three cases. *J Neurosurg* 2001; 94 (Suppl 1): 129–132.
3. Wagner HJ, Seidel A, Reusche E, Sepehrnia A, Kruse K, Sperner J. A craniospinal enterogenous cyst: case report. *Neuropediatrics* 1998; 29(4): 212–214.
4. Weiss MA, Gebarski SS, McKeever PE. Foramen magnum neurenteric cyst causing mollaret meningitis: MR findings. *AJNR Am J Neuroradiol* 1996; 17(2): 386–388.
5. Zahos PA, Goodman LA, Onesti ST, Michelsen WJ. Dorsal endodermal cyst of the upper cervical spine. *J Spinal Disord* 1996; 9(6): 536–539.
6. Joynt RJ. *Clinical Neurology*. Philadelphia: Lippincott 1992: 31–41.
7. Zülch KJ. *Histological typing Of tumours of the central nervous system*. Geneva: World Health Organization 1979.
8. Puusepp M. Variété rare de téréatome sous-dural de la région cervicale (intestinome). Quadriplégie. Extirpation. Guérison complète. *Rev Neurol* 1934; 2: 879–886.
9. Agnoli AL, Laun A, Schönmayr R. Enterogenous intraspinal cysts. *J Neurosurg* 1984; 61(5): 834–840.
10. Brooks BS, Duvall ER, el Gammal T, Garcia JH, Gupta KL, Kapila A. Neuroimaging features of neurenteric cysts: analysis of nine cases and review of the literature. *AJNR Am J Neuroradiol* 1993; 14(3): 735–746.
11. Macdonald RL, Schwartz ML, Lewis AJ. Neurenteric cyst located dorsal to the cervical spine: case report. *Neurosurgery* 1991; 28(4): 583–587.
12. Menezes AH, Traynelis VC. Spinal neurenteric cysts in the magnetic resonance imaging era. *Neurosurgery* 2006; 58(1): 97–105.
13. Rodacki MA, Teixeira WR, Boer VHT, Caropreso J, Oliveira GG. Intradural, extramedullary high cervical neurenteric cyst. *Neuroradiology* 1987; 29(6): 588.
14. Chaynes P, Thorn-Kany M, Sol JC, Arrué P, Lagarrigue J, Manelfe C. Imaging in neurenteric cysts of the posterior cranial fossa. *Neuroradiology* 1998; 40(6): 374–376.
15. Kimura H, Nagatomi A, Ochi M, Kurisu K. Intracranial neurenteric cyst with recurrence and extensive craniospinal dissemination. *Acta Neurochir (Wien)* 2006; 148(3): 347–352.
16. Fuse T, Yamada K, Kamiya K, Inagaki H. Neurenteric cyst at the craniovertebral junction: report of two cases. *Surg Neurol* 1998; 50(5): 431–436.
17. Mackenzie IR, Gilbert JJ. Cysts of the neuraxis of endodermal origin. *Neurol Neurosurg Psychiatry* 1991; 54(7): 572–575.
18. Breeze RE, Nichols P, Segal H, Apuzzo ML. Intradural epithelial cyst at the craniovertebral junction. Case report. *J Neurosurg* 1990; 73(5): 788–791.
19. Friedburg H, Schumacher M, Hennig J. Pathology of the craniocervical junction as shown by magnetic resonance tomography. 68 cases. *Fortschr Röntgenstr* 1986; 145(3): 315–320.
20. Kim CY, Wang KC, Choe G, Kim HJ, Jung HW, Kim IO et al. Neurenteric cyst: its various presentations. *Child's Nerv Syst* 1999; 15(6–7): 333–341.