

# Uncommon Endovascular Technique in Cerebral Venous Sinus Thrombosis Using an Aspiration System – a Case Report

Neobvyklé endovaskulární řešení trombózy mozkových splavů použitím aspiračního systému – kazuistika

## Abstract

A patient with ongoing cerebral venous sinus thrombosis and a parieto-occipital intracerebral haematoma was unsuccessfully treated with full-dose intravenous anticoagulation. A common endovascular aspiration technique was indicated because of the progressive severe deterioration, the level of consciousness had failed. As a novel approach, we used the 6F Neuron guiding catheter (together with The Separator 3D) inserted directly into the thrombus instead of the Reperfusion Catheter, for mechanical disruption of the thrombus mass together with continual aspiration. This procedure was safe and successful and can be used in cases of frequent aspiration catheter occlusions by a large amount of thrombus fragments.

## Souhrn

Pacient s trombózou mozkových splavů a současným intracerebrálním hematodem parieto-okcipitálně byl neúspěšně léčen plnými dávkami intravenózní antikoagulace. Vzhledem k postupné progresi klinického stavu vedoucí ke ztrátě vědomí byla indikována endovaskulární intervence. Pro časté ucpávání aspiračního systému Penumbra byl originálně použit guiding katétr Neuron (současně se Separator 3D) zavedený přímo do trombu namísto Reperfusion katétru se současnou aspirací trombu. Tento postup byl bezpečný a úspěšný a může být použit u pacientů s rozsáhlým trombotickým postižením.

Autoři deklarují, že v souvislosti s předmětem studie nemají žádné komerční zájmy.

The authors declare they have no potential conflicts of interest concerning drugs, products, or services used in the study.

Redakční rada potvrzuje, že rukopis práce splnil ICMJE kritéria pro publikace zasílané do biomedicínských časopisů.

The Editorial Board declares that the manuscript met the ICMJE "uniform requirements" for biomedical papers.

**J. Vanicek, M. Bulik**

Department of Diagnostic Imaging,  
Faculty of Medicine Masaryk University  
and St. Anne's University Hospital in  
Brno



**Martin Bulik, M.D.**  
Department of Diagnostic Imaging  
Faculty of Medicine  
St. Anne's University Hospital in  
Brno  
Pekarska 53  
656 91 Brno  
e-mail: bulik@fnusa.cz

Accepted for review: 8. 6. 2015

Accepted for print: 6. 1. 2016

## Key words

cerebral venous thrombosis – thrombectomy – endovascular – aspiration device

## Klíčová slova

trombóza mozkových splavů – trombektomie – endovaskulární – aspirační systém

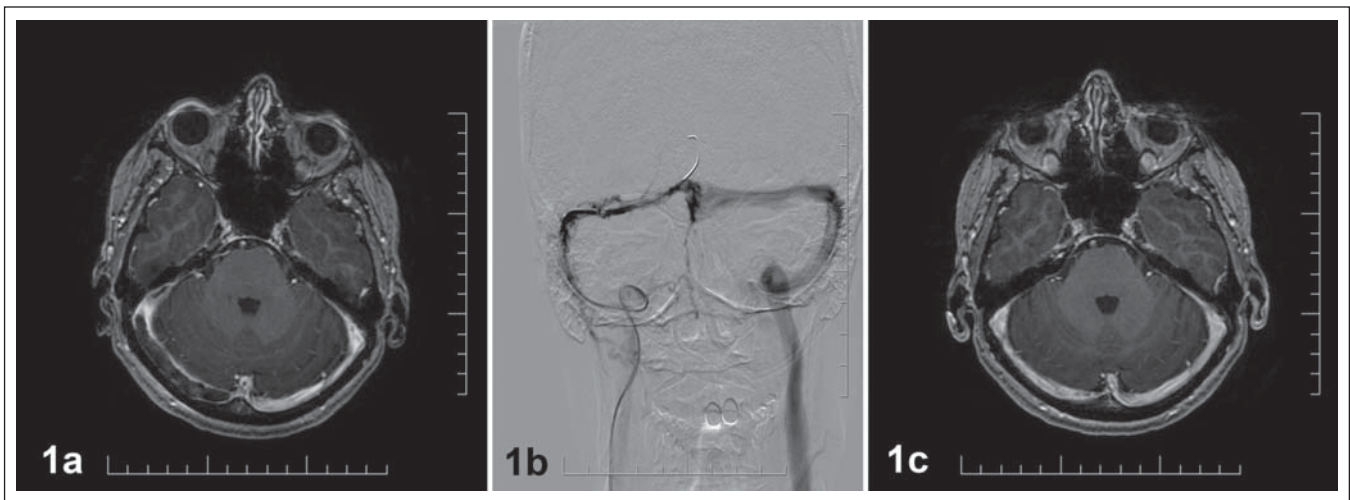
## Background and purpose

Cerebral venous sinus thrombosis is a rarely occurring but potentially serious and life-threatening type of stroke. Acute anticoagulation with either low molecular weight or unfractionated heparin represents the main intervention. Local thrombolysis or

thrombectomy is an option in patients who deteriorate despite anticoagulation or systemic anticoagulation and are at high risk, for example due to progressing intracranial haemorrhage. [1]. We present a case of a patient with progressive severe neurologic deterioration despite intensive anticoagulation.

## Case presentation

A 50-year-old, previously healthy woman with a history of oral contraceptive use was admitted to a neurology department due to intense headache, vertigo, nausea, vomiting and left-sided hemianopsia. Magnetic resonance imaging (MRI) confirmed ongoing



**Fig. 1. Imaging in cerebral venous sinus thrombosis.**

Fig. 1a) The initial MRI with a conclusion of ongoing right transverse and sigmoid sinus thrombosis with a parieto-occipital intracerebral haematoma on the right side.

Fig. 1b) Successful revascularisation was achieved and most of the patient's thrombus was aspirated.

Fig. 1c) MRI angiography four weeks after intervention revealed complete normalization of the cerebral venography finding.

ing right transverse and sigmoid sinus thrombosis (Fig. 1a) with parieto-occipital intracerebral haematoma (ICH) on the right. She was treated with full-dose low-molecular-weight heparin, according to her body weight and anti-factor Xa levels in the Stroke Unit of our hospital. The patient's progressive headache rapidly worsened and she developed left-sided haemiplegia. Repeated MRI four days after the initial examination showed thrombus growth into the superior sagittal sinus and right jugular vein, ICH volume progression and a new haematoma in the precentral region. Due to continued severe deterioration of the level of consciousness (somnia) despite full-dose anticoagulation, it was decided to immediately perform an endovascular intervention.

Cerebral angiography revealed an extensive thrombus with the largest mass in the right transverse sinus. There was no indication of local thrombolysis with respect to the enlarging intracerebral haemorrhage. Since the majority of the thrombus mass was located in the right transverse sinus, the procedure was started by advancing a 6-French Neuron guiding catheter (Penumbra, Inc., Alameda, CA) and the Penumbra System for Continuous Aspiration Thrombectomy (CAT). This was done by using a Reperfusion Catheter 054 and Separator 3D by a common accessing technique into the thrombus [2]. This procedure was unsuccessful because of frequent aspiration catheter

occlusions by a large number of thrombus fragments. The next step was inserting the distal flexible zone of the 6F Neuron guiding catheter directly into confluens sinuum. The Penumbra reperfusion catheter was pulled out and the Separator 3D, alone, was used for mechanical disruption of the thrombus mass together with continual aspiration through the 6F Neuron connected to the Penumbra Pump. During the retrograde movement of the Neuron – Separator 3D system to the right jugular vein and continuous aspiration, successful revascularisation was achieved and the majority of the patient's thrombus was aspirated (Fig. 1b). According to the control angiography, both sinuses were adequately filled with the contrast agent and its flow was presented in both the right and the contralateral jugular veins.

After endovascular treatment, the full-dose anticoagulation continued. After two days, headache disappeared and the neurologic deficit distinctly decreased. A follow-up computer tomography (CT) angiography examination performed two days after the intervention revealed a residual thrombus in the transversal sinus. Before her discharge to home care, the patient was put on oral anticoagulation. A follow-up CT angiography 10 days after the intervention, and MRI angiography four weeks after the intervention revealed complete normalization of cerebral venography (Fig. 1c). Outpatient follow-up was performed three months later with

neurologic examination revealing only minor residual left upper extremity paresis.

## Conclusion

Cerebral venous sinus thrombosis is a rare type of stroke. Ongoing presence of ICH is a common complication of this diagnosis: in 30–40% cases according to some authors [3] and its rate is even higher, around 60%, according to the recent systematic literature review by Siddiqui [4]. A recent recommendation [5] advocates the use of endovascular treatment in anticoagulation refractory patients with worsening clinical status.

Since the approval of the Penumbra System in 2007, various studies in stroke patients have been published. The use of the Penumbra System in cerebral venous thrombosis has been described in a few case series only. A case report by Siddiqui can serve as an example of good results achieved with Penumbra System with a bigger lumen (054). The report describes two cases that were successfully cured without any major complication [6]. Likewise, Choulakian described procedures in four patients without the need for chemical thrombolysis [7].

Some other devices have been successfully used for mechanical thrombectomy, the AngioJet Rheolytic catheter (Posis Medical, Minneapolis, Minnesota, USA) and the Merci Retriever device (Concentric Medical, Mountain View, California, USA) but each has their limitations.

The AngioJet's size and rigidity limits its usage in certain intracranial locations associated with lower complete recanalization rate in the Siddiqui's literature review [4] and the Merci device is not suitable for removal of large thrombus mass.

Larger controlled trials are needed to provide definitive evidence of its treatment benefit. According to our knowledge, aspiration thrombectomy using Penumbra Separator 3D in direct combination with a 6F Neuron guiding catheter, could be a safe and effective approach to mechanical clot removal in cerebral venous sinuses.

The procedure can also be considered for patients with clinical deterioration despite full-dose anticoagulation.

### References

1. Ferro JM, Canhão P. Cerebral venous sinus thrombosis: update on diagnosis and management. *Curr Cardiol Rep* 2014;16(9):523. doi: 10.1007/s11886-014-0523-2.
2. Kreusch AS, Psychogios MN, Knauth M. Techniques and results – penumbra aspiration catheter. *Tech Vasc Interv Radio* 2012;15(1):53–9. doi: 10.1053/j.tvir.2011.12.007.
3. Renowden S. Cerebral venous sinus thrombosis. *Eur Radio* 2004;14(2):215–26.
4. Siddiqui FM, Dandapat S, Banerjee C, et al. Mechanical thrombectomy in cerebral venous thrombosis: systematic review of 185 cases. *Stroke* 2015;46(5):1263–8. doi: 10.1161/STROKEAHA.114.007465.
5. Saposnik G, Barinagarrementeria F, Brown RD jr, et al. Diagnosis and management of cerebral venous thrombosis: a statement for healthcare professionals from the American Heart Association/American Stroke Association. *Stroke* 2011;42(4):1158–92. doi: 10.1161/STR.0b013e31820a8364.
6. Siddiqui FM, Pride GL, Lee JD. Use of the Penumbra system 054 plus low dose thrombolytic infusion for multifocal venous sinus thrombosis. A report of two cases. *Interv Neuroradiol* 2012;18(3):314–9.
7. Choulakian A, Alexander MJ. Mechanical thrombectomy with the penumbra system for treatment of venous sinus thrombosis. *J Neurointerv Surg* 2010;2(2):153–6. doi: 10.1136/jnirs.2009.001651.

**SAVE THE DATE**

**PRAGUE**

**12th European Congress on Epileptology**  
11-15 September 2016

Akce je zajišťována Českou neurologickou společností

**www.epilepsyprague2016.org**

ILM-CEA  
COMMISSION ON EUROPEAN AFFAIRS