

Differential Diagnosis of Bithalamic and Pallidal Hypointensity – a Case of *HEXB* Mutation

Diferenciální diagnostika bithalamické a palidální hypointenzity – kazuistika s mutací *HEXB*

Abstract

Sandhoff disease (SD) is a fatal, autosomal recessive lysosomal storage disease. Mutations in *HEXB* gene cause neuronal damage and SD due to accumulation of GM2 ganglioside. As ganglioside accumulates in the basal ganglia and white matter abnormalities occur, the T2 hypointensities of the basal ganglia, especially those of the thalamus, become observable on the magnetic resonance imaging (MRI). This is what leads to differential diagnosis. T2 hypointensities of the basal ganglia may be due to heterogeneous etiologies. Herein, we present an 18-month-old male patient who had progressive decline of motor functions, seizures, and bilateral thalamic hypointensity on T2-weighted MRI. Whole exome sequencing of the patient revealed homozygous c.1538T>C; p.Leu513Pro (RefSeq. NM_000521, GRCh38) *HEXB* mutation. Of note, our clinical findings were similar to those seen in patients with *HEXB* mutation. Exome sequencing allowed us to exclude genetic disorders with basal ganglia involvement.

Souhrn

Sandhoffova nemoc (SN) je fatální, autozomálně recesivní porucha lysozomálního katabolismu. Mutace *HEXB* genu způsobují akumulaci GM2 gangliosidu, která vede k poškození neuronů a SD. Tak jak dochází k akumulaci gangliosidů v bazálních gangliích a rozvoji abnormit bílé hmoty, jsou na magnetické rezonanci v bazálních gangliích, obzvláště thalamických, patrné T2 hypointenzity. Toho je využíváno při diferenciální diagnostice. T2 hypointenzity bazálních ganglií mohou vzniknout na základě různých etiologií. V článku prezentujeme 18měsíčního pacienta, u kterého došlo k progresivnímu zhoršování motorických funkcí, záchvatům a na T2 váženém MRI byly zjištěny bilaterální thalamické hypointenzity. Celoechomové sekvenování pacienta odhalilo homozygotní c.1538T>C; p.Leu513Pro (RefSeq. NM_000521, GRCh38) mutaci *HEXB*. Naše klinická zjištění jsou ve shodě se zjištěními popsány u pacientů s mutací *HEXB*. Sekvenování exomu umožnilo vyloučení genetických onemocnění postihujících bazální ganglia.

This work was supported by the grant of Scientific Research Projects Coordination Unit of Istanbul University, Project No. 51985 & Istanbul Development Agency, Project Number: TR10/15/YNK/0093.

Ethical approval for the study was obtained from the local ethics committee of Istanbul University. The patient was included in the study after signing a written consent form. His clinical data and MRI images were used upon obtaining a second written consent.

The authors declare they have no potential conflicts of interest concerning drugs, products, or services used in the study.

Autoři deklarují, že v souvislosti s předmětem studie nemají žádné komerční zájmy.

The Editorial Board declares that the manuscript met the ICMJE "uniform requirements" for biomedical papers.

Redakční rada potvrzuje, že rukopis práce splnil ICMJE kritéria pro publikace zasílané do biomedicínských časopisů.

N. H. Akçakaya¹, Ö. Özdemir¹,
F. G. Gökçay², S. A. U. İleri¹,
Z. Yapıcı³

¹ Institute of Aziz Sancar Experimental Medicine, Department of Genetics, Istanbul University, Istanbul, Turkey

² Department of Pediatrics, Division of Metabolic Diseases, Istanbul Medical Faculty, Istanbul University, Istanbul, Turkey

³ Department of Neurology, Division of Child Neurology, Istanbul Medical Faculty, Istanbul University, Istanbul, Turkey



Nihan Hande Akçakaya, MD
Institute of Aziz Sancar
Experimental Medicine
Department of Genetics
Istanbul University
340 93 Istanbul
Turkey
e-mail: nhakcakaya@gmail.com

Accepted for review: 1. 12. 2016

Accepted for print: 8. 3. 2017

Key words

thalamic hypointensity – Sandhoff disease – *HEXB* gene – T2-weighted images – magnetic resonance imaging

Klíčová slova

thalamická hypointenzita – Sandhoffova nemoc – gen *HEXB* – T2 vážené obrazy – magnetická rezonance

Introduction

Mutations may take place in genes encoding the alpha (Tay-Sachs disease) or beta (Sandhoff disease; SD) subunit of the hexosaminidase A or the GM2 activator protein (in the AB variant), and this paves the way for GM2 gangliosides [1,2]. In SD, the mutations in *hexosaminidase beta subunit (HEXB)* gene on chromosome 5q13 lead to neuronal damage due to accumulation of GM2 ganglioside. SD can be divided into the following three forms based on age of onset: infantile, juvenile and adult. In clinical practice, classic infantile-onset form mostly presents itself between 3–6 months of life and causes death within a few years. Some of the main features observed in the course of SD are as follows: progressive decline of motor functions, hearing loss, cherry red spots in retina, macrocephaly, and seizures [2].

Gangliosidosis is primarily a gray matter disease. However, cerebral white matter can also be involved in these disorders. Accumulation of ganglioside in the basal ganglia and white matter abnormalities both make the T2 hypointensities of the basal ganglia, and especially those of the thalamus, more noticeable [3]. Besides, marked hypointensities in the basal ganglia on T2-weighted images (T2WI) prompts differential diagnosis of various diseases including disorders of neuro-

degeneration with brain iron accumulation (NBIA) induced by the accumulation of various substances [4].

Case

An 18-month-old male patient was admitted to the Child Neurology Clinic, Istanbul Faculty of Medicine for progressive decline of motor functions, seizures, and bilateral thalamic hypointensity on T2WI. He had consanguineous parents. His developmental milestones were normal during the first 6 months. Mental and motor deterioration began after 7 months of age. At the age of 10 months, low signal intensity was detected in the bilateral thalamus on T2WI, and high signal intensity in the white matter (Fig. 1). Epileptic seizures started at 15 months of age and his examination revealed macrocephaly, doll-like face, oculogyric crises, strabismus, generalized hypotonia, pyramidal irritation, and startle reactions. The patient was screened for inborn metabolism disorders with the results being within normal limits. Hexosaminidase A activity was also within normal limits; however, total hexosaminidase activity was very low. He showed signs of severe and rapid motor decline within a few months following his admission to our clinic. A follow-up MRI showed bilateral pallidal involvement in addition to bithalamic hypointensity (Fig. 2).

Whole exome sequencing revealed homozygous c.1538T>C; p.Leu513Pro (RefSeq. NM_000521, GRCh38) *HEXB* mutation (Fig. 3) confirmed by Sanger sequencing. Of note, our clinical findings were similar to those seen in patients with *HEXB* mutation. The parents, who were both healthy, were heterozygous carriers of the mutation. In silico tools were used (Polymorphism Phenotyping v2 and Mutation Taster), and the amino acid substitution was predicted to have a damaging effect on the protein. It needs to be mentioned that there is only one healthy person in the ExAC (Exome Aggregation Consortium) database who is a heterozygous carrier of this variant.

Discussion

SD is a rare, autosomal recessive disorder. Genetic testing is not performed routinely for the diagnosis of this disease because of its easily distinguishable clinical features and an already present enzymatic diagnostic test. Bithalamic hypointensity is a well-known feature of SD, and MRI is a very helpful tool in making differential diagnosis. It is noteworthy that the result of enzymatic tests were in support of the observation of the marked bilateral thalamic hypointensity detected on the first T2WI of the patient (Fig. 1). In the absence of these findings, the patient

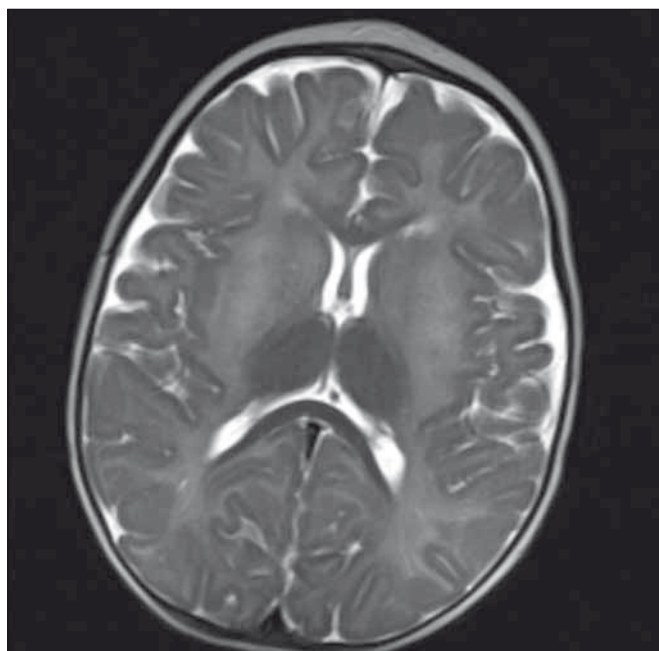


Fig. 1. Low signal intensity seen in the bilateral thalamus and high signal intensity in the white matter on T2WI at the age of 10 months.

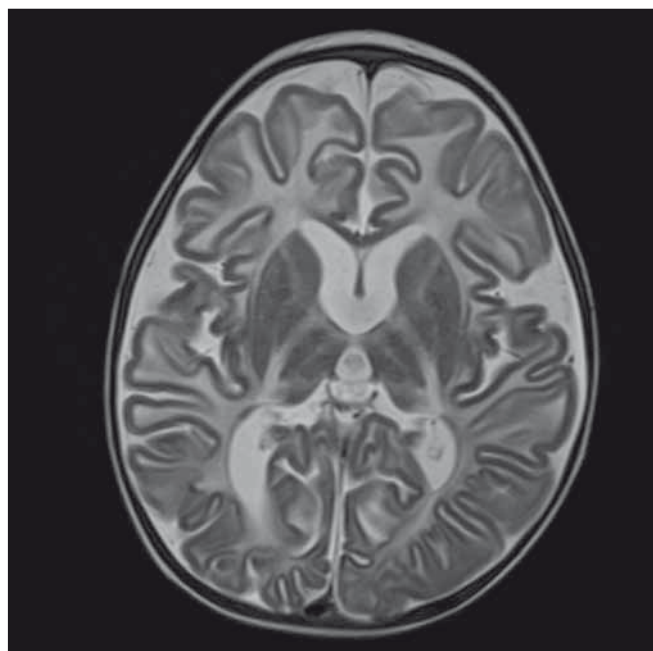


Fig. 2. Bilateral pallidal and bithalamic hypointensity seen on axial T2WI at the age of 2 years 7 months. In addition to basal ganglia hypointensities there is the diffuse white matter hyperintensity (hypo/demyelination), cortical and periventricular atrophy.

would be thought to be a carrier of the AB variant due to GM2 activator deficiency. He could have been suffering from any one of these diseases with MRI findings consistent with SD, and this should be taken into consideration during differential diagnosis.

Thalamic hypointensity on T2WI plays an important role in differential diagnosis. This is a helpful tool in making the diagnosis of lysosomal disorders. Thalamic hypointensities are reported to have been detected in patients with the below disorders: early phases of GM2 gangliosidosis, GM2 activator variant, GM1 gangliosidosis, Krabbe's disease, fucosidosis, mucopolidosis IV, aspartylglucosaminuria, mannosidosis 2, and some neuronal ceroid lipofuscinosis (CLN1, CLN2, CLN3, CLN5, CLN7) [5]. Besides thalamic involvement, macrocephaly and cherry-red spots could be considered as specific diagnostic indicators in our patient.

Apart from the thalamus, subcortical white matter, corpus striatum, internal and external capsules appear as hypointense on T2WI during the late phases of SD. T2WI axial images show symmetrical, diffuse hyperintensity in the periventricular, deep, and subcortical white matter (Fig. 2). Neurodegeneration with Brain Iron Accumulation (NBIA) disorders should be considered first when making differential diagnosis. The clinical features of NBIA range from rapid neurodevelopmental regression in infancy to mild parkinsonism in adulthood, with wide variation seen between the specific NBIA sub-type [4]. T2 hypointensity in the globus pallidus as well as in other basal ganglia is a characteristic radiographic sign observed both in the case of gangliosidosis and NBIA [2,3,6]. At this point, it should be stressed that radiological findings must be evaluated in the light of clinical findings.

Other differential diagnosis of T2 hypointensity of basal ganglia include NBIA, Wilson disease, hypoxic ischemic encephalopathy, and nonketotic hyperglycinemia. It should firmly be kept in mind that each of the above conditions has its own features, a different age of onset and rate of progression [7–9].

Metabolic tests can be deceptive, as is the case of our patient, and this may call for detailed genetic examination. As there are multiple known mutations in the *HEXB* gene, we investigated other genes that may aggravate the phenotype. According to phenolyzer.usc.edu tool, GM2A, GNPTG, GNPTAB, and HEXA are the genes related to Sandhoff phenotype. Our patient did not carry any patho-

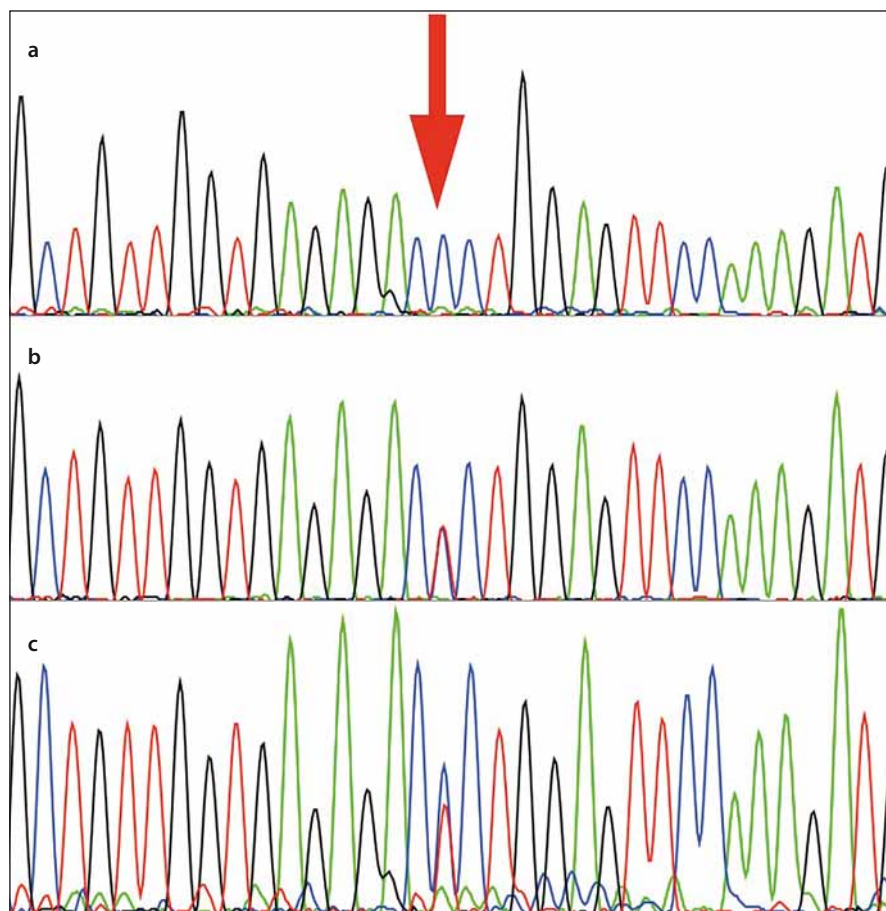


Fig. 3. Electropherogram of the patient showing the nucleotide variant at residue c.1538T>C in *HEXB* (RefSeq. NM_000521, GRCh38) (a).

Electropherogram of the father and mother, who are heterozygous carriers for the substitution (b,c).

genic variants of these genes. The *HEXB* gene has 14 exons, and the protein has enzymatically active alpha helix structures [10]. Playing an active role in enzymatic function, this mutation occurs in one of the *HEXB* alpha-helix structures and has been shown to be compatible with the infantile-onset type of SD. The clinical heterogeneity in SD appears to be related to different allelic *HEXB* mutations.

In conclusion, the authors would like to stress that comprehensive diagnostic approach involving clinical, metabolic, radiographic and genetic testing is necessary to identify individuals affected by SD.

References

1. Grevel RA, Clarke JT, Kaback MM. The GM2 gangliosidosis, in Scriver CR, Beaudet AL, Sly WS, Walle D, eds. *The Metabolic and Molecular Bases of Inherited Disease*. 7th ed. New York, McGraw-Hill, 1995:2839–79.
2. Fernandes Filho JA, Shapiro BE. Tay-Sachs disease. *Arch Neurol* 2004;61(9):1466–8.
3. Kroll RA, Pagel MA, Roman-Goldstein S, et al. White matter changes associated with feline GM2 gangliosidosis (Sandhoff disease): correlation of MR findings

with pathologic and ultrastructural abnormalities. *AJNR Am J Neuroradiol* 1995;16(6):1219–26.

4. Hogarth P. Neurodegeneration with brain iron accumulation: diagnosis and management. *J Mov Disord* 2015;8(1):1–13. doi: 10.14802/jmd.14034.

5. Autti T, Joensuu R, Aberg L. Decreased T2 signal in the thalamus may be a sign of lysosomal storage disease. *Neuroradiology* 2007;49(7):571–8. doi: 10.1007/s00234-007-0220-6.

6. Takenouchi T, Kosaki R, Nakabayashi K, et al. Paramagnetic signals in the globus pallidus as late radiographic sign of juvenile-onset GM1 gangliosidosis. *Pediatr Neurol* 2014;52(2):226–9. doi: 10.1016/j.pediatrneurol.2014.09.022.

7. Dusek P, Bahn E, Litwin T, et al. Brain iron accumulation in Wilson disease: a post-mortem 7 Tesla MRI – histopathological study. *Neuropathol Appl Neurobiol*. In press 2016. doi: 10.1111/nan.12341.

8. Ghei SK, Zan E, Nathan JE, et al. MR imaging of hypoxic-ischemic injury in term neonates: pearls and pitfalls. *Radiographics* 2014;34(4):1047–61. doi: 10.1148/rg.344130080.

9. Suárez-Vega VM, Sánchez Almaraz C, Bernardo AI, et al. CT and MR Unilateral Brain Features Secondary to Nonketotic Hyperglycemia Presenting as Hemichorea-Hemiballism. *Case Rep Radiol* 2016;2016: 5727138. doi: 10.1155/2016/5727138.

10. Mark BJ, Mahuran DJ, Cherney MM, et al. Crystal structure of human β -hexosaminidase B: understanding the molecular basis of Sandhoff and Tay-Sachs disease. *J Mol Biol* 2003;327(5):1093–109.