

# Successful Treatment of Meningoencephalitis due to *Cryptococcus gattii* with Ommaya Reservoir and Intrathecal Injection of Amphotericin B – a Case Report

## Úspěšná léčba meningoencefalitidy vyvolané *Cryptococcus gattii* Ommaya rezervoárem a intratékální injekcí amfotericinu B – kazuistika

### Abstract

Cryptococcal meningitis (CM) is a potentially fatal disease. We report successful treatment with the Ommaya reservoir and intrathecal injection of amphotericin B for the control of refractory cerebral cryptococcosis due to *Cryptococcus gattii* AFLP4/VGI. A 63-year-old male patient presented with a 2-week history of fever and headache, and was he diagnosed with CM. Combined amphotericin B and 5-flucytosine treatment was initiated and followed by fluconazole therapy. After 7 months, he was refractory to traditional CM treatment and received salvage therapy with an Ommaya reservoir and intrathecal injection of amphotericin B. His neurological symptoms recovered gradually with no evidence of relapse during 12-month follow-up. The isolate was re-identified by culturing in canavanine-glycine-bromothymol Blue media and by molecular typing using *URA5* as *Cryptococcus gattii* AFLP4/VGI. The Ommaya reservoir could serve as an alternative treatment for *Cryptococcus gattii* AFLP4/VGI-induced CM, which responds poorly to standard regimens.

### Souhrn

Kryptokokální meningitida (KM) je potenciálně fatální onemocnění. Popisujeme úspěšnou léčbu pomocí Ommaya rezervoáru a intratekální injekce amfotericinu B ke zvládnutí refrakterní cerebrální kryptokokózy způsobené *Cryptococcus gattii* AFLP4/VGI. U 63letého pacienta s hypertermií a bolestmi hlavy v trvání 2 týdnů byla diagnostikována KM. Byla zahájena kombinovaná léčba amfotericinem B a 5-flucytosinem a následována léčbou flukonazolem. Po 7 měsících byl refrakterní k tradiční léčbě KM a byla zvolena záchranná léčba pomocí Ommaya rezervoáru a intratékální injekce amfotericinu B. Neurologické příznaky postupně odezněly bez zřejmého relapsu během 12 měsíců sledování. Izolát byl přešetřen kultivací na médiu s kanavaninem, glycinem a bromthymolovou modří a molekulární typizací pomocí *URA5* byl identifikován *Cryptococcus gattii* AFLP4/VGI. Ommaya rezervoár lze doporučit jako alternativní léčbu KM vyvolané *Cryptococcus gattii* AFLP4/VGI, která špatně odpovídá na standardní léčebné režimy.

### Key words

Ommaya reservoir – intrathecal injection of amphotericin B – *Cryptococcus gattii* AFLP4/VGI – meningoencephalitis – cryptococcoma

### Klíčová slova

Ommaya rezervoár – intratékální injekce amfotericinu B – *Cryptococcus gattii* AFLP4/VGI – meningoencefalitida – kryptokokoma

The authors declare they have no potential conflicts of interest concerning drugs, products, or services used in the study.

Autoři deklarují, že v souvislosti s předmětem studie nemají žádné komerční zájmy.

The Editorial Board declares that the manuscript met the ICMJE "uniform requirements" for biomedical papers.

Redakční rada potvrzuje, že rukopis práce splnil ICMJE kritéria pro publikace zasílané do biomedicínských časopisů.

Ch. Chang-Hua<sup>1</sup>, W. Shao-Hung<sup>2</sup>,  
Y. Hua-Cheng<sup>3</sup>, W. Wang-Fu<sup>4,5</sup>,  
Ch. Wei Liang<sup>6</sup>, Y. Yung-Jen<sup>5</sup>,  
Ch. Yu-Min<sup>7</sup>, H. Chieh-Chen<sup>8</sup>

<sup>1</sup> Division of Infectious Diseases, Department of Internal Medicine, Changhua Christian Hospital, Changhua, Taiwan

<sup>2</sup> Department of Microbiology, Immunology and Biopharmaceuticals, National Chiayi University, Chiayi City, Taiwan

<sup>3</sup> Department of Neurosurgery, Changhua Christian Hospital, Changhua, Taiwan

<sup>4</sup> Department of Neurology, Changhua Christian Hospital, Changhua, Taiwan

<sup>5</sup> Tsao-Tun Psychiatric Center, Ministry of Health and Welfare, Nan-Tou, Taiwan

<sup>6</sup> Department of Medical Imaging, Changhua Christian Hospital, Changhua, Taiwan

<sup>7</sup> Department of Pharmacy, Changhua Christian Hospital, Changhua, Taiwan

<sup>8</sup> Department of Life Science, National Chung Hsing University, Taichung, Taiwan



Chen Chang-Hua, MD  
Division of Infectious Diseases  
Department of Internal Medicine  
Changhua Christian Hospital  
135 Nanhsiao Street  
Changhua 500  
Taiwan  
e-mail: 76590@cch.org.tw

Accepted for review: 25. 8. 2016

Accepted for print: 2. 1. 2017

## Introduction

Cryptococcal meningitis (CM) is a potentially fatal disease caused by infection with *Cryptococcus* spp. *Cryptococcus neoformans* (*C. neoformans*) and *Cryptococcus gattii* (*C. gattii*) are the most commonly isolated pathogenic *Cryptococcus* species, and the taxonomy of their species complexes has been revised [1,2]. CM is a global invasive mycosis associated with significant morbidity and mortality [3,4] from neurological complications [4–6]. *C. gattii*, formerly known as *C. neoformans* var. *gattii*, has been recognized as an endemic pathogen since the 1990s [5–7]. Those infected with *C. gattii* tend to be younger patients with meningitis but without underlying conditions [8,9]. Whether the immune function of the host or different *C. gattii* subtypes contribute more to poor prognoses, pathogenesis is still being debated [10,11].

Intensive induction therapy with amphotericin B (AmB) and 5-flucytosine (5-FC) is a standard practice to improve the outcome of the central nervous system (CNS) infections caused by *C. gattii* [4,5,12,13]. However, response to this typical combination regimen varies and high mortality is seen in treated patients with complicated CM [4]. Owing to the low permeability of the blood-brain barrier to the majority of antifungal agents, these parenteral treatments are not always effective, resulting in treatment-refractory

CM. Although the majority of CM treatment guidelines discouraged or rarely considered the use of adjunctive intrathecal or intraventricular administration of antifungal agents, this approach may be an option for patients with poor treatment response. The Ommaya reservoir, originally invented in 1963 by Pakistani neurosurgeon A. K. Ommaya, facilitates delivery of intrathecal medication (e.g. antibiotics, chemotherapy) [14].

Here, we present a case of a 63-year-old male patient with cerebral cryptococcosis caused by *C. gattii* (genotype AFLP4/VGI), acute severe hydrocephalus, and cryptococcoma, who failed to respond to conventional parenteral treatments.

## Case report

A previously healthy 63-year-old male patient developed a fever and headache that persisted for 3 weeks. Prior to his first hospitalisation at Changhua Christian Hospital, he had received treatment for 2 weeks, without a definite diagnosis. Upon his arrival at the emergency room, physical and neurological examinations revealed a fever (39°C), severe headache, neck stiffness, and a positive Brudzinski's sign. He reported no history of blurred vision, double vision, neck pain, or change in consciousness. We performed computed tomography (CT) of the brain and a subsequent lumbar

puncture. India ink-positive yeast was identified in the cerebrospinal fluid (CSF; Tab. 1) and CM was diagnosed. Later, magnetic resonance imaging (MRI) of the brain showed enhanced cortical nodules and mild hydrocephalus (Fig. 1A). We also investigated potential risk factors for CM by assessing immunity parameters and testing for human immunodeficiency virus (HIV) and other systemic or malignant diseases. All findings were negative. He was then hospitalized and treated with intravenous AmB (0.7 mg/kg/day) and 5-FC (100 mg/kg per day, 4-times a day). His clinical symptoms subsided 4 weeks later and a consolidation therapy regimen with oral fluconazole (FLC) (450 mg per day orally) was administered for 3 months following discharge. Owing to seizure attacks, he was re-hospitalized. Follow-up CSF analysis indicated that the cryptococcal infection was still present. We prescribed intravenous AmB (0.7 mg/kg/day) and oral 5-FC (100 mg/kg/day) for 2 weeks, followed by 6 weeks of treatment with intravenous FLC (6 mg/kg/day). He was then discharged, as the signs of clinical infection appeared to be under control. Oral FLC (450 mg/day) was prescribed for consolidation therapy.

He was re-admitted 4 months after his second hospitalization owing to general weakness, changes in consciousness, and unfavorable CSF data (Tab. 1). Follow-up MRI

Tab. 1. Serial CSF findings of *Cryptococcus gattii* infection.

	Unit	Day 1	Day 14	6 weeks	3 months	Before Ommaya	After Ommaya 1 month	After Ommaya 2 months	After Ommaya 6 months
initial pressure (lumbar)	mmH <sub>2</sub> O	120	130	100	60	240	not performed	not performed	not performed
nucleated cells count	/μL	41	151	82	53	53	1	0	0
lymphocyte	%	49	87	81	87	95	92	0	0
close pressure	mmH <sub>2</sub> O	100	100	100	60	100	nil	nil	nil
mycological culture (CSF)		positive	negative	negative	negative	positive	negative	negative	negative
cryptococcal Ag (CSF)		> 1 : 1,024	> 1 : 1,024	1 : 64	1 : 64	1 : 128	negative	negative	negative
cryptococcal Ag (serum)		> 1 : 1,024	> 1 : 1,024	1 : 64	1 : 64	1 : 128	1 : 4	negative	negative
india ink		positive	positive	positive	positive	positive	negative	negative	negative
protein	mg/dL	158	158	260	100	125	33	26	25
glucose	mg/dL	10	19	< 10	45	50	54	63	63
glucose (serum)	mg/dL	130	130	130	120	120	120	115	126

Ag – antigen.

Tab. 2. References review of Ommaya reservoir in the management of cerebral fungal infection.

Author/ /Country/ /Year/ (Referencer)	Case number	Age/ /Gender	Risk Factors	Initial pressure (mmH <sub>2</sub> O)	Nucleated cells count in CSF (× 10 <sup>6</sup> /L)	Mycological culture in CSF	Cryptococcal Ag in CSF	Regimen	Response to standard regimen	Indication for Ommaya reservoir	Intra- theal therapy	Outcome
Chen CH/ /Taiwan/ /2015/this	1	63/M	negative	120	41	CryGat	> 1 : 1,024	AmB + + 5-FC + + FLC	no good, due to Cryp- TCOma	NeuDe	AmB <sup>I</sup>	recovered, after 3 month
Nakama T/ /Japan/2015/ /(Nakama et al.,2015)	10	57 (mean)/ /M(5) F(5)	pregnancy (1), DM (2), renal failure (1), rheuma- toid arthritis (1), liver cirrhosis (1), hepatocellular carcinoma (1), chronic obstructive pulmonary disease (1), sarcoidosis (1)	NM	NM	CryNeo (10)	NM	NM	no good response (10)	NM	NM	death (3/ /10,30%)
Jiang PF/ /China/2010/ /(Jiang et al., 2010)	1	12/M	NM	130	400	CryNeo	NM	AmB + + 5-FC + + FLC <sup>2</sup>	no good response due to IICP	IICP <sup>3</sup>	NM	recovered, after 5 month
Jiang PF/ /China/2010/ /(Jiang et al., 2010)	1	7/F	negative	140	400	CryNeo	NM	AmB (1,582.2 mg)	no good response due to IICP	IICP after 4 months therapy	NM	recovered, after 4 month
Mohan S/NY, USA/2006/ /(Mohan et al., 2006)	1	41/M	human immunodeficiency virus infection with acquired immune deficiency syndrome status	38	460	CryNeo	> 1 : 32	AmB + + 5-FC <sup>4</sup>	no good response due to craniopathies	craniopathies <sup>5</sup>	NM	complete resolution <sup>6</sup>
Vakis/Greece/ /2005/(Vakis et al., 2005)	1	66/M	chronic lymphocytic leukemia	NM	> 250	<i>Cryptococcus</i> sp.	1 : 100 dilutions <sup>7</sup>	NM	NM	IICP	NM	Ommaya was removed <sup>8</sup>
Hamilton JF/MI, USA/ /2003/ (Hamilton et al., 2003)	1	14/M	DM	NM	NM	Mucor sp.	NM	NM	NM	drainage of the largest cavity	NM	complete resolution
Adler DE/NY USA/1998/ /(Adler et al., 1998)	1	16/M	DM	NM	NM	<i>Rhizopus oryzae</i>	NM	AmB + 5-FC	NM	drainage of the largest cavity	NM	complete resolution 2 years later

Tab. 2 – continuing. References review of Ommaya reservoir in the management of cerebral fungal infection.

Author/ /Country/ /Year/ (Referencer)	Case number	Age/ /Gen- der	Risk Factors	Initial pressure (mmH <sub>2</sub> O)	Nucle- ated cells count in CSF (x 10 <sup>6</sup> /L)	Mycolo- gical culture in CSF	Crypto- coccal Ag in CSF	Regimen	Response to stan- dard regimen	Indication for Ommaya reservoir	Intra- thecal therapy	Outcome
Huang CF/Tai- wan/1993/ (Huang et al., 1993)	21	NM	NM	NM	NM	CryNeo	NM	AmB + + 5-FC	NM	IICP (21)	NM	9 (42.9%) patients expired
Penar PL/Co- nnecticut US/ /1988/ (Penar et al., 1988)	1	60/M	NM	17	NM	CryNeo	1 : 30,000 <sup>9</sup>	AmB (40 mg/ /day)	no good response, rapid NeuDe	rapid NeuDe on Day 5 due to IICP	Nil	died 3 months <sup>10</sup>

5-FC – flucytosine; Ag – antigen; AmB – Amphotericin B; CryGat – *Cryptococcus gattii*; CryNeo – *Cryptococcus neoformans*; CryptComa – *Cryptococcoma*; CSF – cerebrospinal fluid; DM – diabetes mellitus; F – female; FLC – fluconazole; IICP – increasing intracerebral pressure; M – male; NeuDe – neurological deterioration.

Notes: <sup>1</sup> – AmB (0.25 mg/dose, 6 dose per week, intrathecal, in total 12 mg); <sup>2</sup> – AmB (from 0.2 to 1 mg/kg/day), 5-5-FC (150 mg/kg/day) and FLC (3 mg/kg/day); <sup>3</sup> – follow up opening pressure over 400 mmH<sub>2</sub>O, and the follow up brain CT scan showed increasing dilatation of lateral ventricles; <sup>4</sup> – AmB (50 mg/day) and 5-FC (6 gm/day); <sup>5</sup> – IICP and complete loss of hearing and significant deterioration of vision as well as bilateral facial palsy and bilateral sixth nerve palsy; <sup>6</sup> – complete resolution of the sixth and seventh cranial nerve palsies bilaterally by the 65<sup>th</sup> day of hospital stay; <sup>7</sup> – positive after 1 : 100 on serial dilutions; <sup>8</sup> – Ommaya-type device was removed due to cerebral abscess, and V-P adjustable shunt (Hakim Programmable Valve, Godman) was placed 2 months later; <sup>9</sup> – positive after 1 : 30,000 on serial dilutions; <sup>10</sup> – died 3 months later after Ommaya reservoir due to a gastrointestinal haemorrhage.

showed multiple new nodules and exacerbated hydrocephalus (Fig. 1C). No evidence of cryptococcal infection in the peripheral system was found. Owing to his deteriorated clinical condition, persistent unfavorable CSF data, and MRI results indicating disease progression, his family agreed to treatment with intraventricular AmB. He was treated with intraventricular AmB (0.25 mg/dose, 6 doses/week) administered by Ommaya reservoir (Model number 44111, Medtronic PS Medical Inc.) and intravenous AmB (0.7 mg/kg/day) for 8 weeks. For each injection, we withdrew 10 mL of CSF from the Ommaya reservoir, slowly infused a combination of 0.5 mL distilled water and 0.25 mg AmB into the Ommaya reservoir, and flushed with 1 mL CSF using the previously withdrawn CSF. The total dose of AmB delivered intraventricularly and that delivered intravenously was 12 mg and 3,000 mg, resp. His response to treatment was fair and he was finally discharged after 71 days of hospitalization. During the follow-up of 2 years, he received consolidated oral FLC (600 mg/day) treatment at home and was clinically stable as confirmed by follow-up CSF analysis and MRI (Fig. 1D).

Six months later, CSF isolate was re-identified and cultured on canavanine-glycine-

-bromothymol blue (CGB) medium and the isolate was identified *C. gattii sensu stricto*. Molecular taxonomy via sequencing of the URA5 gene revealed that the isolate was genotype AFLP4/VGI, representing the recently described *C. gattii sensu stricto* [2]. Antifungal susceptibility obtained by a commercially prepared, dried colorimetric microdilution panel (Sensititre YeastOne, Thermo-Fisher Scientific, West Sussex, UK) showed 0.5 mg/mL for AmB, 8 mg/mL for 5-FC, and 8 mg/mL for FLC.

**Discussion**

This is the first case report describing administration of adjunctive intra-ventricular amphotericin B via the Ommaya reservoir to treat neurological complications of *C. gattii* AFLP4/VGI-induced CM. The present report demonstrated that adjunctive intra-ventricular AmB delivered via Ommaya reservoir could represent an alternative treatment for patients with *C. gattii* AFLP4/VGI-induced CM who fail to respond adequately to conventional interventions. As intra-ventricular antifungal treatment via an Ommaya implant has been rarely utilized to treat CNS cryptococcosis, we conducted a literature review to support our course of treatment (summarized in Tab. 2). On analyz-

ing the reports, we found that Ommaya reservoirs were frequently applied in the treatment of refractory CM, notably in immunocompromised or fragile populations. Considering the disease course characteristics and poor response from our patient, the few case studies describing treatment of CM with an Ommaya reservoir suggested a potential alternative treatment for our patient. Our intervention led to eradication of *C. gattii sensu stricto* and resolution of clinical manifestations. We believe that intraventricular administration of AmB in our patient enabled more of the drug to pass through the blood-brain barrier, resulting in higher brain concentrations than with the conventional approach. The intraventricular approach also yielded practical secondary benefits, since intracranial pressure could be directly monitored and simultaneously managed at high pressure, without any further adverse effects. Although intraventricular administration of antifungal agents and decompression of intracranial pressure through an Ommaya reservoir was not the standard approach, and was even discouraged in accordance with CM treatment guidelines, we believe this intervention could be reserved as a last resort for similar clinical cases. However, there are po-

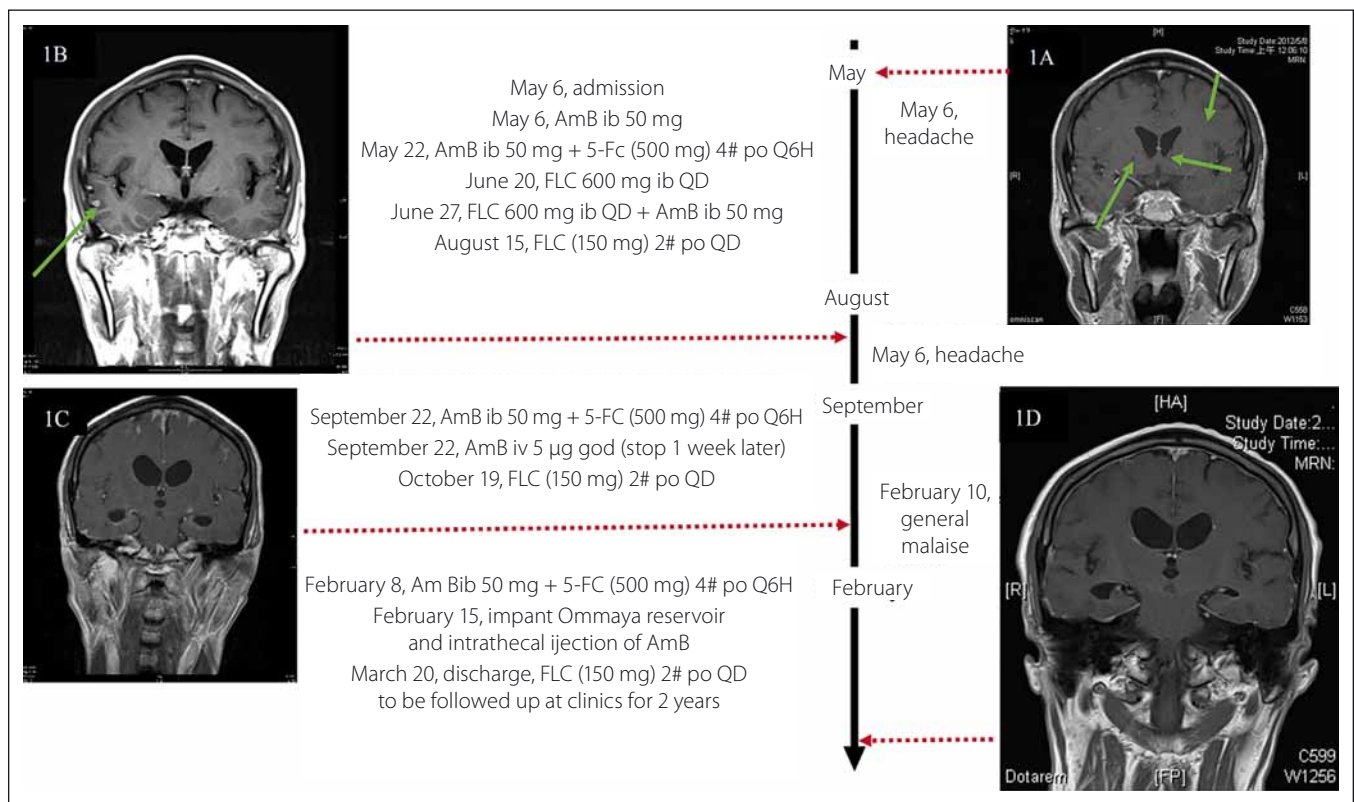


Fig. 1. Timeline of *C. gattii* AFLP4/VGI infection, the serial brain magnetic resonance imaging.

The serial magnetic resonance image (MR image) were analyzed. Fig. 1A showed initial gadolinium-enhanced T1 coronal MR images, and it showed enhanced nodules in the cortex (arrow) and mild hydrocephalus (arrow). Fig. 1B showed 1 month follow-up gadolinium-enhanced T1 axial MR image, and it also showed enhanced nodules in the cortex (arrow). Fig. 1C showed 6-months follow up gadolinium-enhanced T1 axial MR image, and it showed multiple new nodules and exacerbated hydrocephalus. Fig. 1D showed 15-months follow up brain MR image, and no new nodules and more exacerbated hydrocephalus.

tential disadvantages of intraventricular antifungal injection via an Ommaya reservoir, including device-associated infections [15], over-drainage of the CSF [16], tentorial/tonsillar herniation [17] and subdural hematoma [18].

We emphasize that physicians should pay attention to the possible complications of cryptococcal infection in patients, even during active therapy. We also stress the importance of discriminating between *C. gattii* and *C. neoformans*, using CGB medium in clinical situations, as it is necessary to achieve a positive outcome. Immunocompetent individuals are also susceptible to CM infection.

In conclusion, intraventricular administration of antifungal agents via an Ommaya reservoir could represent an alternative choice for treating patients with *C. gattii* AFLP4/VGI-induced CM, who respond inadequately to typical interventions. However, we recommend that it should only be used after attempting all other treatment options.

### All acknowledgements

The authors thank the Changhua Christian Hospital for the grant support (CCH grant 104-CCH-IRP-001, CCH grant 105-CCH-IRP-001). All authors thank the assistant of the Clinical Microbiology Laboratory of the Changhua Christian Hospital for their assistance in data collection. Authors thank Miss Yi-Chen Tseng and Miss Chi-Lun Chang, who study at Department of Microbiology, Immunology and Biopharmaceuticals, National Chiayi University, Chiayi City, for the re-identification of the isolate. This research project would not have been possible without the support of many people. The authors wish to express our gratitude to staffs of Division of Infectious Diseases, Division of Neurosurgery, and Division of Critical Care of Changhua Christian Hospital who were abundantly helpful and offered patient care, invaluable assistance, and support.

### References

- Hagen F, Khayhan K, Theelen B, et al. Recognition of seven species in the *Cryptococcus gattii*/*Cryptococcus neoformans* species complex. *Fungal Genet Biol* 2015;78:16–48. doi: 10.1016/j.fgb.2015.02.009.
- Hagen F, Hare Jensen R, Meis JF, et al. Molecular epidemiology and in vitro antifungal susceptibility testing of 108 clinical *Cryptococcus neoformans sensu lato* and *Cryptococcus gattii sensu lato* isolates

from Denmark. *Mycoses* 2016;59(9):576–84. doi: 10.1111/myc.12507.

- Chen CH, Sy HN, Lin LJ, et al. Epidemiological characterization and prognostic factors in patients with confirmed cerebral cryptococcosis in central Taiwan. *J Venom Anim Toxins Incl Trop Dis* 2015;21:12. doi: 10.1186/s40409-015-0012-0.
- Perfect JR, Dismukes WE, Dromer F, et al. Clinical practice guidelines for the management of cryptococcal disease: 2010 update by the Infectious Diseases Society of America. *Clin Infect Dis* 2010;50(3):291–322. doi: 10.1086/649858.
- Chen SC, Meyer W, Sorrell TC. *Cryptococcus gattii* infections. *Clin Microbiol Rev* 2014;27(4):980–1024. doi: 10.1128/CMR.00126-13.
- Harris JR, Lockhart SR, Sondermeyer G, et al. *Cryptococcus gattii* infections in multiple states outside the US Pacific Northwest. *Emerg Infect Dis* 2013;19(10):1620–6. doi: 10.3201/eid1910.130441.
- Del Poeta M, Casadevall A. Ten challenges on cryptococcus and cryptococcosis. *Mycopathologia* 2012;173(5–6):303–10. doi: 10.1007/s11046-011-9473-z.
- Tseng HK, Liu CP, Ho MW, et al. Microbiological, epidemiological, and clinical characteristics and outcomes of patients with cryptococcosis in Taiwan, 1997–2010. *PLoS One* 2013;8(4):e61921. doi: 10.1371/journal.pone.0061921.
- Hay RJ, Mackenzie DW, Campbell CK, et al. Cryptococcosis in the United Kingdom and the Irish

Republic: an analysis of 69 cases. *J Infect* 1980;2(1): 13–22.

10. Harris J, Lockhart S, Chiller T. *Cryptococcus gattii*: where do we go from here? *Med Mycol* 2012;50(2):113–29. doi: 10.3109/13693786.2011.607854.

11. Ngamskulrungron P, Chang Y, Sionov E, et al. The primary target organ of *Cryptococcus gattii* is different from that of *Cryptococcus neoformans* in a murine model. *M Bio* 2012;3(3):e00103-12. doi: 10.1128/mBio.00103-12.

12. Yuchong C, Fubin C, Jianghan C, et al. *Cryptococcosis* in China (1985–2010): review of cases from Chinese

database. *Mycopathologia* 2012;173(5–6):329–35. doi: 10.1007/s11046-011-9471-1.

13. Abassi M, Boulware DR, Rhein J. *Cryptococcal Meningitis: Diagnosis and Management Update*. *Curr Trop Med Rep* 2015;2(2):90–9.

14. Goudas LC, Langlade A, Serrie A et al. Acute decreases in cerebrospinal fluid glutathione levels after intracerebroventricular morphine for cancer pain. *Anesth Analg* 1999;89(5):1209–15.

15. Diamond RD, Bennett JE. A subcutaneous reservoir for intrathecal therapy of fungal meningitis. *N Engl J Med* 1973;288(4):186–8.

16. Samadani U, Huang JH, Baranov D, et al. Intracranial hypotension after intraoperative lumbar cerebrospinal fluid drainage. *Neurosurgery* 2003;52(1):148–51.

17. Dagnev E, van Loveren HR, Tew JM Jr. Acute foramen magnum syndrome caused by an acquired Chiari malformation after lumbar drainage of cerebrospinal fluid: report of three cases. *Neurosurgery* 2002;51(3): 823–8.

18. Dardik A, Perler BA, Roseborough GS, et al. Subdural hematoma after thoraco-abdominal aortic aneurysm repair: an underreported complication of spinal fluid drainage? *J Vasc Surg* 2002;36(1):47–50.

## Nabídka pro partnery České neurologické společnosti

Česká neurologická společnost je odborná vědecká společnost, jejímž cílem je dbát o rozvoj neurologie jako významné lékařské a vědecké disciplíny v České republice a podílet se na zajištění kvalitní pregraduální i postgraduální přípravy lékařů v tomto oboru.

Česká neurologická společnost nabízí své dlouhodobé partnerství farmaceutickým firmám, výrobcům lékařské techniky a dalším potenciálním partnerům v neurologické oblasti.

### Co Vám můžeme nabídnout?

- Uveřejnění partnera na webové stránce České neurologické společnosti [www.czech-neuro.cz](http://www.czech-neuro.cz).
- Uveřejnění partnera v tiskovinách České neurologické společnosti.
- Uveřejnění partnera v elektronickém newsletteru České neurologické společnosti (čtyři vydání/rok).
- Uveřejnění článku/inzerce v elektronickém newsletteru České neurologické společnosti.

Máte-li zájem spolupracovat s Českou neurologickou společností, kontaktujte náš sekretariát na e-mailu [sekretariat@czech-neuro.cz](mailto:sekretariat@czech-neuro.cz). Případně nás neváhejte kontaktovat pro individuální nabídku.