

# Leiomyoma of the palm

## Leiomyom dlaně

Dear Editor,

Leiomyoma, also known as fibroids, is a benign neoplasm, which can develop anywhere in the body where smooth muscle is present. It is especially present in the uterus of middle-aged women. Occurrences in other locations are less frequent. According to histology, three types of leiomyoma – solid, cavernous and venous – are distinguished. The tumours are benign, but the leiomyosarcoma must be differentiated by histology. If the tumour occurs on the extremities, it is more likely situated in the lower extremities [1]. The localization in the palm is quite rare [2] although there were several cases of leiomyoma of the fingers [3–4]. The first leiomyoma in the palm was described in 1960 and by 2009 about 150 cases of the tumour in the hand region were described [2].

We present a case of a 55-year-old female patient who due to the wrong diagnosis and insufficient examination had to suffer for several decades. From 1981 till 2016 the patient experienced a lump in the first interdigital space and second metacarpal bone. Apart from the symptoms characteristic of carpal tunnel syndrome, she suffered from severe pain, yet no imaging studies were performed to eliminate the possibility of a tumour of the hand. The patient underwent repeated surgical interventions (1982, 1989, 1998, and 2006) at different facilities due to carpal tunnel syndrome. There were some improvements at the beginning, but overall they were effective. In January 2016, this patient was examined again. The examination showed a clear palpable mass in the region of the first interdigital space and the second metacarpal bone. Magnetic resonance imaging (MRI) was completed, showing spherical expansion without a direct relation to the branches of the median nerve in the region between the second and third metacarpal bone (Fig. 1A).

The patient expressed severe hypoaesthesia of the first three fingers, weakened hand-grip muscle power and restricted opposition of the thumb. According to EMG, the

reduced amplitude of the motor response of the median nerve, normal distal motor latency and slightly decreased amplitudes of sensory responses in the first and second fingers, and decreased sensory conduction velocity were shown. On January 11, 2016, microscopic surgery under general anaesthesia was performed. The incision was made through the previous scar through the centre of the palm and farther peripherally over the second metacarpal bone. First, the main trunk of the median nerve from the hardened scar was dissected, as well as the severely altered motor branch of the thenar. Furthermore, the periphery of the spherical mass reaching the first interdigital space in the depth of the palm was dissected. From the capsule of the mass, the thin neural branch was relaxed and the tumour was extirpated in one piece (Fig. 1B).

The tumour was well circumscribed and did not infiltrate the surrounding tissue. The tumour was thought to be a schwannoma due to its appearance and relation to the neural branch. According to the definitive histological examination, however, the surprising diagnosis of a leiomyoma was established (Fig. 2).

The sutures were removed on the eleventh postoperative day. The wound was healed. The previous pain ceased completely. The patient expressed an improvement in the sensation of the fingers except for the residual hypoaesthesia of the third finger. The mobility of the fingers was not limited.

This case report is striking since the findings reveal careless management of the whole case. Firstly, it is likely that nobody listened to the patient sufficiently during the previous surgical operations and this led to repeated surgical interventions and prolongation of the pain for an unbearably protracted period of 35 years. Therefore, imaging studies such as ultrasonography or MRI should be conducted as a routine examination, especially in the cases of revision surgery [5]. Carpal tunnel syndrome surgery brings very good results in general [6]. If

The authors declare they have no potential conflicts of interest concerning drugs, products, or services used in the study.

Autoři deklarují, že v souvislosti s předmětem studie nemají žádné komerční zájmy.

The Editorial Board declares that the manuscript met the ICMJE “uniform requirements” for biomedical papers.

Redakční rada potvrzuje, že rukopis práce splnil ICMJE kritéria pro publikace zasílané do biomedicínských časopisů.

**M. Kanta<sup>1</sup>, E. Ehler<sup>2</sup>, M. Vališ<sup>3</sup>,  
P. Kašparová<sup>4</sup>, J. Adamkov<sup>1</sup>,  
B. Klímová<sup>3</sup>**

<sup>1</sup>Department of Neurosurgery of the Faculty of Medicine of Charles University and University Hospital in Hradec Králové

<sup>2</sup>Department of Neurology, Regional Hospital Pardubice and Faculty of Health Studies, University of Pardubice

<sup>3</sup>Department of Neurology of the Faculty of Medicine of Charles University and University Hospital in Hradec Králové

<sup>4</sup>Department of Pathology of the Faculty of Medicine of Charles University and University Hospital in Hradec Králové



**doc. PhDr. Blanka Klímová, Ph.D.**  
Department of Neurology, University Hospital in Hradec Králové,  
Sokolská 581  
50005 Hradec Králové  
Czech Republic  
e-mail: blanka.klimova@fnhk.cz

Accepted for review: 16. 11. 2017

Accepted for print: 19. 12. 2017

This work was supported by the grants of MH CR – DRO (UHHK 00179906) and PROGRES Q40 run at the Faculty of Medicine of Charles University.

difficulties reoccur, it is necessary to discover whether they are primarily of neurological origin or induced by a different level (cervical spine, supraclavicular or infraclavicular brachial plexus, the course of the me-

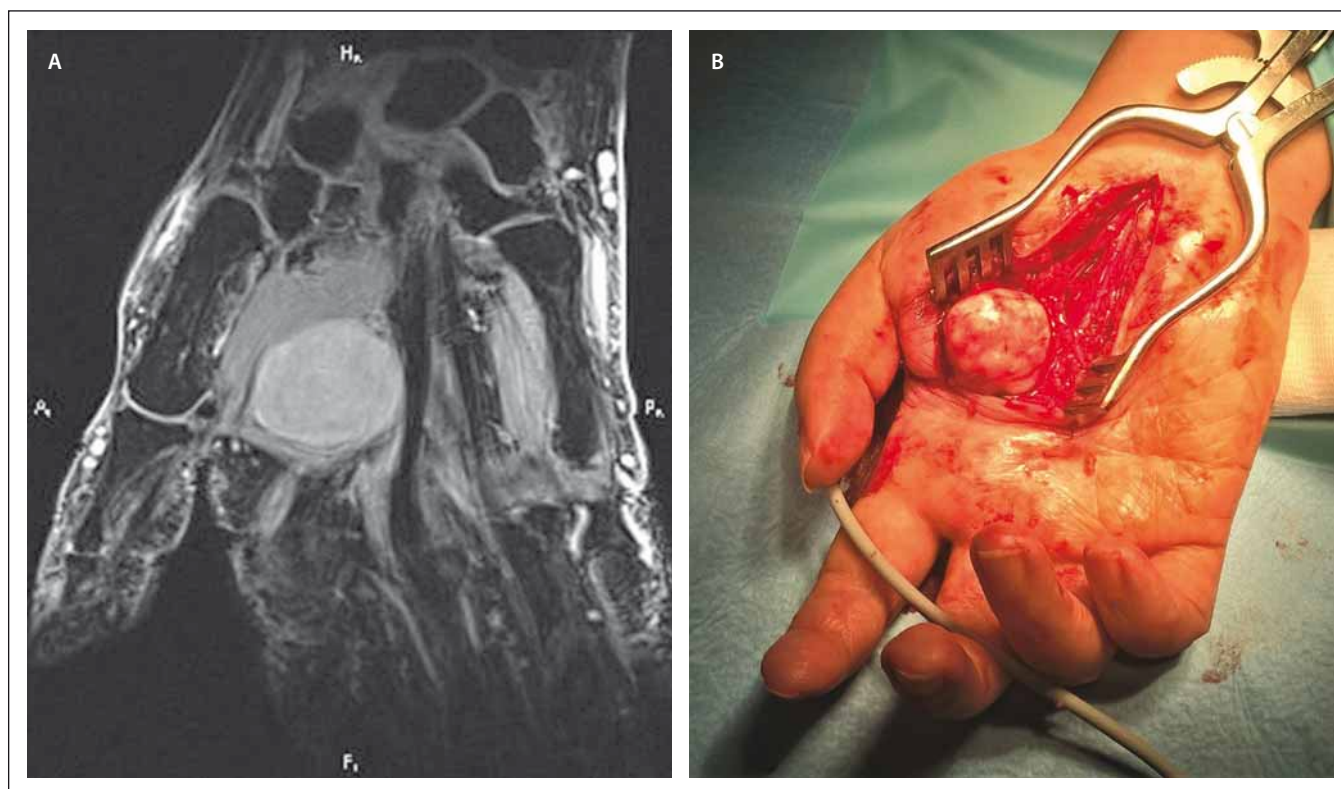


Fig. 1A) MRI of the palm with the tumour. Fig. 1B) Surgical finding.

Obr. 1A) Magnetická rezonance dlaně s nádorem. Obr. 1B) Chirurgický náález.

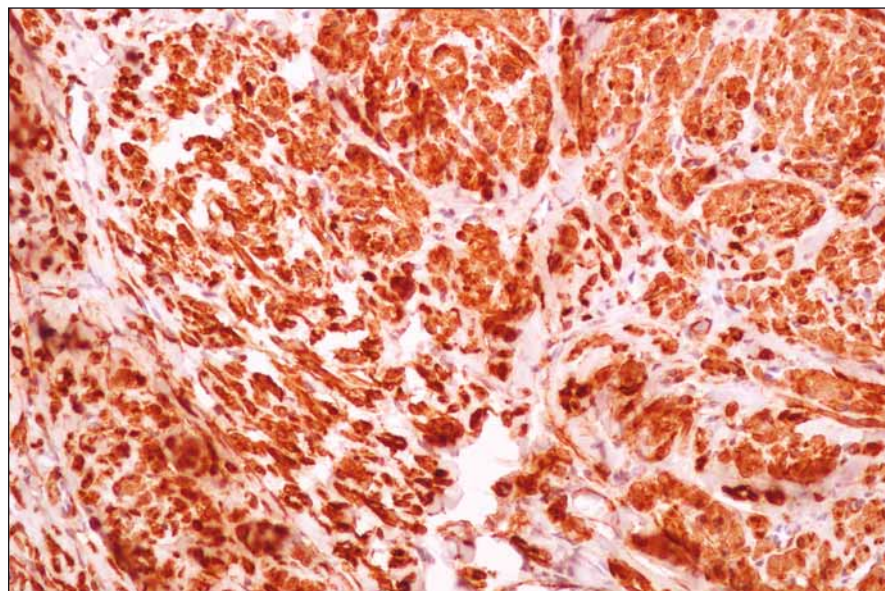


Fig. 2. Histological finding with SMA (Smooth Muscle Actin) – evidence of leiomyoma.

Obr. 2. Histologický náález s aktinem hladkého svalstva – průkaz leiomyomu.

dian nerve within the arm and the forearm). In this case, the symptoms were based further peripherally from the carpal tunnel and the tumour was not directly related to the larger branches of the nerve. Nevertheless, the scarring of the nerve surely contributed

to the problems of the patient as she has expressed improvement in sensory functions following surgery. The combination of the neural lesion and another pathology may cause confusion. Secondly, the long duration of the painful symptoms for 35 years is

quite uncommon, although there is a case of more than fifty years of growth of a tumour in the palm, but without any pain [7].

Therefore, the precise recording of the patient's medical history, the necessity of a thorough analysis of the symptoms of the patient, and a careful physical examination with subsequent targeted imaging are inevitable in order to maintain the patient's quality of life.

## References

1. Maresca A, Gagliano C, Marcuzzi A. Leiomyoma of the hand: a case report. *Chir Main* 2005; 24(3–4): 193–195.
2. Kulkarni AR, Haase SC, Chung KC. Leiomyoma of the hand. *Hand (N Y)* 2009; 4(2): 145–149. doi: 10.1007/s11552-008-9143-x.
3. Boutayeb F, Ibrahim AE, Chraïbi F et al. Leiomyoma in an index finger: report of case and review of literature. *Hand (N Y)* 2008; 3(3): 210–211.
4. Yang WE, Hsueh S, Chen CH et al. Leiomyoma of the hand mimicking a pearl ganglion. *Chang Gung Med J* 2004; 27(2): 134–137.
5. Fazilleau F, Williams T, Richou J et al. Median nerve compression in carpal tunnel caused by a giant lipoma. *Case Rep Orthop* 2014; 2014: 654934. doi: 10.1155/2014/654934.
6. Staal A, van Gijn F, Spaans F. *Mononeuropathies: examination, diagnosis and treatment*. London: WB Saunders, 1999.
7. Moritomo H, Murase T, Ebara R et al. Massive vascular leiomyoma of the hand. *Scand J Plast Reconstr Hand Surg* 2003; 37(2): 125–127.