

# Iron deficiency anemia showing progressive retinal, cochlear and cerebral thrombosis

Anémie z nedostatku železa vykazující progresivní retinální, kochleární a cerebrální trombózu

Dear editor,

Iron deficiency anemia (IDA) can cause various thrombotic conditions, such as retinal vessel occlusion, cerebral thrombosis, peripheral vascular thrombosis, hearing loss and pulmonary embolism, and some of these complications may be life-threatening [1,2]. However, the exact pathogenic mechanism of IDA-associated thrombosis is unclear; it may be hypercoagulability related to iron deficiency [1,3]. The previously reported cases of IDA-related thrombotic complications showed non-progressive course and affected single organ vessels [1–4]. We report a case of a 70-year-old woman with IDA-associated, progressive retinal, cochlear and cerebral thrombosis. To the best of our knowledge, no such case has been described previously.

A 70-year-old woman presented with sudden vertigo, hearing loss and gait disturbance for two days. One month earlier, she had visited an ophthalmologic clinic due to blurred vision and was diagnosed as central retinal vessel occlusion (CRVO) with hemorrhagic leakage in both eyes. She denied any history of diabetes, heart disease, stroke, or cigarette smoking except for arterial hypertension. Family history was negative for neurological or hematological diseases. Her blood pressure was 135/80 mm Hg, heart rate 85/min, respiratory rate 19/min, and body temperature 36 °C. Her physical examination was unremarkable except for pale conjunctivae. On neurological examination, she showed finger-counting visual acuity in both eyes, sensory neural hearing loss (SNHL) in both ears, gait ataxia, right sided dysmetria, and falling tendency. Upon fundoscopic examination on admission, the optic nerve head appeared swollen and hyperemic with hemorrhages in the right eye and scattered intraretinal hemorrhages along the vessels in both

eyes (Fig. 1A). The pure tone audiometry on admission revealed SNHL in both ears (Fig. 1B).

Laboratory examinations revealed IDA without reactive thrombocytosis: hemoglobin 6.6 gm/dL; hematocrit 20%; mean corpuscular volume (MCV) 79.4 fL; mean corpuscular hemoglobin concentration (MCHC) 26.0 pg; serum iron 19 µg/dL; total iron binding capacity 505 µg/dL; unsaturated iron binding capacity 486 mg/dL; serum ferritin 10.0 ng/mL; and platelets 385,000/µL. A blood smear review showed hypochromic microcytosis with Rouleaux formation. No data indicated the presence of significant inflammation, including white blood cell count (6,900/mm<sup>3</sup>) and C-reactive protein (0.10 mg/dL). Other laboratory tests were unremarkable, including fibrinogen (503 mg/dL), D-dimer (511.67 ng/mL), prothrombin time (PT 13.5 s), activated partial thromboplastin time (aPTT 39 s), C3, C4, lupus anticoagulant, anticardiolipin antibody, anti-neutrophil cytoplasmic antibody, antinuclear antibody, antithrombin III, antiplatelet antibody, protein C activity, and protein S activity. We performed endoscopic examinations for the stomach and large intestine, which were negative for malignancy. The brain MRI showed subtle increased hyperintensities in the left pons and right cerebellar hemisphere (Fig. 2).

During the admission period, her visual blurring and hearing difficulties showed progressive course. The follow-up fundoscopic examination (Fig. 1C) performed after 7 days showed more severe optic disc swelling and vascular tortuosity with dilatation, flame-shaped retinal hemorrhage around the optic disc and macular edema. Pure tone audiometry (Fig. 1D) performed after 7 days showed aggravated SNHL respectively.

The Editorial Board declares that the manuscript met the ICMJE "uniform requirements" for biomedical papers.

Redakční rada potvrzuje, že rukopis práce splnil ICMJE kritéria pro publikace zasílané do biomedicínských časopisů.

**B. D. Ku<sup>1</sup>, H. Y. Shin<sup>2</sup>**

<sup>1</sup> Department of Neurology, International St. Mary's Hospital, Catholic Kwandong University College of Medicine, Incheon, South Korea

<sup>2</sup> Department of Rheumatology, Shin Ill Medical Clinic, Seoul, South Korea



**Bon D. Ku, MD**  
Department of Neurology  
International St. Mary's Hospital  
College of Medicine  
Catholic Kwandong University  
25, Simgok-ro 100beon-gil  
Seo-gu, Incheon 22711  
South Korea  
e-mail: bondku34@cku.ac.kr

Accepted for review: 23. 8. 2021

Accepted for print: 20. 1. 2022

To prevent thrombosis progression, we treated the patient with ferrous sulfate and heparin, with the risk of hemorrhagic leakage of retinal vessels. After anticoagulation, her visual, auditory and neurological symptoms did not progress. A follow-up complete blood count performed one month later showed the anemia partially improved: hemoglobin 8.8 gm/dL; hematocrit 32%; MCV 85 fL; MCHC 23.7 pg; and platelets 329,000/mm<sup>3</sup>. As the anemia improved, the visual, auditory and neurological symptoms of the patient gradually improved.

The diagnostic criteria of CRVO are thrombotic occlusion of the central retinal vein

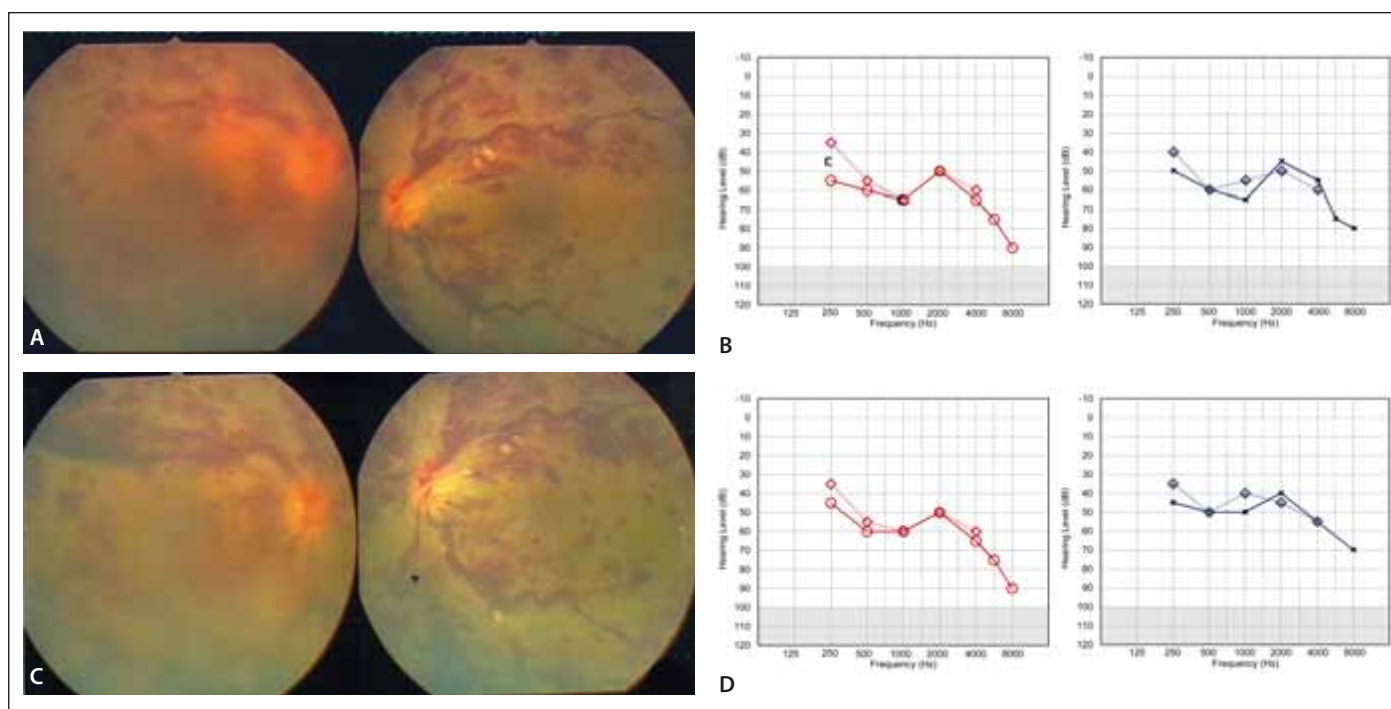


Fig. 1. (A) The initial fundoscopic examination performed on admission showed bilateral hyperemic disk edema with a cotton-wool spot along the inferior vascular arcade and scattered dot-blot hemorrhages temporal to the macula. (B) The PTA performed on admission showed sensory neural hearing loss in both ears. (C) Follow-up fundoscopic examination after seven days showed more severe optic disc swelling and vascular tortuosity with dilatation, flame-shaped retinal hemorrhage around the optic disc and macular edema. (D) The follow-up PTA after seven days showed aggravated sensory neural hearing loss in both ears.

PTA – pure tone audiogram

Obr. 1. (A) Výchozí fundoskopické vyšetření provedené při příjmu ukázalo oboustranný hyperemický edém optického disku s měkkým exudátem typu „cotton-wool spot“ podél spodní cévní arkády a rozsev tečkovitých a skvrnitých hemoragií temporálně od makuly. (B) PTA provedený při příjmu ukázal senzoreineurální ztrátu sluchu v obou uších. (C) Následné fundoskopické vyšetření po 7 dnech ukázalo závažnější otok optického disku a tortuozitu cév s dilatací, plaménkovou hemoragií sítnice okolo optického disku a edém makuly. (D) Následný PTA po 7 dnech ukázal zhoršení senzoreineurální ztráty sluchu v obou uších.

PTA – tónový audiogram

at the level of, or posterior to, the lamina cribrosa. The fundoscopic findings of the present case are compatible with bilateral CRVO. The possible mechanisms by which IDA could cause thrombosis are reactive thrombocytosis (e.g., increased platelet count and activity); hypoxia from anemia leading to injury of endothelial cells in the retino-choroidal circulation; and dysregulation of coagulation [5]. Among these mechanisms, researchers regard reactive thrombosis as a contributing factor and not a main factor [3]. Thrombus formation requires abnormal platelet activation and aggregation to the endothelial surface rather than an absolute platelet count [1,6,7]. The present case and one-third of previously-reported cases did not show increased platelet counts [3,4]. Anemic hypoxia causes diminished autoregulatory dilatation of the vessels, which leads to increased flow velocity, especially in the arteries, potentially causing

platelets to come into more frequent contact with the vessel's endothelial lining [1,3]. However, anemic hypoxia may also contribute directly, because it could predominantly affect the area that the terminal arteries supply; most cases of IDA-associated thrombosis occur in cerebral or retinal veins [1]. Anemic hypercoagulability and hemodynamic changes may be the main causes of IDA-associated thrombosis [1,6]. The normal PT, aPTT, fibrinogen, and D-dimer levels in the present case suggested that regulation of the coagulation-fibrinolysis system was unimpaired. Microcytosis in IDA reduces deformability and increases viscosity of red blood cells [1,7]. These factors contribute to reduced flow velocity and to red blood cell stasis in the veins making platelets come into more frequent contact with the vessel's endothelial lining [6,7]. This stasis frequently occurs in a negative-pressure environment, such as retinochoroidal circulation [1,3]

The optimal treatment for patients with IDA-associated progressive thrombosis with retinal hemorrhage is unknown. Iron supplementation is essential, but administration of anticoagulants is controversial, because the hemorrhagic leakage of retinal vessels leads to blindness [7]. Chung SD et al demonstrated the association between SNHL and IDA [8]. Vascular events such as thrombosis, embolus, reduced blood flow, or vasospasms may lead to vascular compromise of the cochlea. These findings suggest underlying IDA should be considered in patients with SNHL and that more aggressive management of patients with IDA should be undertaken. Recent studies confirmed the safety of anticoagulant use, even in patients with hemorrhagic parenchymal lesions [9,10].

In the present case, the clinical course of the thrombosis was progressive, and administration of the anticoagulant agent did not

aggravate the retinal hemorrhage. We are concerned about the possibility of generalizing, but physicians still should consider iron supplementation with an anticoagulant for a patient with IDA-associated progressive thrombosis with retinal hemorrhage.

### Declaration of patient consent

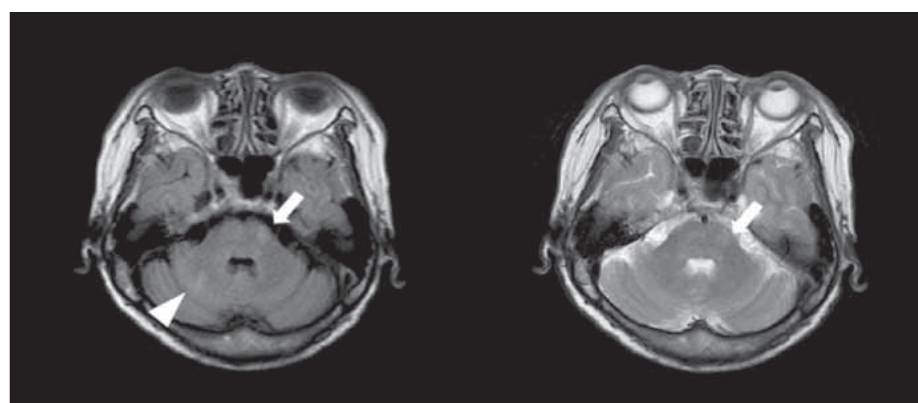
The authors certify that they have obtained all of the appropriate patient consent forms. In the form, the patient has given her consent for her images and other clinical information to be reported in the journal. The patient understands that her name and initials will not be published and due efforts will be made to conceal her identity, but anonymity cannot be guaranteed.

### Acknowledgement

The authors would like to thank Harrisco (www.harrisco.net) for the English language review.

### References

1. Yadav D, Chandra J. Iron deficiency: beyond anemia. *Indian J Pediatr* 2011; 78(1): 65–72. doi: 10.1007/s12098-010-0129-7.
2. Eliaçık S, Uysal Tan F. Iron deficiency anaemia in cerebral venous sinus thrombosis – cause or association? *Cesk Slov Neurol N* 2021; 117(2): 208–210. doi: 10.48095/cccsnn2021208.
3. Belman AL, Roque CT, Ancona R et al. Cerebral venous thrombosis in a child with iron deficiency anemia and thrombocytosis. *Stroke* 1990; 21(3): 488–493. doi: 10.1161/01.str.21.3.488.
4. Akins PT, Glenn S, Nemeth PM et al. Carotid artery thrombus associated with severe iron-deficiency anemia and thrombocytosis. *Stroke* 1996; 27(5): 1002–1005. doi: 10.1161/01.str.27.5.1002.



**Fig. 2. Brain MRI. Subtle hyperintensities in the left pons (arrow) and right cerebellar hemisphere (arrow head) in the FLAIR (left) and T2-weighted image (right), respectively.**

Obr. 2. MR mozku. Drobné hyperintenzity v levé části Varolova mostu (šipka) a v pravé hemisféře mozečku (hrot šipky) v sekvenci FLAIR (vlevo) a na T2-váženém snímku (vpravo).

5. Yang V, Turner LD, Imrie F. Central retinal vein occlusion secondary to severe iron-deficiency anaemia resulting from a plant-based diet and menorrhagia: a case presentation. *BMC Ophthalmol*. 2020; 19; 20(1): 112. doi: 10.1186/s12886-020-01372-6.
6. Kim JS, Kang SY. Bleeding and subsequent anemia: a precipitant for cerebral infarction. *Eur Neurol* 2000; 43(4): 201–208. doi: 10.1159/000008176.
7. Lewis H, Sloan SH, Foos RY. Massive intraocular hemorrhage associated with anticoagulation and age-related macular degeneration. *Graefes Arch Clin Exp Ophthalmol* 1988; 226(1): 59–64. doi: 10.1007/BF02172720.

8. Kuramatsu JB, Sembill JA, Gerner ST et al. Management of therapeutic anticoagulation in patients with intracerebral haemorrhage and mechanical heart valves. *Eur Heart J* 2018; 39(19): 1709–1723. doi: 10.1093/eurheartj/ehy056.
9. Chung SD, Chen PY, Lin HC et al. Sudden sensorineural hearing loss associated with iron-deficiency anemia: a population-based study. *JAMA Otolaryngol Head Neck Surg* 2014; 140(5): 417–422. doi: 10.1001/jamaoto.2014.75.
10. Nashashibi J, Avraham GR, Schwartz N et al. Intravenous iron treatment reduces coagulability in patients with iron deficiency anaemia: a longitudinal study. *Br J Haematol* 2019; 185: 93–101.