

Primary intraorbital hydatid cyst in a young Sudanese female

Primární intraorbitální hydatidová cysta u mladé súdánské ženy

Dear Editor,

Herein, we report a rare case of an intraorbital hydatid cyst in a 24-year-old female residing in a rural area with a low socioeconomic status. She presented to the eye clinic with complains of exophthalmos (lasting for 4 months), visual impairment, and embarrassment from cosmetic disfigurement in the right eye. Patient was referred to the neurosurgery clinic. Clinical examination of the right eye revealed no pain or sensitivity, moderate proptosis, and double vision in the upward gaze. Patient's visual acuity was 8/10 in the right eye and 10/10 in the left eye. Fundoscopic examination revealed a mild, pale, and atrophic optic disc in the right eye, and a normal left eye. Systemic examination did not reveal any other abnormalities. Cranial CT revealed a cystic lesion pushing the optic nerve downward and the eyeball inferolaterally (Fig. 1 A–C). There was a lack of MRI devices at our hospital and the surrounding hospitals, with the nearest MRI device located 1,300 km away in the capital city of Khartoum. Thus, an MRI could not be obtained. Laboratory tests yielded normal results, and no hydatid cysts were detected on the patient's chest and abdominal CT.

Patient was positioned supine on the operating table, with head fixed in a skull clamp, which was supported by the right shoulder, and turned approximately 30° to the left. Patient underwent a right fronto-temporo-orbitozygomatic craniotomy and orbitotomy. A unilocular cyst was identified in superomedial aspect of the orbital cavity. Aspiration of the cyst with a 22G needle revealed a clear fluid. Hypertonic saline solution was gently injected into the cavity and re-aspirated. The cyst had a thick fibrous wall and was dissected from the surrounding tissues. The cyst was completely removed. The surgical site was washed with hypertonic saline solution for 5 min. After hemostasis was achieved, the bone was replaced, and the wound was sutured. No additional neuro-

logical deficits developed after surgery. Histopathological examination of the excised cyst revealed an eosinophilic acellular cuticle and a protoscolex, which were consistent with *Echinococcus granulosus*. Therefore, the patient was administered oral albendazole (15 mg/kg/day) for 3 months and prednisolone (1 mg/kg). The postoperative period was uneventful, and the patient was discharged on the fifth postoperative day. The right eye proptosis had completely resolved 2 weeks after surgery (Fig. 1D–F). After the albendazole course was completed, the patient visited the outpatient clinic for a follow-up. Physical examination did not reveal any additional findings or recurrence. At the 1-year follow-up, no additional pathology was detected.

Hydatid disease is a global health concern which is endemic to Africa, the Middle East, Eastern Europe, Australia, and Mediterranean countries [1,2]. The disease is caused by *Echinococcus*, and it can manifest in the following forms: cystic form caused by *E. granulosus*, alveolar form caused by *E. multilocularis*, and polycystic form caused by *E. vogeli* or *E. oligarthrus* [3]. *Echinococcosis* has a wide range of clinical manifestations and severity from asymptomatic to fatal disease [4]. In hydatid cysts, symptoms generally occur due to the pressure effect on the surrounding tissues or cyst rupture. Furthermore, symptoms depend on the size and location of the affected organ. Most common cause of an orbital hydatid cyst is *E. granulosus* [5]. Definitive host of *E. granulosus* is a dog and the adult worm lives in the proximal portion of the small intestine of its host. Eggs are released into the environment via dog feces and are ingested by intermediate hosts such as sheep and cows. The cycle is completed when the definitive host consumes the internal organs of the intermediate host. Humans are accidental hosts who develop echinococcosis by consuming contaminated vegetables. Hydatid cysts commonly develop in

The Editorial Board declares that the manuscript met the ICMJE "uniform requirements" for biomedical papers.

Redakční rada potvrzuje, že rukopis práce splnil ICMJE kritéria pro publikace zasílané do biomedicínských časopisů.

O. Boyali

Department of Neurosurgery,
Nyala Sudan-Turkish Training
and Research Hospital
Istanbul, Turkey



Osman Boyali, MD
Department of Neurosurgery
University of Health Sciences
Gaziosmanpasa
Training and Research Hospital
Karayollari, Osmanbey Cd. 621 Sokak
34255 Gaziosmanpasa/Istanbul
Istanbul
Turkey
e-mail: drosmansboyali@gmail.com

Accepted for review: 9. 12. 2023
Accepted for print: 23. 10. 2024

the liver and lungs (> 90%). The disease can also affect the mesentery, spleen, bronchi, parotid gland, uterus, tibia, and feet [5,6].

Orbital hydatid cyst is rare (1%) [2,5] and can be observed in any age group. Clinical manifestation of an orbital hydatid cyst is painless exophthalmos without any pulsations (Tab. 1) [7–10]. Degree and direction of proptosis depends on cyst's location. Other findings may include eyelid edema, visual disturbance, and restriction of extraocular movements. In our patient, painless exophthalmos and mild visual impairment were observed, without eyelid edema or restricted eye movements. Hydatid cysts can occur in different locations within the orbit. However, it is commonly lo-

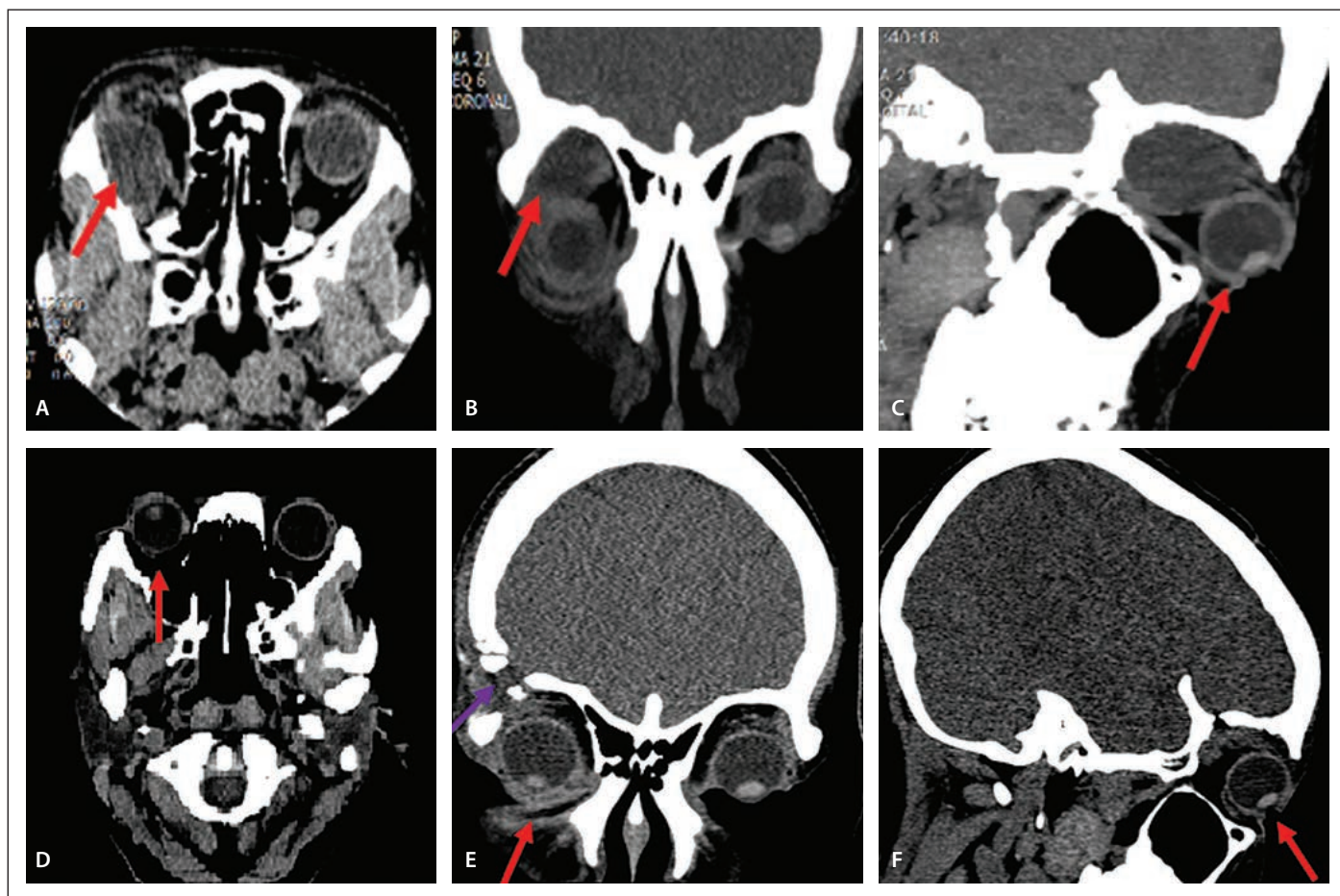


Fig. 1. Pre-op optic nerve pushed by the cyst downward and the eyeball inferolaterally in axial (A) and coronal (B) CT scan. (C) Pre-op proptosis in sagittal CT scan. (D) Post-op proptosis resolved in axial CT scan. (E) Post-op proptosis resolved in coronal CT scan, fronto-temporo-orbitozygomatic craniotomy. (F) Post-op proptosis resolved in sagittal CT scan.

Obr. 1. Před operací optický nerv zatlačený cystou směrem dolů a globus inferolaterálně zatlačený cystou na axiálním (A) a koronálním (B) snímku CT. (C) Proptóza před operací na sagitálním snímku CT. (D) Pooperační vyřešená proptóza na axiálním snímku CT. (E) Pooperačně vyřešená proptóza na koronálním snímku CT, frontotemporo-orbitozygomatická kraniotomie. (F) Pooperačně vyřešená proptóza na sagitálním snímku CT.

Tab. 1. Orbital hydatid cysts in the literature.

Local area	Localization of cyst	Symptoms	Treatment
Chtira K et al. (Morocco) [7]	extraconal right orbital lesion near the orbital apex	unilateral proptosis and blindness	cyst removed and albendazole at a dose of 10 mg/kg/day for 2 weeks
Fasina O et al. (Nigeria) [8]	retrobulbar	unilateral gradual protrusion blindness	cyst removed
Belaaroussi S et al. (Morocco) [9]	intraconic	unilateral exophthalmia	cyst removed
Irey G et al. (Turkey) [10]	retrobulbar	unilateral proptosis	cyst removed and albendazole at a dose of 10 mg/kg/day for 12 weeks

cated superomedial or superolateral to the eyeball [8,10].

When a hydatid cyst is suspected, CT or MRI can help confirm the diagnosis. MRI is the preferred imaging modality for diagnosing orbital hydatid cysts. On MRI, a hydatid cyst appears as a thin-walled, usually unilocular,

well-defined, fluid-filled cyst. When a cystic structure is detected in the orbit, the differential diagnoses should include hydatid cyst, orbital abscess, epidermoid cyst, mucocele, hematoma, lymphangioma, and teratoma. Although preoperative imaging may suggest the presence of a hydatid cyst, the

disease is usually confirmed by direct visualization of the typical protoscolices or *E. granulosus* hooks in cyst aspirates or histological examination of biopsied tissue samples [5]. Although MRI imaging was not performed in our patient, the CT findings were consistent with those described in the literature.

Definitive treatment for an orbital hydatid cyst is total surgical excision. Most common complication is rupture of the cyst and spill-age of the contents, which can lead to anaphylaxis and secondary local recurrences [8]. When cysts rupture, complete fluid aspiration and irrigation with hypertonic saline or hydrogen peroxide must be done.

There are no definitive guidelines for the treatment (Tab. 1) [7–10]. Although surgical intervention is standard treatment for hydatid cysts, adjuvant medical therapy is crucial to reduce recurrence rates and cyst size. Treatment of hydatid disease is reportedly more effective when albendazole is administered alone or in combination with praziquantel 2–4 weeks before surgery [7]. However, our patient was diagnosed during surgery. Thus, medical therapy was initiated after surgery, with albendazole being prescribed for 3 months.

Housekeeping training is the primary method of preventing *Echinococcus* infections. Preventing contact with dog and fox feces, ensuring compliance with hand washing and hygiene rules, and breaking the biological life cycle of the parasite are other methods for controlling the disease. Vaccinating dogs that live with humans and maintaining their hygiene are crucial. Additionally, stray dogs must be controlled. Finally, slaughterhouses should be improved, and animal slaughter should be controlled.

Conflict of interest

The authors declare they have no potential conflicts of interest concerning drugs, products, or services used in the study.

References

1. Bektas S, Erdogan NY, Sahin G et al. Clinicopathological findings of hydatid cyst disease: a retrospective analysis. *Ann Clin Pathol* 2016; 4(3): 1071. doi: 10.47739/2373-9282/1071.

2. Benazzou S, Arkha Y, Derraz S et al. Orbital hydatid cyst: review of 10 cases. *J Craniomaxillofac Surg* 2010; 38(4): 274–278. doi: 10.1016/j.jcms.2009.10.001.
3. Craing PS, Macmanus D, Lightowlers MW et al. Prevention and control of cystic echinococcosis. *Lancet Infect Dis* 2007; 7(6): 385–394. doi: 10.1016/S1473-3099(07)70134-2.
4. Eckert J, Deplazes P. Biological, epidemiological, and clinical aspects of echinococcosis, a zoonosis of increasing concern. *Clin Microbiol Rev* 2004; 17(1): 107–135. doi: 10.1128/CMR.17.1.107-135.2004.
5. Xiao A, Xueyi C. Hydatid cysts of the orbit in Xinjiang: a review of 18 cases. *Orbit* 1999; 18(3): 151–155. doi: 10.1076/orbi.18.3.151.2705.
6. Moro P, Schantz PM. Echinococcosis: a review. *Int J Infect Dis* 2009; 13(2): 125–133. doi: 10.1016/j.ijid.2008.03.037.
7. Chтира K, Benantar L, Aitlhaj H et al. The surgery of intra-orbital hydatid cyst: a case report and literature review. *Pan Afr Med J* 2019; 33: 167. doi: 10.11604/pamj.2019.33.167.18277.
8. Fasina O, Ogun OG. Hydatid cyst of the orbit in a young Nigerian female: a case report. *Ghana Med J* 2017; 51(4): 204–206.
9. Belaaroussi S, Housni K, Baqadir C et al. Clinical case: orbital hydatid cyst revealed by exophthalmia. *ASOP* 2020; 3(12): 5–7.
10. Irey G, Mayali H, Baser EF et al. "Orbital Kist Hidatik" Türkiye Klinikleri. *J Ophthalmol* 2015; 24(1): 41–45.

ONEMOCNĚNÍ TYPICKY SE PROJEVUJÍCÍ ZÁNĚTEM ZRAKOVÝCH NERVŮ A MÍCHY

Monografie přináší přehled základních patogenetických mechanismů u NMOSD a MOGAD, osvětluje diferenciálnědiagnostické postupy, předkládá typické nálezy při zobrazení magnetickou rezonancí a optickou koherenční tomografií u optických neuritid. Shrnuje možnosti terapie relapsů a dlouhodobou chronickou léčbu nemocných s těmito autoimunitními onemocněními CNS.



Shrnuje možnosti terapie relapsů

Kupujte na **grada.cz**



Nakladatelský dům
GRADA