

Ventriculo-atrial shunt in the treatment of idiopathic intracranial hypertension in pregnancy

Ventrikulo-atriální shunt v terapii idiopatické intrakraniální hypertenze v těhotenství

Dear Editor,

We present the case of a 27-year-old woman who was consulted at our outpatient clinic due to visual obscurations that lasted for two months. Symptoms started as white dots appearing at the bitemporal sides of visual fields that later merged into a continuous mass that caused difficulties with everyday activities. The patient was in her 13th week of gestation. History included migraines, interestingly worsening in the horizontal position. Typical prodromes included nausea and vomitus with occasional occurrence of psychogenic generalized epileptic-like seizures (without any epileptogenic activity of the brain on repeated EEGs). Past medical therapy for migraines proved to be ineffective.

A neurologic exam did not show any significant findings. An ophthalmologic evaluation revealed bilateral severe papilledema with multiple scotomas predominantly in the nasal half of the perimeter. Therefore, a clinical suspicion of idiopathic intracranial hypertension (IIH) was raised. MRI and MR venography showed no apparent pathology or thrombosis of dural sinuses but only subtle radiological signs of chronic rise of intracranial pressure (ICP) (Fig. 1). The next diagnostic step was to perform a lumbar puncture (LP) in the lateral decubitus position. The opening pressure reached 650 mm of the water column. Diagnosis of IIH was established.

The patient underwent a set of repeated relieving LPs with unsatisfactory results.

With previous impairment of visual fields and ineffectiveness of conservative treatment, indication for surgical management was raised.

We briefly admitted the patient to our department. We chose permanent ventriculo-atrial (VA) diversion (explained below). The

position of the atrial catheter was checked using transthoracic echocardiography intraoperatively. We implanted an adjustable valve Medtronic Strata II (Dublin, Ireland), which was initially set at position 2.0 corresponding to 110 mm of the water column. Ventricular catheter was introduced using stereotactic navigation [1]. After a few days, we performed postoperative MRI of the brain with satisfactory findings. The patient was dismissed 6 days after the procedure. After 1 month, the patient was subjectively satisfied with the surgery results. However, ophthalmologic evaluation revealed progression of papilledema, and the perimeter was only slightly improved since the last evaluation. Therefore, we adjusted the valve to position 1.5 with the next appointment scheduled in 1 month. At the next visit, the patient complained about tinnitus. Initially, we ruled out peripheral origin of the symptom. Additionally, the fundoscopic exam confirmed stationary edema, therefore we decided to perform an echocardiographically guided shunt-o-gram (Fig. 2), which excluded shunt malfunction. Therefore, we lowered the opening pressure of the valve (1.0) and paraclinical findings subsided significantly. She later gave birth naturally without complications. Henceforth, she was being followed up in our outpatient clinic with minimal residual papilledema and a few stationary scotomas in the left eye.

As IIHT occurs mainly in women of child-bearing age, it is important to address this specific clinical situation.

Although there are some papers suggesting pregnancy as a risk factor for worsening or even provoking IIHT due to weight gain or hormonal changes, a controlled study performed by Digre et al. disproved these assertions. It has also shown that pregnancy does not alter the outcome of already manifested

Redakční rada potvrzuje, že rukopis práce splnil ICMJE kritéria pro publikace zasílané do biomedicínských časopisů.

The Editorial Board declares that the manuscript met the ICMJE "uniform requirements" for biomedical papers.

**M. Plevko^{1,2}, V. Vybíhal^{1,2},
P. Fadrus^{1,2}, M. Smrčka^{1,2}**

¹ Department of Neurosurgery, Faculty of Medicine, Masaryk University, Brno, Czech Republic

² Department of Neurosurgery, University Hospital Brno, Czech Republic



Václav Vybíhal, MD
Department of Neurosurgery
University Hospital Brno
Jihlavská 340/20
625 00 Brno
e-mail: vybihal.vaclav@fnbrno.cz

Accepted for review: 8. 2. 2024

Accepted for print: 23. 10. 2024

disease [2]. Pregnancy, however, does significantly affect therapeutic options for this disease.

Conservative treatment of IIHT in pregnancy is unfortunately limited. Acetazolamide, which proved to be effective in the reduction of papilledema [3], was showing some teratogenic effects in animal studies, but not in human cases. Therefore, every use in clinical practice must be thoroughly discussed with a patient about its risks [4,5]. On the other hand, topiramate for the treatment of headaches, has documented teratogenicity and should be avoided during pregnancy [6]. Body weight reduction, as the only disease-modifying therapy, might be

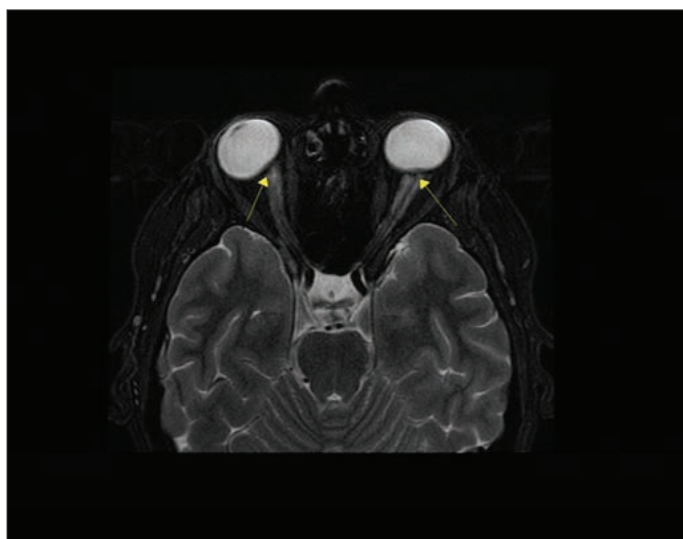


Fig. 1. Preoperative brain MRI (T2-weighted sequence, axial plane). Notice the applanation of the back side of bulbi and slightly widened sheets of optic nerves (arrows).

Obr. 1. Předoperační MR mozku (T2-vážená sekvence, axiální rovina).

Všimněte si aplanaci optických bulbů a jemné rozšíření pochev optických nervů (šipky).

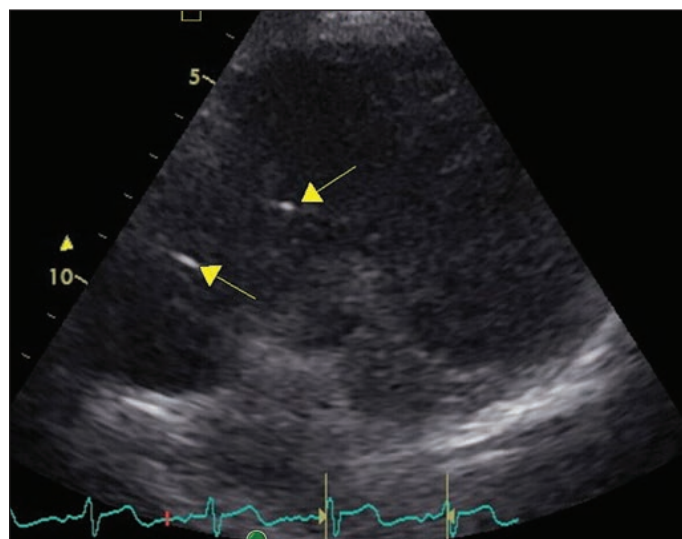


Fig. 2. Transthoracic echocardiography guided shunt-o-gram.

Notice small bubbles of highly frothy saline entering the right atrium and chamber (arrows).

Obr. 2. Transthorakální echokardiografií navigovaný shunt-o-gram.

Všimněte si malých bublinek vysoce zpěněného fyziologického roztoku, které vstupují do pravé síně a komory (šipky).

a challenging goal during pregnancy and in general, is not recommended. A bridge between surgical and conservative treatment is represented by serial lumbar punctures, whose effect is usually short-lived as you can also see from our experience [4].

CSF shunting is a well-established and effective treatment of IIHT mainly in preserving visual functions [4,7]. However, our data prove that it also provides solid results for other manifestations of disease. Although many authors propose peritoneal shunting in the early stages of gravidity as safe [8], in our opinion, VA connection provides numerous advantages over other types in this particular situation:

- Abdominal discomfort and pain are frequent complaints of patients via the peritoneal route immediately after surgery and sometimes persist for a longer time, which can be a rather challenging symptom during pregnancy.
- A precious factor in the early stages of pregnancy is the option to perform an X-ray and iodine-free shunt-o-gram to rule out possible malfunction of the implanted device.
- Another factor important in the advanced stages of pregnancy are the rather confusing anatomical orientation and pressure changes inside the peritoneal cavity. In a study performed by Staelens et al., intra-abdominal pressure measured by

Foley catheter shortly before a caesarean section ranged from 11 to 16 mm of mercury column. Such pressure would indeed impair the function of the capsule which was initially set at 110 mm of the water column and even had to be lowered in the postoperative course [9].

- The next benefit of VA shunting is preventing potential infection of the abdominal cavity with its eventual deleterious effects on the developing embryo. Not to mention caesarean section and its risks of potential catheter infection or malfunction.

An alternative to shunting is endovascular stenting of venous sinuses introduced by Higgins et al. [10]. The main drawback of this method is the need for chronic antiplatelet therapy, which may be quite hazardous in patients in their active years of life and even more during pregnancy.

According to data provided by Thaller et al. [5], there is no need to choose caesarean section as the mode of delivery unless needed from obstetric factors. Although repeated Valsava maneuvers during vaginal labor could theoretically exacerbate damage to optic nerves, these however last only for a short time.

Author contribution

All authors agree with the content of the manuscript, and all gave explicit consent after careful revision. Ma-

terial preparation, data collection, and analysis were performed by Martin Plevko and Václav Vybíhal. The first and final draft of the manuscript was written by Martin Plevko and all authors commented on previous versions of the manuscript.

Conflict of interest

All authors certify that they have no affiliations with nor involvement in any organization with any financial or nonfinancial interest in the subject matter or materials presented in the manuscript. The funder also confirms that it had no role in the design of the study; in the collection, analyses, or interpretation of data; in the writing of the manuscript; or in the decision to publish the results.

Funding

Supported by the Ministry of Health, Czech Republic – conceptual development of research organization (FNBr, 65269705).

References

1. Woodworth GF, McGirt MJ, Elfert P et al. Frameless stereotactic ventricular shunt placement for idiopathic intracranial hypertension. *Stereotact Funct Neurosurg* 2005;83(1): 12–16. doi: 10.1159/000084059.
2. Digre KB, Varner MW, Corbett JJ. Pseudotumor cerebri and pregnancy. *Neurology* 1984; 34(6): 721–729. doi: 10.1212/wnl.34.6.721.
3. NORDIC Idiopathic Intracranial Hypertension Study Group Writing Committee; Wall M, McDermott MP, Kiebertz KD et al. Effect of acetazolamide on visual function in patients with idiopathic intracranial hypertension and mild visual loss: the idiopathic intracranial hypertension treatment trial. *JAMA* 2014; 311(16): 1641–1651. doi: 10.1001/jama.2014.3312.
4. Mollan SP, Davies B, Silver NC et al. Idiopathic intracranial hypertension: consensus guidelines on management. *J Neurol Neurosurg Psychiatry* 2018; 89(10): 1088–1100. doi: 10.1136/jnnp-2017-317440.

5. Thaller M, Wakerley BR, Abbott S et al. Managing idiopathic intracranial hypertension in pregnancy: practical advice. *Pract Neurol* 2022; 22(4): 295–300. doi: 10.1136/practneurol-2021-003152.

6. Weston J, Bromley R, Jackson CF et al. Monotherapy treatment of epilepsy in pregnancy: congenital malformation outcomes in the child. *Cochrane Database Syst Rev* 2016; 11(11): CD010224. doi: 10.1002/14651858.CD010224.pub2.

7. Abubaker K, Ali Z, Raza K et al. Idiopathic intracranial hypertension: lumboperitoneal shunts versus ventriculoperitoneal shunts--case series and literature review. *Br J Neurosurg* 2011; 25(1): 94–99. doi: 10.3109/02688697.2010.544781.

8. Byth LA, Lust K, Jeffree RL et al. Management of idiopathic intracranial hypertension in pregnancy. *Obstet Med* 2022; 15(3): 160–167. doi: 10.1177/1753495X211021333.

9. Staelens AS, Van Cauwelaert S, Tomsin K et al. Intra-abdominal pressure measurements in term pregnancy and postpartum: an observational study. *PLoS One* 2014; 9(8): e104782. doi: 10.1371/journal.pone.0104782.

10. Higgins JN, Owler BK, Cousins C et al. Venous sinus stenting for refractory benign intracranial hypertension. *Lancet* 2002; 359(9302): 228–230. doi: 10.1016/S0140-6736(02)07440-8.



**OMBUDSMAN
DOSTUPNOSTI
ZDRAVOTNÍ PÉČE**

Drahá a neúčinná je jen ta intervence,
která se včas nedostane ke správnému pacientovi

Náš cíl

Cílem spolku Ombudsman zdravotní péče, z.s., je vytvoření systému spojujícího predikci potřeb zdravotní péče na národní úrovni s možnostmi medicínských technologií a jejich udržitelného financování a rozvoje.*

Připojte se svými náměty a potřebami i vy:

- na webových stránkách **www.ombudsmanzdravotnipece.cz**
- na e-mailové adrese **ombudsman@ombudsmanzdravotnipece.cz**



PharmDr. Jiří Samek,
odborný garant –
ombudsman

Činnost spolku
Ombudsman zdravotní
péče, z.s., **podporují**
zdravotní pojišťovny
České republiky.

* Ombudsman dostupnosti zdravotní péče, z.s., není primárně založen k řešení konkrétních případů neposkytnutí adekvátní zdravotní péče a dalších otázek, které jsou v kompetenci patientského ombudsmana, nemocničních ombudsmanů či obdobných institucí.