

Compressive and traumatic neuropathies of the deep branch of the radial nerve – a retrospective analysis of surgically treated cases

Kompresivní a traumatické neuropatie ramus profundus nervi radialis – retrospektivní analýza chirurgicky řešených případů

Abstract

Aim: This study aimed to evaluate the outcomes of surgical treatment for compressive and traumatic neuropathies of the deep branch of the radial nerve (DBRN), with an additional focus on epidemiology, anatomical considerations linked to DBRN lesions, and complications. **Materials and methodology:** Records of patients surgically treated for peripheral nerve lesions were retrospectively reviewed to compile data on demographic details, anatomical location of the lesion, surgical management, outcomes, and complications. The primary outcome measure was the Louisiana State University Health Sciences Center (LSUHSC) score. **Results:** Twenty-two patients, comprising of 15 compressive and 7 traumatic neuropathies, were included. The median follow-up was 17.5 (14–41) months. Surgical intervention led to a significant improvement in the LSUHSC score in both the compressive (from 2 [0–3] to 4 [2–5]; $P = 0.018$) and the traumatic neuropathy group (from 0 [0–0] to 3 [0–4]; $P = 0.011$). The traumatic neuropathy group exhibited a significantly lower preoperative LSUHSC score ($P = 0.004$), but the difference in postoperative scores was not significant ($P = 0.129$). Primary surgical treatment failed in 26.7% of patients with compression and in 28.6% of patients with DBRN injury. Tendon transfer presented a viable solution for patients with failed primary treatment. **Conclusion:** Surgical treatment provides significant functional improvement in patients with compressive and traumatic neuropathies of the DBRN. However, a considerable percentage of patients in both groups experienced primary treatment failure. Although patients with traumatic neuropathies of the DBRN presented with a worse preoperative functional status, the postoperative outcomes between both groups were comparable.

Souhrn

Cíl: Cílem této studie je zhodnocení výsledků chirurgické léčby u pacientů s kompresivními a traumatickými neuropatiemi ramus profundus nervi radialis (RPNR) společně s epidemiologií, anatomickými aspekty spojenými s lézemi RPNR a komplikacemi. **Soubor a metodika:** Záznamy chirurgicky léčených pacientů pro léze periferních nervů byly retrospektivně přezkoumány za účelem získání demografických údajů, místa léze, typu chirurgického řešení, výsledků a komplikací. K objektivizaci klinických výstupů bylo zvoleno skóre Louisiana State University Health Sciences Center (LSUHSC). **Výsledky:** Celkem bylo zahrnuto 22 pacientů, z toho 15 kompresivních a 7 traumatických neuropatií. Medián sledování byl 17,5 (14–41) měsíců. Chirurgická intervence vedla k významnému zlepšení skóre LSUHSC jak ve skupině s kompresivní (ze 2 [0–3] na 4 [2–5]; $p = 0,018$), tak ve skupině s traumatickou neuropatií (z 0 [0–0] na 3 [0–4]; $p = 0,011$). Skupina s traumatickou neuropatií vykazovala významně nižší předoperační skóre LSUHSC ($p = 0,004$), ale rozdíl v pooperačním skóre nebyl významný ($p = 0,129$). Primární chirurgická léčba selhala u 26,7 % pacientů s kompresí a u 28,6 % pacientů s poraněním RPNR. Šlachové přenosy byly posouzeny jako vhodné řešení pro pacienty se selháním primární léčby. **Závěr:** Chirurgická léčba přináší významné funkční zlepšení u pacientů s kompresivními i traumatickými neuropatiemi RPNR. U značného procenta pacientů v obou skupinách však došlo k selhání primární léčby. Přestože pacienti s traumatickými neuropatiemi RPNR vykazovali horší předoperační funkčnost končetiny, pooperační výsledky mezi oběma skupinami byly srovnatelné.

The Editorial Board declares that the manuscript met the ICMJE “uniform requirements” for biomedical papers.

Redakční rada potvrzuje, že rukopis práce splnil ICMJE kritéria pro publikace zasílané do biomedicínských časopisů.

M. Beneš^{1–3}, I. Humhej^{2–4}, H. Zítek^{2–4}, D. Kachlík^{2,3}, V. Kunc^{2,3,5}

¹ 1st Department of Orthopaedics, First Faculty of Medicine, Charles University and Motol University Hospital, Prague, Czech Republic

² Department of Anatomy, Second Faculty of Medicine, Charles University, Prague, Czech Republic

³ Center for Endoscopic, Surgical and Clinical Anatomy (CESKA), Second Faculty of Medicine, Charles University, Prague, Czech Republic

⁴ Department of Neurosurgery, Faculty of Health Studies, Jan Evangelista Purkinje University, Masaryk Hospital, Usti nad Labem, Czech Republic

⁵ Clinic of Trauma Surgery, Masaryk Hospital, Usti nad Labem, Czech Republic



Vojtěch Kunc, MD, PhD

Department of Anatomy
Second Faculty of Medicine
Charles University

Plzenska 311

150 06 Prague

Czech Republic

e-mail: vjpkunc@gmail.com

Přijato k recenzi: 20. 3. 2025

Přijato do tisku: 25. 11. 2025

Key words

deep branch of the radial nerve – posterior interosseous nerve – compression – palsy – injury – neuropathy

Klíčová slova

ramus profundus nervi radialis – nervus interosseus posterior – komprese – paréza – úraz – neuropatie

Introduction

Deep branch of the radial nerve (DBRN) is the main source of innervation to the muscles of the posterior compartment of the forearm [1]. It originates from a division of the radial nerve (C5–C7) at the level of the lateral epicondyle of the humerus, which separates into the superficial branch of the radial nerve (SBRN) and the DBRN [1]. As the DBRN courses distally, it descends over the radial head and neck before entering the supinator canal beneath the tendinous arch of the supinator muscle (arcade of Frohse) [2]. Within the supinator canal, the DBRN is positioned between the superficial and deep layers of the supinator muscle [1]. Upon exiting the supinator canal through the distal arcade, the DBRN is renamed the posterior interosseous nerve (PIN), reflecting its topographical relation to the forearm bones and antebrachial interosseous membrane [3]. Thereafter, it branches into the recurrent (medial) branch, supplying the extensor digitorum (EDM), extensor digiti minimi (EDMM), and extensor carpi ulnaris (ECUM) muscles, and the descending (lateral) branch provides innervation to the abductor pollicis longus (APLM), extensor pollicis longus and brevis (EPLM and EPBM), and extensor indicis (EIM) muscles [4,5]. Nevertheless, the branching patterns are highly variable [4,6]. Consequently, DBRN lesions typically manifest as a variable spectrum of weakness or paralysis in the muscles responsible for finger extension, impairing hand function and the patient's quality of life.

Impairment of the DBRN is among the less frequent neuropathies [1,7–9]. Loss in the distribution of the DBRN may be caused by both traumatic or non-traumatic mechanisms [8,10,11]. Various non-traumatic conditions, such as unique anatomical features along the course of the DBRN or space-occupying lesions, may lead to entrapment, which is generally the most frequent reason for DBRN palsy [1,7]. External compression of the DBRN may also develop after forearm fracture (e.g., Monteggia fracture), elbow dislocation, or surgical hardware placement [5,10]. Additionally, internal compression by a nerve tumor has also been documented [8,11]. On the other hand, traumatic neuropathies are usually caused by penetrating injuries with devastating consequences, owing to the resultant severe motor loss [12–14].

To date, numerous studies have been conducted on PIN palsy [7,8,10,11,14–20]; however, there remains notable deficiency

in recent scientific literature that simultaneously evaluates surgical experience with both compressive and traumatic DBRN neuropathies. Therefore, the aim of the present study was to analyze our cohort of patients who had undergone surgical treatment for DBRN neuropathy with a particular focus on the functional outcomes. Additionally, epidemiological characteristics, anatomical considerations linked to DBRN lesions, and complications were investigated.

Materials and methods

Following Institutional Review Board approval, we conducted a retrospective review of a surgical database of patients with peripheral nerve lesions treated at a single referral center between January 2011 and July 2024. The collected records of all patients who were diagnosed with either compressive or traumatic neuropathy of the DBRN were reviewed to gather data on the demographic details, anatomical location of the lesion, surgical management, outcomes, and complications. Exclusion criteria were applied to patients with simultaneous involvement of another motor nerve, insufficient records, and missing follow-up data.

Diagnosis

Clinically, the patients presented with a variable degree of weakness in fingers and thumb extension as a result of EDM, EDMM, EIM, EPBM, and EPLM palsy. Wrist extension with radial deviation signified preserved function of the extensor carpi radialis longus and brevis muscles in the setting of ECUM palsy. Abnormal EMG results showing denervation changes in the distribution of the PIN strongly indicated DBRN impairment. Additional imaging methods, including US and MRI, were indicated in selected cases.

Surgical technique

All neurolyses were performed using a peripheral nerve block with the patient placed in a supine position. The anterolateral approach was utilized for exploration of the DBRN. An S-shaped incision over the cubital fossa, starting about 5 cm proximal to the cubital flexion crease and following the medial border of the brachioradialis muscle distally, was made. After dissection through the subcutaneous tissue, the brachial fascia was incised along the medial border of the brachioradialis muscle. Proximally, the radial nerve was identified between the brachialis

and brachioradialis muscles, and was traced to its division into the SBRN and DBRN. The DBRN entering the supinator canal was then observed for any apparent compression sites or lesions. If required, the DBRN was also explored and released within the supinator canal or an additional posterior approach to the forearm was used for a more distal release. Intraoperative neurophysiological monitoring was used to assess the nerve action potentials.

Complex reconstructive procedures were performed under general anesthesia. In cases of traumatic lesions, incisions in the area of original scars were used to access the DBRN, or eventually, the PIN. In case of severe symptom persistence, tendon transfer was offered to the patient if no clinical improvement was observed within one year after neurolysis or surgical repair.

Recovery of the PIN function was periodically followed during outpatient visits and EMG examinations. Follow-ups were carried out by the operating surgeon.

Outcome assessment

The Louisiana State University Health Sciences Center (LSUHSC) grading system [8,11] was employed to assess the function of muscles innervated by the PIN (Tab. 1). This system evaluates the functional activity of the ECUM, EDM, and EPLM. A maximum grade of five indicates full strength, while a grade of zero signifies no function in the three aforementioned muscles. The LSUHSC score was assessed both preoperatively and postoperatively at final follow-up.

Statistical analysis

Anatomical aspects, complications, and treatment pitfalls were analyzed descriptively. Shapiro-Wilk test revealed a non-normal distribution of the data. Therefore, continuous variables are presented as median values with the interquartile range. Categorical variables are presented as absolute values with frequencies. Mann-Whitney U test was used for comparison of differences between groups with a P value ≤ 0.05 indicating statistical significance. Pearson correlation coefficient was calculated to describe association between variables with r values of 0–0.39 interpreted as a weak correlation; 0.40–0.69 demonstrating a moderate correlation; and > 0.70 indicating a strong correlation [21]. Statistical analysis was conducted using GraphPad Prism v. 9.5.1 (GraphPad Software, Boston, MA, USA).

Results

Twenty-two patients were identified for inclusion in this study, representing 1.1% of all surgically treated patients with peripheral nerve lesions over a 13-year period. The median follow-up was 17.5 (14–41) months. There were 15 patients (68.2%) with compressive and 7 patients (31.8%) with traumatic DBRN neuropathy. Levels of the lesion sites in relation to the supinator canal are shown in Fig. 1.

Compressive neuropathies

Among the patients with DBRN compressions, there were eight males (53.3%) and seven females (46.7%), with a median age of 49 (43–59) years (Tab. 2). Left upper limb was affected more frequently compared to the right side (9 vs. 6; 60.0 vs. 40.0%). The arcade of Frohse was the most common entrapment site (5 cases; 33.3 %) (Fig. 2). In three patients (20.0%), the DBRN was entrapped under the fibrous bands spanning between the brachioradialis and brachialis muscles (Fig. 3). One of these patients featured dual intraoperative compression by the leash of Henry, in addition to the aforementioned fibrous bands. Compression by scar tissue from a previous surgical intervention was encountered in three patients (20%). In two of these cases, the scarring was a result of an open reduction of the radial head. In the remaining case, excessive scarring occurred after unsuccessful distal biceps brachii tendon repair, where the reinsertion was found to be loose upon the revision surgery. Tumorous compression was observed in two patients (13.3%), with one being intraneural due to a perineurinoma (Fig. 4) and the other one being extraneural by a lipoma of the radial neck (Fig. 5). One patient (6.7%) presented with a compressed DBRN by a hematoma following unrecognized distal biceps brachii tendon rupture. Compression by a plate after osteosynthesis of the proximal radius was observed in one case (6.7%).

All patients underwent external neurolysis of the DBRN at a median time of 12 (4–24) months after the onset of symptoms, except for the case of DBRN perineurinoma, which was treated with resection and end-to-end neurorrhaphy. Overall, primary treatment significantly improved the preoperative LSUHSC score from 2 (0–3) to 4 (2–5) at the last follow-up (P = 0.018), leading to an increase in the LSUHSC score of 2 (0–4). Symptom duration showed a moderate negative correlation with functional LSUHSC out-

Tab. 1. The Louisiana State University Health Sciences Center grading system of posterior interosseous nerve function.

Grade	Criteria
0	no ECUM, EDM, or EPLM function
1	trace function or contraction against gravity only for ECUM
2	partial ECUM function; absent or trace function of EDM and/or EPLM
3	partial ECUM function; some EDM function; weak or absent EPLM function
4	full strength of ECUM; partial or moderate strength in EDM and EPLM
5	full strength in ECUM, EDM, and EPLM

ECUM – extensor carpi ulnaris muscle; EDM – extensor digitorum muscle; EPLM – extensor pollicis longus muscle

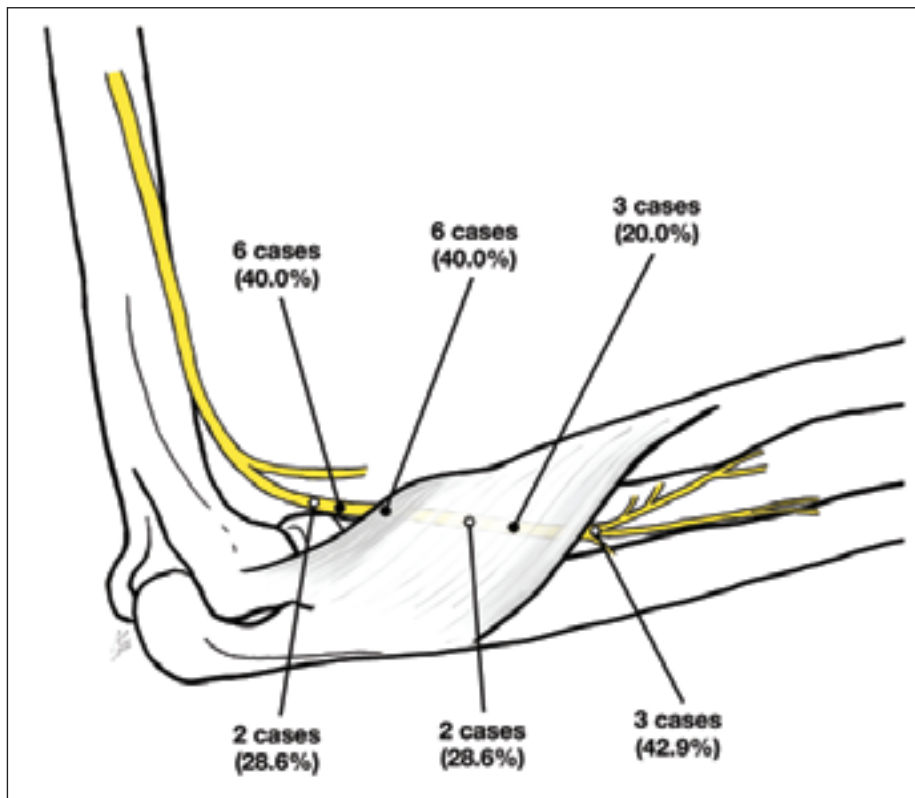


Fig. 1. Schematic illustration showing the lesion levels with their frequencies. Compressive neuropathies are marked with black dots, while traumatic neuropathies are displayed as white dots.

Obr. 1. Schematické znázornění úrovní lézí s jejich četností. Kompresivní neuropatie jsou označeny černými tečkami, zatímco traumatické neuropatie jsou zobrazeny bílými tečkami.

comes ($r = -0.46$), whereas age at the time of surgery demonstrated a weak positive correlation ($r = 0.29$).

Initial surgical treatment failed in four cases (26.7%), where the postoperative LSUHSC score either dropped or did not improve from the preoperative status. Two of these patients opted not to proceed with tendon transfer. In one case, which requi-

red tendon transfer of the flexor carpi ulnaris muscle (FCUM) to the EDM and reinsertion of the extensor carpi radialis longus muscle to the third metacarpal bone, the definitive treatment resulted in an LSUHSC score of 4. Furthermore, in the only case of intraneural compression, an unsuccessful end-to-end reconstruction of the DBRN following perineurinoma resection necessita-

Tab. 2. Characteristics of patients with compressive neuropathy of the deep branch of the radial nerve.

No.	Sex	Age	Side	Symptom duration (months)	Compression site	Previous condition	Pre-operative LSUHSC	Post-operative LSUHSC	Follow-up (months)	Additional treatment
1	M	58	L	10	AoF	–	4	2	38	–
2	M	43	L	1	plate	proximal radius fracture	1	5	43	–
3	M	43	R	13	AoF	–	3	2	82	tendon transfer
4	M	69	R	14	AoF	–	2	4	41	–
5	F	68	L	48	fibrous bands	–	4	5	14	–
6	F	52	L	6	scar tissue	radial head fracture	2	4	11	–
7	F	47	L	24	intraneural	perineurinoma	3	0	41	tendon transfer
8	F	32	L	48	fibrous bands	–	0	0	12	–
9	F	59	R	1	hematoma	distal biceps rupture	4	5	8	–
10	M	49	R	13	AoF	–	3	5	26	–
11	M	59	R	5	fibrous bands and LoH	–	3	4	13	–
12	F	76	R	12	AoF	radial neck lipoma	1	5	17	–
13	M	27	L	82	AoF	–	0	2	4	–
14	F	9	L	1	scar tissue	radial head fracture	0	5	15	–
15	M	48	L	2	scar tissue	distal biceps reinsertion	0	4	19	–

AoF – arcade of Frohse; F – female; L – left; LoH – leash of Henry; LSUHSC – Louisiana State University Health Sciences Center; M – male; R – right

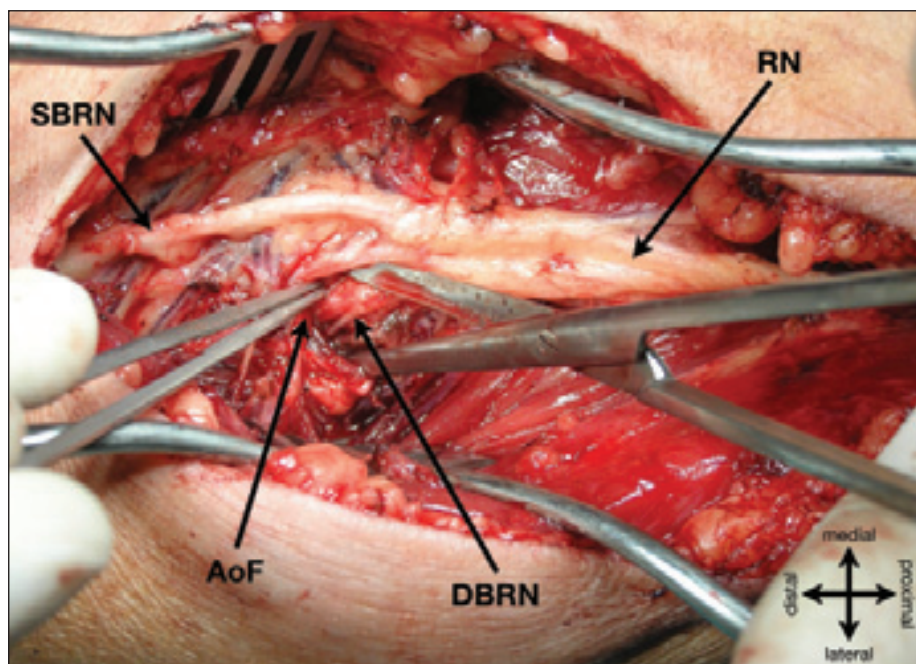


Fig. 2. Intraoperative image showing the release of the DBRN at the AoF.

AoF – arcade of Frohse; DBRN – deep branch of the radial nerve; RN – radial nerve; SBRN – superficial branch of the radial nerve

Obr. 2. Peroperační snímek zobrazující uvolnění DBRN v oblasti AoF.

AoF – Frohseho arkáda; DBRN – ramus profundus nervi radialis; RN – nervus radialis; SBRN – ramus superficialis nervi radialis

ted a transfer of the brachioradialis muscle to the APLM, palmaris longus muscle (PLM) to the EPLM, and FCUM to the EDM, resulting in a final LSUHSC score of 4. The time from the first surgery to tendon transfer was 26 and 14 months, respectively.

Traumatic neuropathies

Seven male patients with a median age of 43 (22–55) years underwent surgery due to a DBRN injury (Table 3). Right upper limb was predominantly involved (5 vs. 2; 71.4 vs. 28.6%). Laceration was the mechanism of injury in all but one case (85.7%). All lacerations resulted in a complete transection of the DBRN, and were caused by a sharp object, including a knife, sickle, machine tool, circular saw, piece of sheet metal, and motorcycle footpeg. The only case of DBRN contusion was caused by a knife cut, macroscopically not penetrating the antebrachial fascia (14.3%). Two lacerations occurred proximal to the supinator canal (33.3%), one within the supinator canal (16.7%), and three distal to this topographical space (50.0%). DBRN contusion occurred in the middle of the supinator canal.

All patients with forearm lacerations required extensor muscle repair by a direct suture. Three patients were treated with an end-to-end repair (42.9%). One of these patients underwent immediate repair on the day of injury, while the remaining two patients had a surgery delay of one and five months, necessitating neuroma resection. Neuroma resection followed by nerve grafting was performed in three patients (42.9%). The grafts were harvested from the lateral antebrachial cutaneous nerve in two cases, and from the SBRN in one case. These procedures were performed from one to five months following injury. Surgical exploration and neurolysis were performed in one case, which was classified as contusion due to the DBRN being in continuity (14.3%). Since intraoperative monitoring showed signs of neuronal activity, this case most likely featured a spontaneous regeneration at the time of surgery, which took place one month after the injury. The LSU-HSC score significantly improved from preoperative 0 (0–0) to 3 (0–4) following primary treatment ($P = 0.011$), and the difference in LSUHSC score between the preoperative and postoperative status was 3 (0–4). Neither age nor symptom duration showed a substantial correlation with postoperative functional outcomes ($r = -0.11$ and $r = -0.05$, respectively). Compared to the compressive neuropathy group, the preoperative LSUHSC score was significantly worse ($P = 0.004$); however, differences in postoperative scores and LSU-

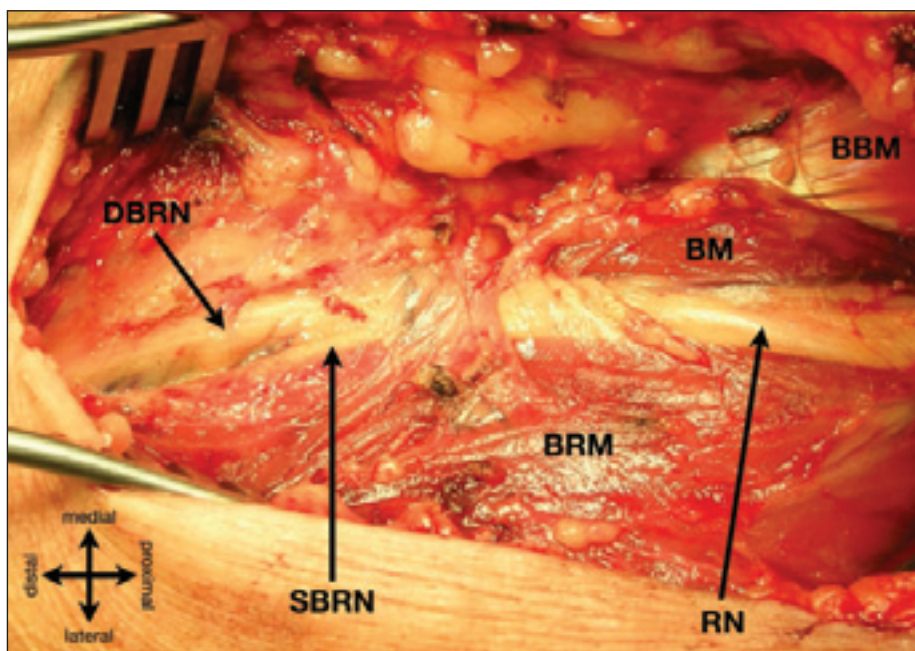


Fig. 3. Intraoperative image showing a compression by the fibrous bands spanning between the BM and the BRM.

BM – brachialis muscle; BBM – biceps brachii muscle; BRM – brachioradialis muscle; DBRN – deep branch of the radial nerve; RN – radial nerve; SBRN – superficial branch of the radial nerve
Obr. 3. Peroperační snímek zobrazující kompresi vazivovými pruhy mezi BM a BRM.

BM – musculus brachialis; BBM – musculus biceps brachii; BRM – musculus brachioradialis; DBRN – ramus profundus nervi radialis; RN – nervus radialis; SBRN – ramus superficialis nervi radialis

HSC changes were not statistically significant ($P = 0.129$ and $P = 0.391$, respectively).

There were two cases of unsuccessful primary reconstruction (28.6%). Thus, tendon

transfer comprising of the FCUM to the EDM and the PLM to the EPLM was performed in both cases. This reconstructive procedure resulted in a final LSUHSC score of 3 and 4.

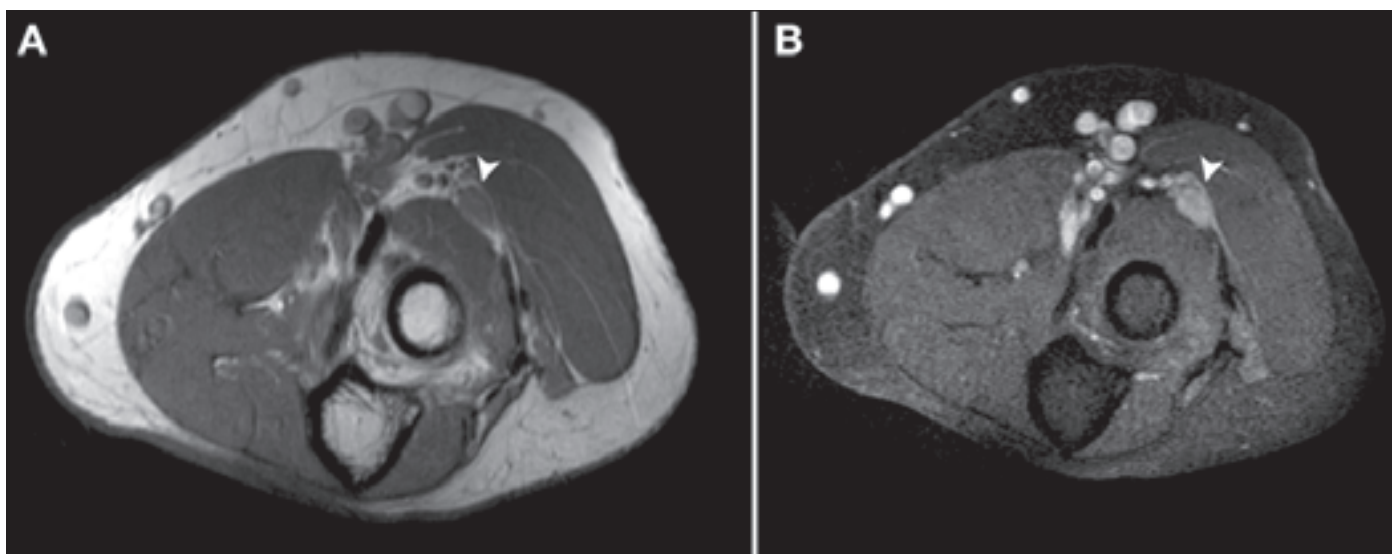


Fig. 4. MRI. PDW TSE (A) and T1W TSE (B) images showing a neural tumor (arrowhead) that was histologically classified as perineurinoma.

PDW – proton density-weighted; TSE – turbo spin echo

Obr. 4. MR. Snímky z PDW TSE (A) a T1W TSE (B) sekvencí zobrazující tumor nervu (hrot šipky), který byl histologicky klasifikován jako perineurinom.

PDW – proton density-weighted; TSE – turbo spin echo

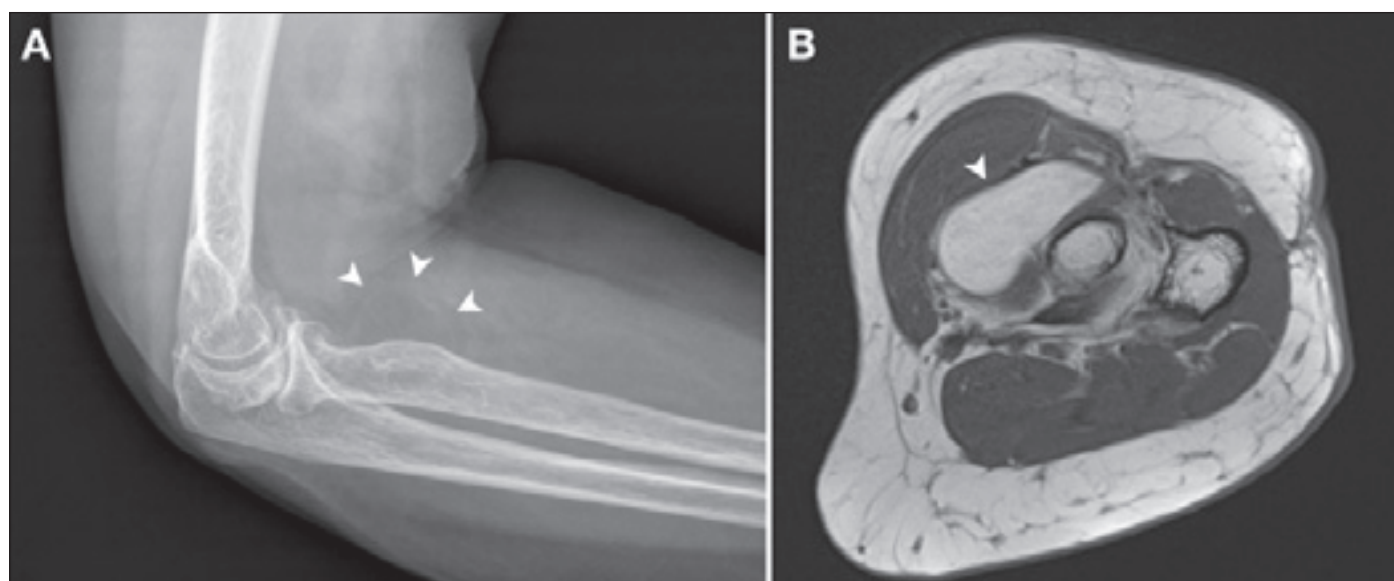


Fig. 5. Lateral x-ray (A) and MRI T1W (B) image showing a lipoma (arrowhead) at the level of the radial neck.

TSE – turbo spin echo

Obr. 5. Bočný rentgenový snímek (A) a snímek MR T1W TSE (B) sekvence zobrazující lipom (hrot šipky) v úrovni krčku vřetenní kosti.

TSE – turbo spin echo

Tab. 3. Characteristics of patients with traumatic neuropathy of the deep branch of the radial nerve or the posterior interosseous nerve.

No.	Sex	Age	Side	Symptom duration (months)	Mechanism	Anatomic location	Treatment	Pre-operative LSUHSC	Post-operative LSUHSC	Follow-up (months)	Additional treatment
1	M	28	R	0	laceration	proximal to supinator canal	end-to-end repair	0	0	46	tendon transfer
2	M	54	R	1	laceration	supinator canal	neuroma resection and end-to-end repair	0	3	16	–
3	M	43	R	5	laceration	distal to supinator canal	neuroma resection and grafting	0	4	44	–
4	M	19	R	1	contusion	supinator canal	neurolysis	0	3	12	–
5	M	64	R	1	laceration	proximal to supinator canal	neuroma resection and grafting	0	3	18	–
6	M	22	L	1	laceration	distal to supinator canal	neuroma resection and grafting	0	4	16	–
7	M	55	L	5	laceration	distal to supinator canal	neuroma resection and end-to-end repair	0	0	28	tendon transfer

F – female; L – left; LSUHSC – Louisiana State University Health Sciences Center; M – male; R – right

The time from the first surgery to the tendon transfer was 15 and 34 months, respectively.

Discussion

This comparative analysis of compressive and traumatic neuropathies of the DBRN provides insights into the efficacy of surgical interventions and discusses the underlying pathoanatomical aspects of DBRN lesions.

Our results highlight that severe preoperative dysfunction reported in traumatic neuropathies resolved after primary treatment, and both groups ultimately reached comparable functional outcomes over time. The findings of this study further demonstrate that a substantial percentage of patients in both groups experienced unsatisfactory results following primary surgical intervention.

Consistent with previous reports, the arcade of Frohse, characterized by tendinous remodeling of the proximal arch of the supinator muscle [2], emerged as the most common entrapment site for the DBRN [7,8,18,19]. Additionally, variable fibrous bands arising between the brachioradialis and brachialis muscles represented the second most common entrapment site in our series. The fre-

quently discussed compression caused by the leash of Henry (a branch of the recurrent radial artery transversing the DBRN proximal to the supinator canal) was identified only once in co-existence with the above-mentioned fibrous bands. Consequently, anatomical variations were responsible for about half of the compressive neuropathies, underscoring the importance of awareness regarding these variations. In the remaining cases, patients developed compression due to other underlying pathologies, including proximal radius fracture, distal biceps brachii tendon rupture, and tumors. Notably, we did not identify any hourglass-like fascicular constrictions in our cohort [20].

Although forearm injuries are common conditions encountered in the emergency department, injuries to the DBRN and PIN are relatively rare because of the nerve's deep course within a solid muscular envelope. Therefore, traumatic neuropathy of the DBRN is usually associated with severe damage to the posterior and lateral compartments of the forearm [10], and the potential for DBRN injury should be considered following penetrating injuries to the extensor surface of the forearm [13]. All but one patient had surgery delay, resulting from a missed diagnosis upon initial wound exploration. Despite the delayed diagnosis, surgical management of forearm lacerations with involvement of the DBRN demonstrated satisfactory outcomes in the vast majority of our patients. This finding is consistent with other studies, suggesting that appropriate repair may lead to nearly full recovery [14,17]. This success is attributed to the short distance that the regenerating axons must transverse [13,14].

Current literature assessing both compressive and traumatic neuropathies of the DBRN is limited, resulting in a dearth of supporting data. According to Cravens and Kline [8], operative treatment yielded an LSUHSC score of at least 3 in all 28 of their cases. However, the authors indicated that all of their patients experienced symptoms for less than one year without providing closer specifications. Similarly, Kim et al. [11] reported functional outcomes achieving an LSUHSC score of at least 3 across their series of 45 surgically treated cases; however, they did not present any information regarding the duration of symptoms. In contrast, our findings suggest overall worse functional outcomes, which are likely attributable to an extended interval between the onset of

symptoms and the timing of surgical intervention. A direct comparison with other studies, especially those focusing on only one of the mechanisms, is impeded by differences in the employed methodologies [7,10,14–19].

The optimal surgical approach for treating non-traumatic PIN palsy remains unclear, owing to the heterogeneous nature of its etiologies [22]. Longer symptom duration was moderately correlated with worse functional outcomes in the compressive neuropathy group, but such a correlation was not found in the traumatic group. This discrepancy may be explained by the overall shorter interval from injury to surgery in the traumatic group compared to the longer symptom duration in patients with compressions. We believe that this highlights the impact of prompt surgical treatment on recovery outcomes [16,22]. In traumatic neuropathies, the DBRN should be immediately exposed, and repair should be attempted [10,12,13,23]. The option of tendon transfer emerges as a viable solution for managing cases that are refractory to the primary interventions [8,11]. Furthermore, nerve transfers to restore PIN function present excellent results in young patients [24].

This study is not without limitations. The retrospective design inherently introduces potential limitations and constraints in data interpretation. Moreover, given the rarity of these conditions, the relatively small sample size may reduce the generalizability of our findings. Furthermore, by focusing exclusively on patients who underwent surgical intervention, cases that were treated conservatively were overlooked.

Conclusion

Although surgical treatment provides significant functional improvement, neuropathies of the DBRN remain challenging conditions with a relatively high rate of unsuccessful primary surgical intervention. Primary treatment failed in about one-quarter of the patients in both study groups, and tendon transfer posed a viable option for management of these cases. Although patients with traumatic neuropathies of the DBRN presented with a worse preoperative functional status, the postoperative outcomes were comparable with the compressive neuropathy group.

Ethical approval

Study approval was granted by the Ethics Committee for Multi-Centric Clinical Trials of the University Hospi-

tal Motol and Second Faculty of Medicine, Charles University in Prague (No. EK-1107/22), and procedures were in accordance with the 1964 Declaration of Helsinki and its later amendments. Informed consent was obtained from all individual participants included in this study.

Authors' contribution statement

MB – conceptualization, methodology, formal analysis, investigation, writing – original draft
 IH, HZ – methodology, investigation, writing – review & editing
 DK – validation, writing – review & editing
 VK – methodology, supervision, writing – review & editing

Conflict of interest

The authors declare they have no potential conflicts of interest concerning drugs, products, or services used in the study.

References

1. Sunderland S. Nerves and nerve injuries. 2nd ed. New York: Churchill Livingstone 1978.
2. Benes M, Kachlik D, Kunc V et al. The arcade of Frohse: a systematic review and meta-analysis. *Surg Radiol Anat* 2021; 43(5): 703–711. doi: 10.1007/s00276-021-02718-5.
3. Braun N, Save AV, Lee SK et al. Nomenclature of the radial nerve: distinguishing between the deep branch of the radial nerve and the posterior interosseous nerve. *J Hand Surg Eur Vol* 2025; 50(1): 122–123. doi: 10.1177/17531934241254706.
4. Ay S, Apaydin N, Acar H et al. Anatomic pattern of the terminal branches of posterior interosseous nerve. *Clin Anat* 2005; 18(4): 290–295. doi: 10.1002/ca.20114.
5. Shrestha S, Kunc V, Woo AC. Posterior interosseous nerve injury after a fracture of ulna and radius: a case report. *Turk Neurosurg* 2021; 31(5): 803–806. doi: 10.5137/1019-5149.JTN.32693-20.1.
6. Elgafy H, Ebraheim NA, Rezcallah AT et al. Posterior interosseous nerve terminal branches. *Clin Orthop Relat Res* 2000; 376(376): 242–251. doi: 10.1097/00003086-200007000-00033.
7. Anania P, Fiaschi P, Ceraudo M et al. Posterior interosseous nerve entrapments: review of the literature. Is the entrapment distal to the arcade of Frohse a really rare condition? *Acta Neurochir* 2018; 160(9): 1857–1864. doi: 10.1007/s00701-00018-3615-3618.
8. Cravens G, Kline DG. Posterior interosseous nerve palsies. *Neurosurgery* 1990; 27(3): 397–402. doi: 10.1097/00006123-199009000-00009.
9. Dang AC, Rodner CM. Unusual compression neuropathies of the forearm, part 1: radial nerve. *J Hand Surg Am* 2009; 34(10): 1906–1914. doi: 10.1016/j.jhna.2009.10.016.
10. Hirachi K, Kato H, Minami A et al. Clinical features and management of traumatic posterior interosseous nerve palsy. *J Hand Surg Br* 1998; 23(3): 413–417. doi: 10.1016/s0266-7681(98)80071-5.
11. Kim DH, Murovic JA, Kim YY et al. Surgical treatment and outcomes in 45 cases of posterior interosseous nerve entrapments and injuries. *J Neurosurg* 2006; 104(5): 766–777. doi: 10.3171/jns.2006.104.5.766.
12. Givissis PK, Stavridis SI, Ditsios KT et al. Isolated injury of the posterior interosseous nerve complicating a deep laceration of the proximal forearm dorsolateral muscles: a case report. *J Trauma* 2009; 67(6): E194–E196. doi: 10.1097/TA.0b013e31815613d1.
13. Leechavengvongs S, Wittonchart K, Uerpairojkit C. Penetrating injury to the terminal branches of the posterior interosseous nerve with nerve grafting. *J Hand Surg Br* 2001; 26(6): 293–295. doi: 10.1054/jhsb.2001.0609.

- 14.** Shams A, El-Sayed MMH. Functional results after posterior interosseous nerve microsurgical repair. *Eur Orthop Traumatol* 2014; 5(3): 305–310. doi: 10.1007/s12570-12014-0252-0254.
- 15.** Kaiser R, Houstava L, Haninec P. Surgical treatment of supinator canal syndrome. *Cesk Slov Neurol N* 2013; 76/109(5): 619–622.
- 16.** Ochi K, Horiuchi Y, Tazaki K et al. Surgical treatment of spontaneous posterior interosseous nerve palsy: a retrospective study of 50 cases. *J Bone Joint Surg Br* 2011; 93(2): 217–222. doi: 10.1302/0301-620X.93B2.24748.
- 17.** Shergill G, Bonney G, Munshi P et al. The radial and posterior interosseous nerves. results fo 260 repairs. *J Bone Joint Surg Br* 2001; 83(5): 646–649. doi: 10.1302/0301-620X.83b5.11312.
- 18.** Suematsu N, Hirayama T. Posterior interosseous nerve palsy. *J Hand Surg Br* 1998; 23(1): 104–106. doi: 10.1016/s0266-7681(98)80234-9.
- 19.** Vrieling C, Robinson PH, Geertzen JHB. Posterior interosseous nerve syndrome: literature review and report of 14 cases. *Eur J Plast Surg* 1998; 21: 196–202. doi: 10.1007/s002380050068.
- 20.** Wu P, Yang JY, Chen L et al. Surgical and conservative treatments of complete spontaneous posterior interosseous nerve palsy with hourglass-like fascicular constrictions: a retrospective study of 41 cases. *Neurosurgery* 2014; 75(3): 250–257. doi: 10.1227/NEU.00000000000000424.
- 21.** Schober P, Boer C, Schwarte LA. Correlation coefficients: appropriate use and interpretation. *Anesth Analg* 2018; 126(5): 1763–1768. doi: 10.1213/ANE.0000000000002864.
- 22.** McGraw I. Isolated spontaneous posterior interosseous nerve palsy: a review of aetiology and management. *J Hand Surg Eur Vol* 2019; 44(3): 310–316. doi: 10.1177/1753193418813788.
- 23.** Sunderamoorthy D, Chaudhury M. An uncommon peripheral nerve injury after penetrating injury of the forearm: the importance of clinical examination. *Emerg Med J* 2003; 20(6): 565–566. doi: 10.1136/emj.20.6.565.
- 24.** Garcia-Lopez A, Navarro R, Martinez F et al. Nerve transfers from branches to the flexor carpi radialis and pronator teres to reconstruct the radial nerve. *J Hand Surg Am* 2014; 39(1): 50–56. doi: 10.1016/j.jhssa.2013.10.011.